

# Multiple intracranial aneurysms following radiation therapy for nasopharyngeal carcinoma

Puneet Gulati, Bhaskar Bhattacharyya<sup>1</sup>, Sumit Deb, Samarendranath Ghosh

Departments of Neurosurgery and <sup>1</sup>Neuroradiology, Bangur Institute of Neurosciences, Kolkata, West Bengal, India

## ABSTRACT

A 30-year-old male presented to the neurosurgical emergency with sudden onset severe headache, nausea, and vomiting. A computed tomography scan showed subarachnoid hemorrhage and a subsequent four vessel angiogram showed six cerebral aneurysms (predominantly fusiform) involving both the anterior and posterior circulations, all on the left side. The patient had received 60 Gy external beam radiotherapy for left nasopharyngeal carcinoma 8 years back. The middle cerebral artery aneurysm was clipped, while the internal carotid artery and the two posterior cerebral artery aneurysms were wrapped. The patient was discharged uneventfully and is asymptomatic at follow-up 6 months later. The effects of radiation on cerebral vasculature are well-documented. Radiation-induced vasculopathy generally presents as occlusion/stenosis of cerebral vessels and aneurysms are rare. Only 46 cases of radiation-induced aneurysms have been reported previously. Just seven of these had multiple aneurysms and only one case had as many as six aneurysms.

**Key words:** Intracranial aneurysms, nasopharyngeal carcinoma, radiation, radiation induced aneurysm, subarachnoid hemorrhage

## INTRODUCTION

Radiation induced cerebral vasculopathy is a well-known entity. It generally presents with occlusive and stenotic lesions in cerebral arteries.<sup>[1-4]</sup> Aneurysms have been reported very rarely. There have been only 46 reported cases of radiation induced aneurysms so far.<sup>[5]</sup> Just seven of these patients had multiple aneurysms. Aneurysm development has been generally seen to correspond to the field of radiotherapy, a mean of 12 years after exposure to radiation.<sup>[5]</sup> We report a patient with history of radiotherapy for nasopharyngeal carcinoma 8 years back, who presented to the emergency room with subarachnoid haemorrhage (SAH). Four vessel angiogram showed multiple intracranial aneurysms involving both anterior and posterior circulation.

## CASE REPORT

In 2004, a 22-year-old male was diagnosed with left sided nasopharyngeal carcinoma. Magnetic resonance

imaging (MRI) showed a lesion with epicenter at the left side of the nasopharynx with extension into adjoining left sided nasal cavity, left sided paranasal sinuses (sphenoid, ethmoid, and maxillary sinuses) and left parasellar region [Figure 1].

The patient received external beam radiotherapy (EBRT) with a total dose of 60 Gy in 30 divided doses over a 6 weeks period. The radiation field comprised left side of nasopharynx, left nasal cavity and left maxillary antrum. Clinicoradiological follow-up showed no local residual lesion/recurrence.

Eight years later, in 2012, this patient presented to the neurosurgical emergency with sudden onset severe headache, nausea and vomiting. Neck rigidity was present on examination. A plain computed tomography scan [Figure 2] showed SAH involving the perimesencephalic cisterns, sylvian cistern and along the tentorium (Fisher Grade 3). His Glasgow coma scale score was 15 and World Federation of Neurological Surgeons grade was Grade 1.

A four vessel angiogram revealed six cerebral aneurysms. There was a fusiform terminal left internal carotid artery (ICA) aneurysm with extension in proximal A1 and proximal M1 segments of left anterior cerebral artery and middle cerebral artery (MCA). A saccular

Access this article online	
Quick Response Code:	Website: www.ijns.in
	DOI: 10.4103/2277-9167.132005

**Address for correspondence:** Dr. Puneet Gulati,

Room No. 422, Junior Doctors Hostel, 242, A.J.C. Bose Road, Kolkata - 700 020, West Bengal, India. E-mail: puneetgulati7@gmail.com

aneurysm was seen in the dilated proximal M1 segment of left MCA [Figure 3] Small fusiform aneurysms were seen in proximal left ophthalmic artery (OA) and left posterior communicating artery (PCOM) [Figure 4]. Finally, two fusiform aneurysms were seen in P2 segment of left posterior cerebral artery (PCA) [Figure 5]. A MRI done subsequently revealed no residual/recurrent nasopharyngeal carcinoma.

Since endovascular coiling facilities are not available in our institution, the patient was managed surgically. The saccular left MCA aneurysm was clipped, while the left ICA and the two PCA aneurysms were wrapped. The OA and the PCOM artery aneurysms were too small to be of any significance and were left alone. The aneurysm wall of the clipped MCA aneurysm was biopsied. Histopathological examination revealed scanty cells, irregularly thickened media and intima and fibrotic changes. Though not pathognomonic, this picture is compatible with radiation induced vasculopathy.

Recovery was uneventful and the patient was discharged on the 10<sup>th</sup> postoperative day.

## DISCUSSION

Radiation induced vasculopathy was first reported by Thomas and Forbus in 1959.<sup>[6]</sup> It is now a well-documented entity where radiation induced damage to the vascular endothelium leads to occlusive vascular injury. Radiation induced aneurysms are a much rarer entity and pathogenesis is believed to be similar.

Of the reported cases of radiation induced aneurysms so far, only seven patients had multiple aneurysms. Our patient had six distinct aneurysms; only one case previously has had as many as six aneurysms.<sup>[7]</sup> Multiple aneurysms present a therapeutic challenge and sometimes require a multimodality treatment approach.

Radiation-induced aneurysms generally occur in the

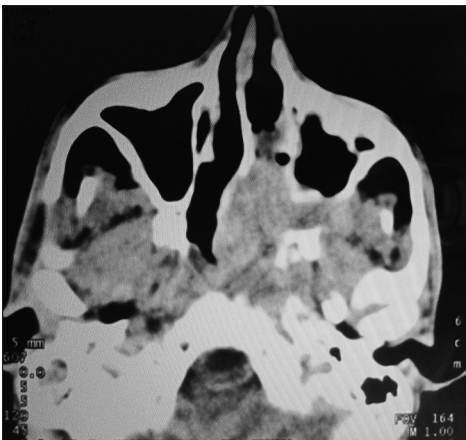


Figure 1: Computed tomography scan showing left nasopharyngeal carcinoma

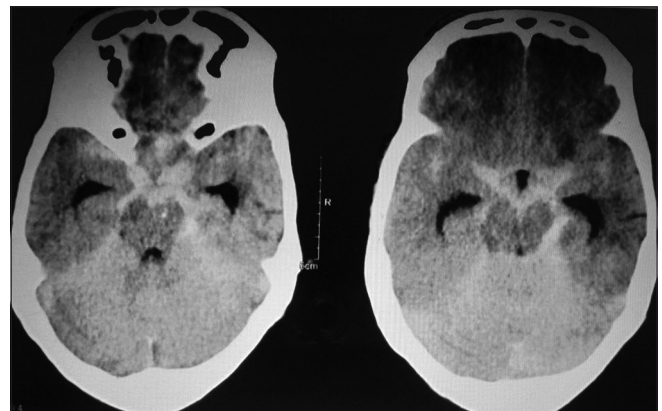


Figure 2: Computed tomography scan showing subarachnoid haemorrhage involving perimesencephalic cisterns, sylvian cistern and tentorium

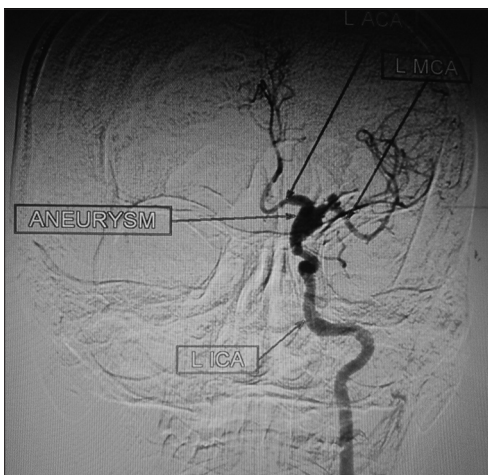


Figure 3: Angiogram of the left internal carotid artery (anteroposterior view) showing the left internal carotid artery aneurysm and the saccular middle cerebral artery aneurysm

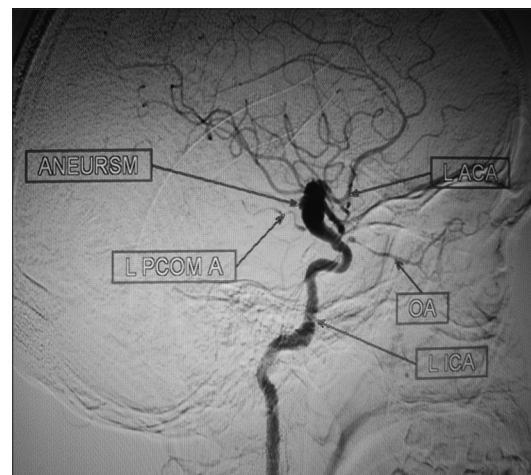
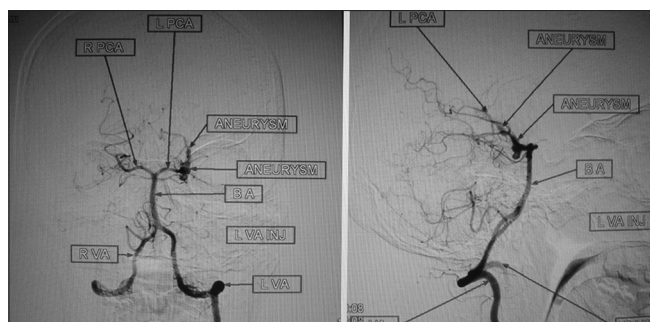


Figure 4: Angiogram of the left internal carotid artery (lateral view) showing the small left ophthalmic artery and left posterior communicating artery aneurysms



**Figure 5:** Angiogram of the left vertebral artery showing the two posterior cerebral artery aneurysms

field of radiation. Our patient had received EBRT for left sided nasopharyngeal carcinoma and all aneurysms developed on the left side. Though no pre radiation vascular investigation was ordered, the pre-radiation MRI was not suggestive of any aneurysm. These aneurysms have presented 4 months to 50 years after exposure to radiation (with a mean of 12 years).<sup>[5]</sup> The latency to SAH was 8 years in our case.

Median lag time to SAH has been reported to be 20 years for brachytherapy, 8 years for focused radiation, 9 years for whole brain radiation, and 6 years for stereotactic radiosurgery.<sup>[5]</sup> The latency to SAH was 8 years in our case.

Radiation induced aneurysms reported in literature were saccular in 83% cases and fusiform in 9% cases.<sup>[5,8]</sup> In our patient, of the six aneurysms, five were fusiform and one was saccular.

Among reported aneurysms, 55% presented with some form of hemorrhage and only 13% were discovered incidentally.<sup>[5]</sup>

Radiation induced aneurysms characteristically arise directly from vessel walls unlike congenital aneurysms, which arise at branching points. Rupture in radiation induced aneurysms takes place at their origin or at the takeoff point of arterial branches.<sup>[9]</sup> This again contrasts with congenital aneurysms where rupture generally occurs at the dome.

Histologically, radiation induced aneurysms show injury to or loss of internal elastic lamina, thickening of intima and fibrosis. Foamy histiocytes, plaque and thickened collagenized adventitia may be evident. In our patient,

histopathological examination revealed scanty cells, irregularly thickened media and intima and fibrotic changes. None of these features are however specific to radiation induced vasculopathy.<sup>[10,11]</sup>

## CONCLUSION

Radiation induced aneurysms is a potentially fatal condition generally appearing several years after radiation therapy. Though rare, high index of suspicion should be there for patients presenting with spontaneous SAH months to years after cranial radiation therapy. Emergent angiogram followed by surgical clipping or coiling is the management strategy of choice.

## REFERENCES

1. Conomy JP, Kellermeyer RW. Delayed cerebrovascular consequences of therapeutic radiation. A clinicopathologic study of a stroke associated with radiation-related carotid arteriopathy. *Cancer* 1975;36:1702-8.
2. Sheline GE, Wara WM, Smith V. Therapeutic irradiation and brain injury. *Int J Radiat Oncol Biol Phys* 1980;6:1215-28.
3. Silverberg GD, Britt RH, Goffinet DR. Radiation-induced carotid artery disease. *Cancer* 1978;41:130-7.
4. Ghoshhajra BB, McLean GK, SIR Foundation. SIR 2006 Annual Meeting Film Panel Case: Radiation-induced cerebral aneurysms. *J Vasc Interv Radiol* 2006;17:1891-6.
5. Nanney AD 3<sup>rd</sup>, El Tecle NE, El Ahmadih TY, Daou MR, Bit Ivan EN, Marymont MH, et al. Intracranial aneurysms in previously irradiated fields: Literature review and case illustration. *World Neurosurg* 2013.
6. Thomas E, Forbus WD. Irradiation injury to the aorta and the lung. *AMA Arch Pathol* 1959;67:256-63.
7. Moriyama T, Shigemori M, Hirohata Y, Konishi J, Tokunaga T, Kuramoto S. Multiple intracranial aneurysms following radiation therapy for pituitary adenoma; a case report. *No Shinkei Geka* 1992;20:487-92.
8. Jensen FK, Wagner A. Intracranial aneurysm following radiation therapy for medulloblastoma. A case report and review of the literature. *Acta Radiol* 1997;38:37-42.
9. Yamaguchi S, Kato T, Takeda M, Ikeda H, Kitamura K. Ruptured distal anterior inferior cerebellar artery aneurysm following stereotactic irradiation for vestibular schwannoma: Case report. *Neurol Med Chir (Tokyo)* 2009;49:202-5.
10. Yucesoy K, Feiz-Erfan I, Spetzler RF, Han PP, Coons S. Anterior communicating artery aneurysm following radiation therapy for optic glioma: Report of a case and review of the literature. *Skull Base* 2004;14:169-73.
11. Azzarelli B, Moore J, Gilmore R, Muller J, Edwards M, Mealey J. Multiple fusiform intracranial aneurysms following curative radiation therapy for suprasellar germinoma. Case report. *J Neurosurg* 1984;61:1141-5.

**How to cite this article:** Gulati P, Bhattacharyya B, Deb S, Ghosh S. Multiple intracranial aneurysms following radiation therapy for nasopharyngeal carcinoma. *Indian J Neurosurg* 2014;3:44-6.

**Source of Support:** Nil, **Conflict of Interest:** None declared.