

## LETTERS

## Inconspicuous Nasoethmoidal Encephalocele Might Be Wrongly Diagnosed

Weng Jun Tang, Wan Azman Wan Sulaiman

Reconstructive Science Unit, School of Medical Sciences, Health Campus, Universiti Sains Malaysia, Kubang Kerian, Malaysia

**Correspondence:** Weng Jun Tang  
Reconstructive Sciences Unit, School of Medical Sciences, Health Campus, Universiti Sains Malaysia,  
16150 Kubang Kerian Kelantan, Malaysia  
Tel: +609-7676894, Fax: +609-7676909, E-mail: weng\_jun@yahoo.com

No potential conflict of interest relevant to this article was reported.

Received: 30 Jan 2016 • Revised: 16 Mar 2016 • Accepted: 16 Mar 2016  
pISSN: 2234-6163 • eISSN: 2234-6171  
<http://dx.doi.org/10.5999/aps.2016.43.3.291> • Arch Plast Surg 2016;43:291-292



Copyright © 2016 The Korean Society of Plastic and Reconstructive Surgeons  
This is an Open Access article distributed under the terms of the Creative Commons Attribution Non-Commercial License (<http://creativecommons.org/licenses/by-nc/4.0/>) which permits unrestricted non-commercial use, distribution, and reproduction in any medium, provided the original work is properly cited.

Dear Editor-in-Chief,

We have read the paper of Song et al. [1] on frontonasal dysplasia deformity. It was an interesting discussion of an image that depicts a boy with a nose deformity, and it was reported that no basal encephalocele was observed. We would like to point out that we had a similar case of a girl with the same nose deformity. As in the report by Song et al., our patient also presented with mild hypertelorism, a

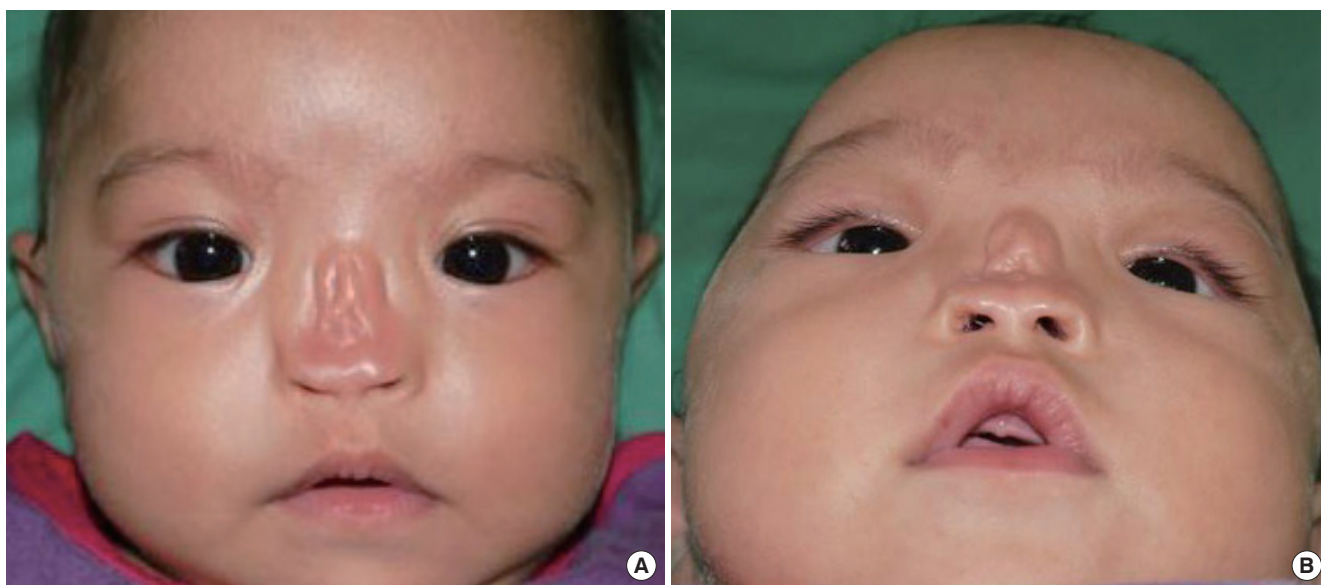broad nasal root and a bifid nasal tip (Fig. 1). The defect at the nasal dorsum had never increased in size and was not cystic. Her parents were anxious about the cosmetic appearance of their child and requested an early excision of the nasal defect and rhinoplasty.

Intraoperatively, we noted a very small stalk passing between the nasal bone and the upper lateral cartilage (Fig. 2A, B). The stalk was faintly seen on the magnetic resonance imaging due to its very small size. This small stalk passed from an internal location between the frontal and ethmoidal bone to an external location between the nasal bone and the upper lateral cartilage (Fig. 2C).

Due to this inconspicuous finding, a frontoethmoidal encephalocele may be missed and wrongly diagnosed. Frontoethmoidal encephalomeningocele is associated with hypertelorism, a broad nasal root, bifid nasal tip, widow's peak and encephalocele, all of which were present in our patient. Based on the clinical review by Rojvachiranonda et al. [2], our patient did have a small herniation mass with a very small stalk of 2 mm passing through a long narrow exit pathway. Due to the small diameter of the stalk and mass, there were no external bone defects or a huge facial deformity. Only skin thickening was present, without a secondary pressure effect, which correlates with the classification on the basis of the soft tissue aspect by Rojvachiranonda et al. [2]. Based on the proposed classification by Rojvachiranonda et al. [2], which describes a facial deformity, external bone defect, exit pathway and malformation of the brain, this patient could be classified as  $F_{1c}E_{1NE}E_1M_0$ .

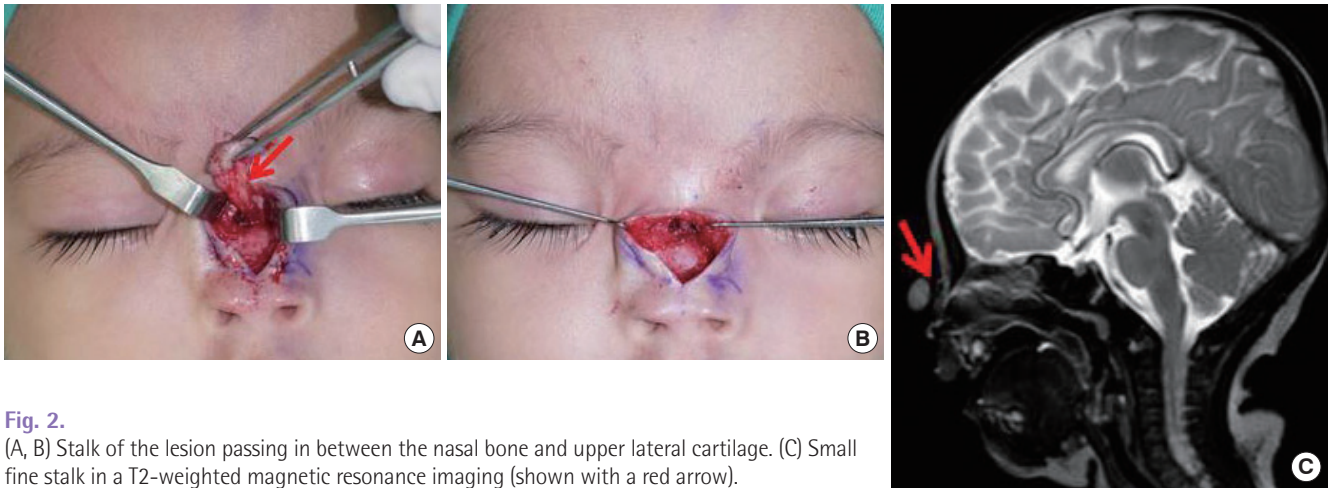
Thank you.

Yours sincerely,



**Fig. 1.**

(A, B) A 6 months old, Malay girl with features of nasoethmoidal encephalomeningocele, including telecanthus, broadening of the nasal root with irregular nasal dorsal skin and lack of a nasal tip.



**Fig. 2.** (A, B) Stalk of the lesion passing in between the nasal bone and upper lateral cartilage. (C) Small fine stalk in a T2-weighted magnetic resonance imaging (shown with a red arrow).

## References

1. Song SY, Choi JW, Lew HW, et al. Nasal reconstruction of a frontonasal dysplasia deformity using aesthetic rhinoplasty techniques. *Arch Plast Surg* 2015;42:637-9.
2. Rojvachiranonda N, David DJ, Moore MH, et al. Frontoethmoidal encephalomeningocele: new morphological findings and a new classification. *J Craniofac Surg* 2003;14:847-58.

## Response To Dr. Tang Letter to Editor: Inconspicuous Nasoethmoidal Encephalocele Might Be Wrongly Diagnosed

Jong Woo Choi

Department of Plastic and Reconstructive Surgery, Asan Medical Center, University of Ulsan College of Medicine, Seoul, Korea

**Correspondence:** Jong Woo Choi  
Department of Plastic and Reconstructive Surgery, Asan Medical Center, University of Ulsan College of Medicine, 88 Olympic-ro 43-gil, Songpa-gu, Seoul 05505, Korea  
Tel: +82-2-3010-3604, Fax: +82-2-476-7471, E-mail: pschoi@amc.seoul.kr

No potential conflict of interest relevant to this article was reported.

Received: 9 May 2016 • Revised: 11 May 2016 • Accepted: 11 May 2016  
pISSN: 2234-6163 • eISSN: 2234-6171  
<http://dx.doi.org/10.5999/aps.2016.43.3.292> • *Arch Plast Surg* 2016;43:292



Copyright © 2016 The Korean Society of Plastic and Reconstructive Surgeons  
This is an Open Access article distributed under the terms of the Creative Commons Attribution Non-Commercial License (<http://creativecommons.org/licenses/by-nc/4.0/>) which permits unrestricted non-commercial use, distribution, and reproduction in any medium, provided the original work is properly cited.

We appreciate your comments on our diagnosis of a case of frontonasal dysplasia.

We reviewed Nond's new classification system and the patient's data and computed tomography (CT) findings again as you suggested. However, we were not able to find evidence of frontoethmoidal encephalomeningocele (FEEM).

Given the genetic counseling and the morphologic features based on the CT scan, we have concluded that frontonasal dysplasia is the right diagnosis for this patient. Genetic analysis revealed that the patient had a normal *ALX3* gene sequence, indicating a sporadic occurrence of frontonasal dysplasia. If the patient would have been interested in the exact gene sequence, we could have ordered the analysis of the *ALX1* or *ALX4* genes, but the parents of the patient did not want to do so in this case.

Despite the lack of evidence, we believe it still could be possible that this patient had FEEM. As you mentioned, there is a possibility that some patients with FEEM features are diagnosed with frontonasal dysplasia. We agree. In the diagnosis of FEEM, extracranial pathological findings of interest include herniation masses, facial deformities, and frontonasal bone morphology. Intracranial pathological findings of interest include morphology of the anterior cranial floor and brain malformations.

Although we have concluded that our patient's diagnosis is frontonasal dysplasia, we appreciate your valuable comments on the similarity to FEEM. We feel the differential diagnosis of the two types of lesions requires further research.

Regards,