

4. Liu YJ, Hirsch BP, Shah AA, et al. Mild intraoperative hypothermia reduces free tissue transfer thrombosis. *J Reconstr Microsurg* 2011;27:121-6.
5. Thomson JG, Mine R, Shah A, et al. The effect of core temperature on the success of free tissue transfer. *J Reconstr Microsurg* 2009;25:411-6.

Iatrogenic Calcinosis Cutis of the Upper Limb Arising from the Extravasation of Intravenous Anticancer Drugs in a Patient with Acute Lymphoblastic Leukemia

Eui Han Chung, Young Hwan Kim

Department of Plastic and Reconstructive Surgery, Baik Hospital, Inje University School of Medicine, Busan, Korea

Correspondence: Young Hwan Kim
Department of Plastic and Reconstructive Surgery, Busan Baik Hospital, Inje University School of Medicine, 75 Bokji-ro, Busanjin-gu, Busan 47392, Korea
Tel: +82-51-890-6136, Fax: +82-51-894-7976
E-mail: hwanps77@hanmail.net

No potential conflict of interest relevant to this article was reported.

Received: 22 Apr 2015 • Revised: 8 Jun 2015 • Accepted: 9 Jun 2015
pISSN: 2234-6163 • eISSN: 2234-6171
<http://dx.doi.org/10.5999/aps.2016.43.2.214>
Arch Plast Surg 2016;43:214-216



Copyright © 2016 The Korean Society of Plastic and Reconstructive Surgeons
This is an Open Access article distributed under the terms of the Creative Commons Attribution Non-Commercial License (<http://creativecommons.org/licenses/by-nc/4.0/>) which permits unrestricted non-commercial use, distribution, and reproduction in any medium, provided the original work is properly cited.

Calcinosis cutis is a condition in which calcium salts are deposited in the skin and subcutaneous tissue due to various causes. These deposits are classified as dystrophic, metastatic, idiopathic, and iatrogenic calcifications [1]. Dystrophic calcification is characterized by damaged or abnormal local tissues without elevated serum calcium and phosphate levels.

Metastatic calcification is caused by abnormal calcium and/or phosphate metabolism. Idiopathic calcification occurs even in the absence of tissue damage or metabolic disorders. Moreover, calcification may also occur as a result of tissue damage or impaired mineral metabolism after medical interventions [2].

We experienced a case of an 18-year-old man who had been diagnosed with acute lymphoblastic leukemia (ALL) as a child and developed iatrogenic calcinosis cutis due to the extravasation of intravenous anticancer drugs. Here, we report our case with a review of the literature. In January 2015, a patient initially diagnosed with ALL in June 2001 visited us for the further evaluation and treatment of a mass. Until September 2004, the patient had been treated with methotrexate, vincristine, and cyclophosphamide at the outpatient clinic of the Department of Pediatrics. In 2002, the patient exhibited extravasation of intravenous anticancer drugs on the dorsum of the right hand. At that time, the patient presented with pain, swelling, redness, and tender inflammation. Over two weeks, the redness and inflammation had improved, but the lesion exhibited a gradual tendency towards firmness. A routine laboratory test showed calcium levels of 9.9 mg/dL and inorganic phosphate levels of 5.4 mg/dL. In February 2007, the patient experienced a relapse of ALL. Until August 2010, the patient received secondary chemotherapy using the same drugs. During this period, in 2008, the patient experienced extravasation of intravenous anticancer drugs on the elbow of the right arm. As in 2002, the patient developed a larger mass two weeks later. A routine laboratory test showed calcium levels of 9.5 mg/dL and inorganic phosphate levels of 5.3 mg/dL. Both masses persisted without changes in their size (Fig. 1).

On radiography, the patient had a radiopaque lesion at the site of each mass. On sonography, the patient had calcified lesions in the subcutaneous fat layer; the

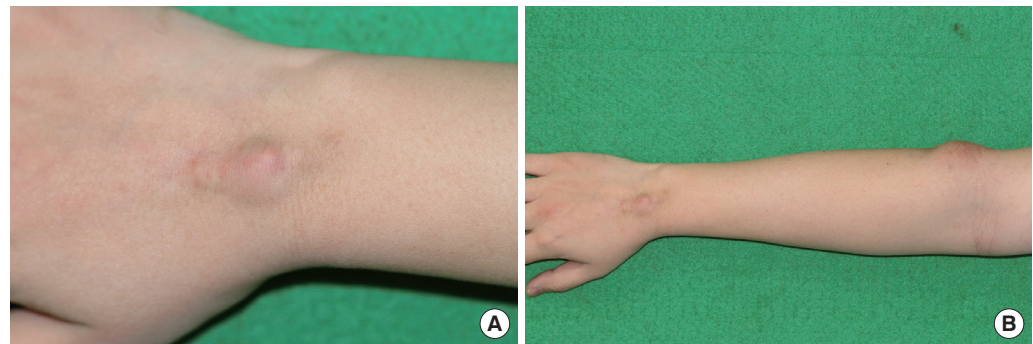


Fig. 1.
Preoperative view of the patient. (A) The mass on the dorsum of the right hand. (B) The mass on the elbow of the right arm.

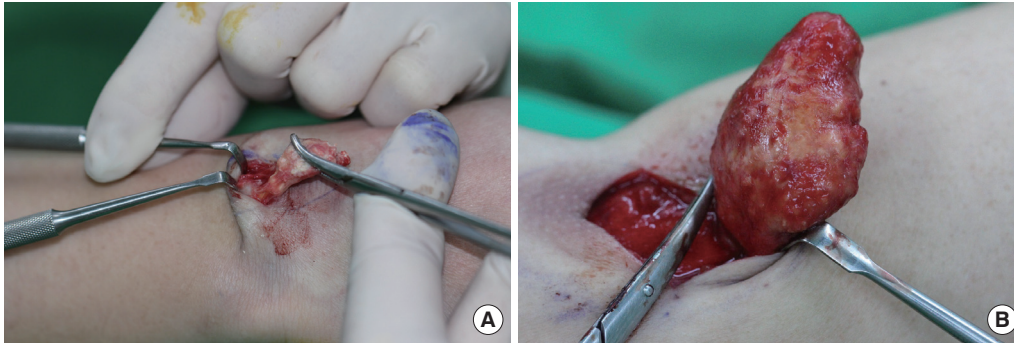


Fig. 2. Intraoperative view of the patient. (A) The mass on the dorsum of the right hand. (B) The mass on the elbow of the right arm.

lesion on the dorsum of the right hand measured $3.0 \times 1.1 \times 0.5$ cm, and the lesion on the elbow of the right arm measured $4.0 \times 2.6 \times 1.3$ cm. These findings were interpreted as a heterotopic ossification. On January 21, 2015, the patient underwent resection of the mass under general anesthesia. Intraoperatively, two subcutaneous encapsulated masses were found: one was found on the dorsum of the right hand and measured $2.4 \times 1.5 \times 0.5$ cm, and the other was found on the elbow of the right arm and measured $5.2 \times 2.8 \times 1.4$ cm (Fig. 2). Postoperatively, the patient underwent tissue biopsy and was diagnosed with calcinosis cutis (Fig. 3). Thereafter, the patient underwent follow-up at our outpatient clinic, but showed no episodes of recurrence.

Calcinosis cutis may be misdiagnosed as cellulitis, osteomyelitis, arthritis, abscess, periostitis, myositis ossificans, and thrombophlebitis. It is frequently encountered in a clinical setting. When a preoperative X-ray or sonography shows heterotopic ossification, differential diagnoses should include osteoma cutis and calcinosis cutis. Osteoma cutis is a condition in which bone tissue is formed on the skin, with the emergence of a focus of calcification arising from the inflammatory scar or from a granuloma of bony tissue. In contrast, calcinosis cutis is characterized by the deposition of calcium salt in the skin and soft tissue, with the involvement of bony tissue.

The pathogenesis of calcinosis cutis has not been fully elucidated. However, many factors causing this disease have been established, and different clinical scenarios, involving various forms of calcinosis cutis, arise from different causes. Tumoral calcinosis is characterized by calcium deposition around joints, and appears in healthy adolescents. It is a type of metastatic calcification that accompanies hyperphosphatemia, and develops after swelling without pain at the major joints such as the shoulder, hips, and elbows. Leukemia cutis occurs with paraneoplastic hypercalcemia due to bony metastases or the production of an abnormal hormone

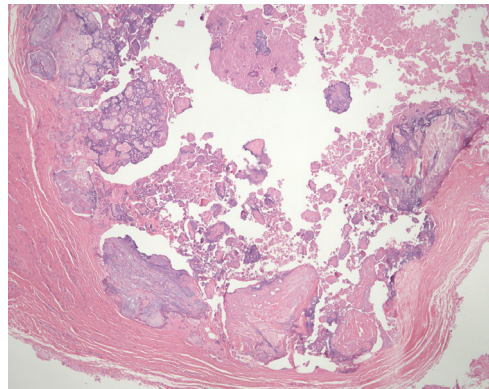


Fig. 3. Pathologic image showing calcium salts, which can be recognized as either fine granules or small deposits in the dermis (H&E, $\times 100$).

that directly affects calcium and bone metabolism. According to Lestringant et al. [3], this disease is widespread and mainly affects the blood vessels, kidneys, lungs, and gastric mucosa, as well as the skin or subcutaneous tissue. Furthermore, diffuse osteoporosis or spontaneous fractures of small bones may appear.

In our case, it was possible to distinguish the clinical course of tumoral calcinosis from leukemia cutis. When the mass first developed, the patient's serum calcium levels were within the normal range and phosphate was slightly elevated, but within the normal range considering that the patient was a child at the time. Therefore, we were able to exclude metastatic calcification with hyperphosphatemia and hypercalcemia. Unlike the general pattern of occurrence observed in diffuse leukemia cutis, the mass arose at the venipuncture site after intravenous injections, subsequent to pain, swelling, and redness.

Some case reports have described iatrogenic calcinosis cutis as a complication of the intravenous use of calcium chloride or calcium gluconate [4]. These authors have also noted that iatrogenic calcinosis cutis occurs between two hours and 24 days after extravasation, with an average delay of 13 days [5]. The case of our patient corresponded to this pattern, with calcinosis cutis caused by the extravasation of calcium solutions. The patient

developed a mass two weeks after the extravasation of anticancer drugs, which is consistent with the clinical manifestation of calcinosis cutis arising from the extravasation of calcium chloride. According to Goldminz et al. [5], the pathophysiology of calcinosis cutis is based on tissue damage arising from the extravasation of a solution followed by the deposition of crystalline or insoluble calcium phosphate minerals.

However, we did not use intravenous calcium therapy. We assume that this case was solely caused by the extravasation of anticancer drugs. The tissue damage caused by the extravasation of anticancer drugs may be assumed to have played an important role in the onset of calcinosis cutis. This is the first case report of calcinosis cutis caused by the extravasation of intravenous anticancer drugs. We believe that our rare case may help elucidate the pathogenesis of calcinosis cutis.

References

- Walsh JS, Fairley JA. Calcifying disorders of the skin. *J Am Acad Dermatol* 1995;33:693-706.
- Reiter N, El-Shabrawi L, Leinweber B, et al. Calcinosis cutis: part I. Diagnostic pathway. *J Am Acad Dermatol* 2011;65:1-12.
- Lestringant GG, Masouye I, El-Hayek M, et al. Diffuse calcinosis cutis in a patient with congenital leukemia and leukemia cutis. *Dermatology* 2000;200:147-50.
- Kagen MH, Bansal MG, Grossman M. Calcinosis cutis following the administration of intravenous calcium therapy. *Cutis* 2000;65:193-4.
- Goldminz D, Barnhill R, McGuire J, et al. Calcinosis cutis following extravasation of calcium chloride. *Arch Dermatol* 1988;124:922-5.

A Rare Case of an Epidermal Inclusion Cyst in the Joint Capsule of the Thumb

So-Min Hwang¹, Sang-Hwan Lee¹, Min-Wook Kim¹, Hwal-Woong Kim²

¹Aesthetic, Plastic, and Reconstructive Surgery Center, Busan; ²Department of Pathology, Good Moonhwa Hospital, Busan, Korea

Correspondence: Sang-Hwan Lee

Aesthetic, Plastic and Reconstructive Surgery Center, Good Moonhwa Hospital, 119 Beomil-ro, Dong-gu, Busan 48735, Korea
Tel: +82-51-630-0199, Fax: +82-51-630-0145
E-mail: Sangwind@hanmail.net

This article was presented as a poster at the 72nd Congress of the Korean Society of Plastic and Reconstructive Surgeons on November 7-9, 2014 in Seoul, Korea.

No potential conflict of interest relevant to this article was reported.

Received: 13 Apr 2015 • Revised: 11 May 2015 • Accepted: 21 May 2015

ISSN: 2234-6163 • eISSN: 2234-6171
<http://dx.doi.org/10.5999/aps.2016.43.2.216>
Arch Plast Surg 2016;43:216-218



Copyright © 2016 The Korean Society of Plastic and Reconstructive Surgeons
This is an Open Access article distributed under the terms of the Creative Commons Attribution Non-Commercial License (<http://creativecommons.org/licenses/by-nc/4.0/>) which permits unrestricted non-commercial use, distribution, and reproduction in any medium, provided the original work is properly cited.

Epidermal inclusion cysts are one of the most common types of benign lesions that present in the subcutaneous tissue, and they are observed as fluctuating nodules [1]. They may occur in all body areas composed of squamous epithelium. However, intra-articular involvement of such cysts has been described very rarely in the literature [2]. We experienced a case of an epidermal inclusion cyst occurring in the joint capsule of the thumb in a patient with a past history of thumb trauma. Herein, we report our case and provide a review of the

Fig. 1.

(A) A 75-year-old male who had a mass within the interphalangeal joint capsule of the right thumb. (B) Widening of the interphalangeal joint space (white arrow) was observed and the origin of the radiolucent mass (white arrowhead) appeared to be located within the joint (dotted line, the boundary of the mass).

