

free perforator flap surgery and always have a second option in mind in case of flap failure. Further, a sufficient understanding of the wound characteristics, donor and recipient vessels, and design for inseting should precede the surgery. Lastly, the skin graft over the muscle flap is less durable than the fasciocutaneous flap and tends to form a callus. To prevent this complication, a perforator-based fasciocutaneous chimeric flap, which enables an independent inset of components, seems to be more ideal.

References

1. Kang MJ, Chung CH, Chang YJ, et al. Reconstruction of the lower extremity using free flaps. *Arch Plast Surg* 2013;40:575-83.
2. Zgonis T, Stapleton JJ, Roukis TS. Advanced plastic surgery techniques for soft tissue coverage of the diabetic foot. *Clin Podiatr Med Surg* 2007;24:547-68.
3. Agarwal JP, Agarwal S, Adler N, et al. Refining the intrinsic chimera flap: a review. *Ann Plast Surg* 2009;63:462-7.
4. Hallock GG. Simultaneous transposition of anterior thigh muscle and fascia flaps: an introduction to the chimera flap principle. *Ann Plast Surg* 1991;27:126-31.
5. Kim SW, Youn S, Kim JD, et al. Reconstruction of extensive lower limb defects with thoracodorsal axis chimeric flaps. *Plast Reconstr Surg* 2013;132:470-9.

Medial Sural Artery Perforator Flap: Using the Superficial Venous System to Minimize Flap Congestion

John Ranson, Anais Rosich-Medina, Kavita Amin, Damir Kosutic

Department of Plastic Surgery, The Christie NHS Foundation Trust, Manchester, UK

Correspondence: Damir Kosutic
Department of Plastic Surgery, The Christie NHS Foundation Trust, Wilmslow Road, Didsbury, Manchester, UK
Tel: +44-016-1446-7054, Fax: +44-016-1918-7078
E-mail: dkosutic@hotmail.com

No potential conflict of interest relevant to this article was reported.

Received: 7 Jun 2015 • Revised: 18 Jul 2015 • Accepted: 23 Jul 2015
pISSN: 2234-6163 • eISSN: 2234-6171
<http://dx.doi.org/10.5999/aps.2015.42.6.813> • *Arch Plast Surg* 2015;42:813-815

Copyright © 2015 The Korean Society of Plastic and Reconstructive Surgeons
This is an Open Access article distributed under the terms of the Creative Commons Attribution Non-Commercial License (<http://creativecommons.org/licenses/by-nc/3.0/>) which permits unrestricted non-commercial use, distribution, and reproduction in any medium, provided the original work is properly cited.

Use of the pedicled medial sural artery perforator (MSAP) fasciocutaneous flap has been widely reported in the literature for ipsilateral lower limb reconstruction. Depending on defect location, the MSAP flap may be utilized as a propeller or V-Y advancement flap [1]. This perforator flap is typically based on the proximal perforator of the medial sural artery supplying the gastrocnemius muscle. One of the main issues encountered when performing an MSAP flap is venous congestion [2], a commonly described complication in other perforator based flaps [3]. We describe a useful technique to overcome this problem by including the superficial vein into the original flap design. A 57-year-old woman was referred to our department with a malignant melanoma in the left popliteal fossa. Histologically the lesion was reported as having a 0.8 mm Breslow

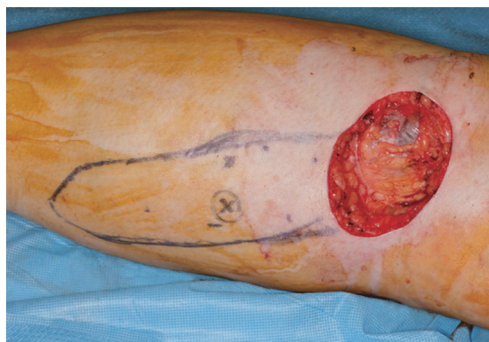

Fig. 1. Wide local excision of malignant melanoma left popliteal fossa with resulting 5 cm × 5.5 cm defect. V-Y advancement flap designed based on a dominant perforator marked with an X.

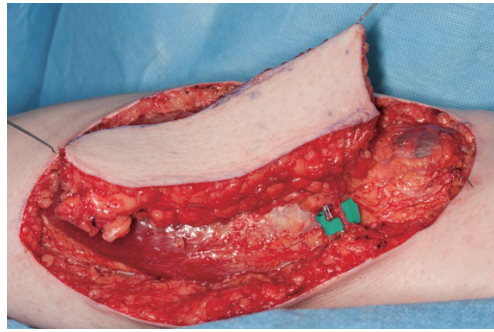


Fig. 2.
The medially located superficial branch of the short saphenous vein.

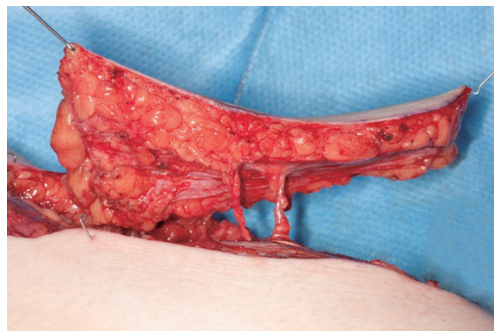

Fig. 3.
Two median sural artery perforators were identified and dissected on the lateral aspect of the flap.

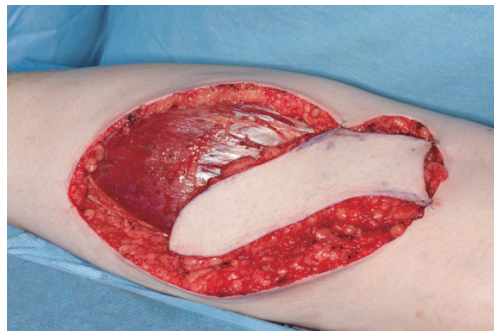

Fig. 4.
V-Y flap raised subfascially and advanced into defect.

thickness. The resulting defect was 5 cm × 5.5 cm (Fig. 1). Handheld Doppler was used to locate and mark the perforators preoperatively across the medial head of gastrocnemius. Although more accurate methods can be used to map the perforator, handheld Doppler offers time efficiency and reduces input from radiological investigations [4]. Flap harvest commenced with an incision placed above the medial border of the medial head of the gastrocnemius. A branch of the long saphenous vein superficial to the fascia was encountered and preserved and seen to enter the medial side flap (Fig. 2). Two perforators were identified. The vein was mobilized free from the lateral skin flap to provide enough mobility for flap advancement. The flap was raised subfascially from distal to proximal with identification and preservation of two MSAP (Fig. 3). The two perforators were skeletonised with minimal intra-muscular dissection.

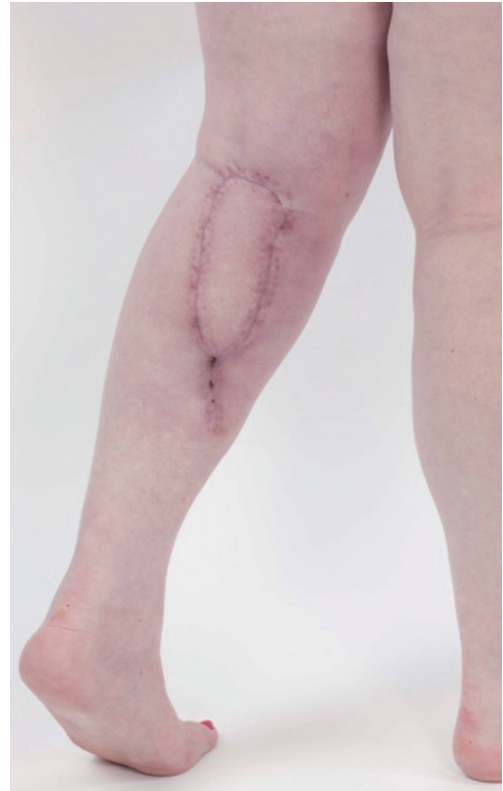

Fig. 5.
Medial sural artery perforator flap 4 months postoperatively.

This ensured the flap could be advanced proximally 5 cm in a V-Y fashion and inset (Fig. 4). No venous congestion was encountered following flap inset (Fig. 5). This case report suggests that venous augmentation with the superficial branch of the long saphenous vein in MSAP flap improves venous drainage, as has previously been described by Hallock [2]. It can most effectively be utilized in V-Y advancement MSAP flaps, where the movement is unidimensional, as no rotation of the flap is required which may lead to vascular compromise and consequent flap compromise. In the distally based flap, the technique of phlebotomy to relieve flap congestion *via* an exteriorised segment of short saphenous vein has been described, contributing to favourable flap survival [5]. Short saphenous branch preservation is a useful and relatively simple method of reducing the risk of MSAP flap congestion without prolonging dissection time.

References

1. Venkataramkrishnan V, Mohan D, Villafane O. Perforator based V-Y advancement flaps in the leg. Br J

- Plast Surg 1998;51:431-5.
- Hallock GG. The medial sural (MEDIAL GASTROCNEMIUS) perforator local flap. *Ann Plast Surg* 2004;53:501-5.
 - Innocenti M, Menichini G, Baldrighi C, et al. Are there risk factors for complications of perforator-based propeller flaps for lower-extremity reconstruction? *Clin Orthop Relat Res* 2014;472:2276-86.
 - Kosutic D, Pejkoivic B, Anderhuber F, et al. Complete mapping of lateral and medial sural artery perforators: anatomical study with Duplex-Doppler ultrasound correlation. *J Plast Reconstr Aesthet Surg* 2012;65:1530-6.
 - Wong CH, Tan BK. Intermittent short saphenous vein phlebectomy: an effective technique of relieving venous congestion in the distally based sural artery flap. *Ann Plast Surg* 2007;58:303-7.

The Use of a Mechanical Stapler in Jejunal Free Flaps in Laryngopharyngectomy Defects

Jaebeom Park¹, Nakheon Kang¹, Sang Ha Oh¹, Sang Il Lee², Seung Han Song¹

Departments of ¹Plastic and Reconstructive Surgery and ²Surgery, Chungnam National University School of Medicine, Daejeon, Korea

Correspondence: Seung Han Song
Department of Plastic and Reconstructive Surgery, Chungnam National University School of Medicine, 282 Munhwa-ro, Jung-gu, Daejeon 35015, Korea
Tel: +82-42-280-7381, Fax: +82-42-280-7384, E-mail: teddylik@naver.com

This work was supported by the research funds of Chungnam National University.

No potential conflict of interest relevant to this article was reported.

Received: 19 May 2015 • Revised: 14 Jul 2015 • Accepted: 7 Sep 2015
pISSN: 2234-6163 • eISSN: 2234-6171
<http://dx.doi.org/10.5999/aps.2015.42.6.815> • *Arch Plast Surg* 2015;42:815-818

Copyright © 2015 The Korean Society of Plastic and Reconstructive Surgeons
This is an Open Access article distributed under the terms of the Creative Commons Attribution Non-Commercial License (<http://creativecommons.org/licenses/by-nc/3.0/>) which permits unrestricted non-commercial use, distribution, and reproduction in any medium, provided the original work is properly cited.

The reconstruction of laryngopharyngectomy defects requires the creation of a tubular passage that connects the pharyngeal remnant to the cervical esophagus. Tubed fasciocutaneous flaps (e.g., from the anterolateral thigh or radial forearm) are most

commonly used, because they permit good postoperative speech and result in low systemic morbidity. However, if a fasciocutaneous flap is unavailable due to a lack of perforators or an obese thigh, the next choice is a jejunal flap. The most common method of securing visceral graft anastomoses was previously one or two layers of hand sewing. However, circular mechanical staplers have been commonly used by general surgeons for enteric anastomosis and lead to similar or lower anastomotic leakage and stricture rates than hand sewing [1,2]. Stapled anastomoses may also reduce the mean operating time by reducing the time required for anastomosis, and also probably reduce blood loss and the likelihood of intraoperative contamination [3]. The ischemic time seems to be a very important factor affecting the likelihood of postoperative complications, especially for free flaps. In particular, the intestine is more vulnerable to ischemia than the skin and bone [4]. In this report, the use of circular mechanical stapling for jejunoesophageal anastomosis was reviewed to assess whether it is a good alternative to hand-sewn anastomoses in the reconstruction area.

Jejunal free flap surgery was performed in six patients with a total laryngopharyngectomy defect between March 2009 and January 2013. Total laryngopharyngectomy was performed to treat hypopharyngeal cancer in four cases and to treat glottis cancer in two cases. All patient specimens were diagnosed as squamous cell carcinoma by a

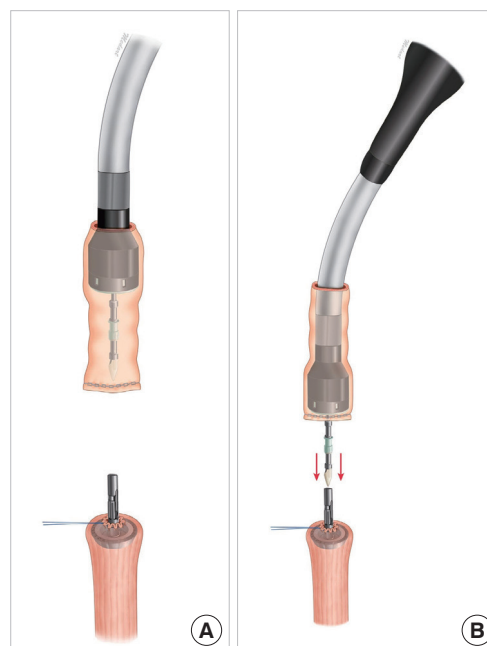


Fig. 1. Diagram of the anastomosis process. (A) Diagram showing the proximal esophagus with the trocar in place and retraction (purse-string) sutures for dilating and sizing the esophageal lumen. (B) The pierced jejunum is seated within the stapler cartridge.