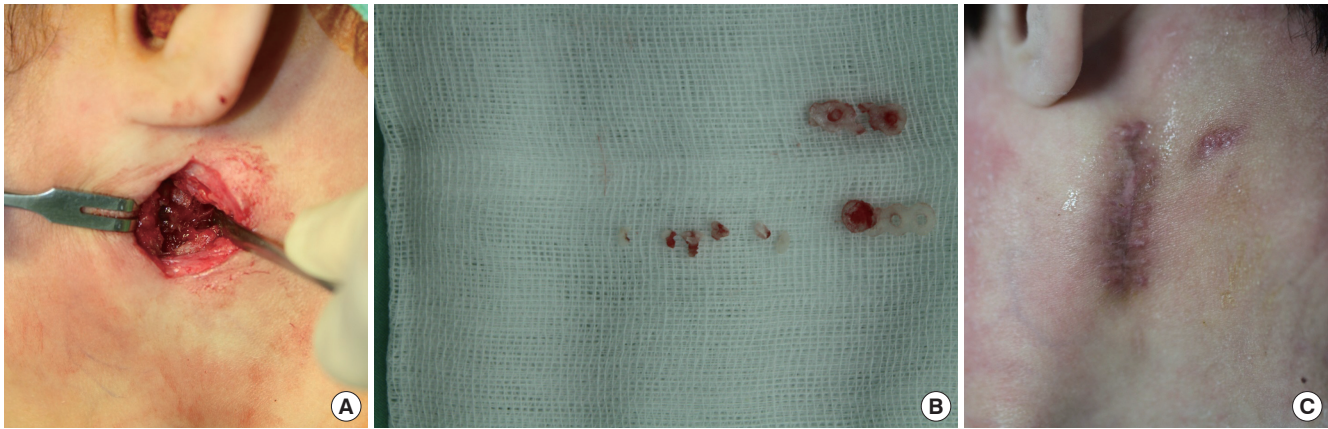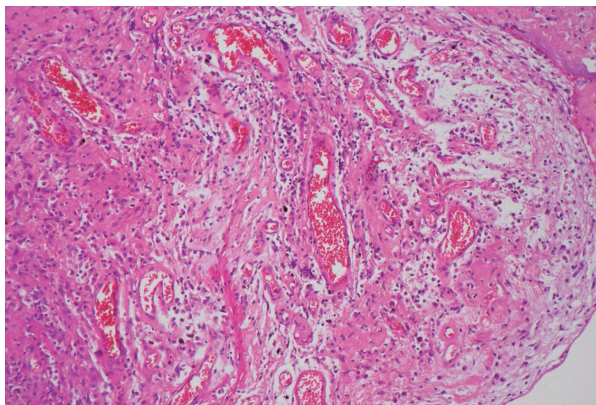
**Fig. 2.**

(A) Intraoperative view of the operation field. (B) Remnant of the absorbable plate and screw. (C) Follow-up photograph at 15 days postoperatively.

**Fig. 3.**

Microscopic finding of the mass. The specimen shows focal loose granulation tissue with some macrophages. The remaining portion shows fibrosis (H&E, $\times 40$).

complication in mandibular fracture fixation using the absorbable fixator method. Normally, where mass growth is initiated in an acute postoperative period, primary infection is most likely considerable. However, in the case described above, where the mass showed late growth, circumstantial evaluation of the mass itself is important. Accurate knowledge of types of complication will eventually be helpful in proper management of operation site mass genesis.

References

1. Choi HJ, Kim W, Youn S, et al. Management of delayed infection after insertion of bioresorbable plates at the infraorbital rim. *J Craniofac Surg* 2012;23:524-5.
2. Lee JH, Chang JW, Choi MS, et al. Delayed infection after a zygoma fracture fixation with absorbable plates. *J Craniofac Surg* 2010;21:2018-9.
3. Tripathi N, Goyal M, Mishra B, et al. Zygomatic

complex fracture: a comparative evaluation of stability using titanium and bio-resorbable plates as one point fixation. *Natl J Maxillofac Surg* 2013;4:181-7.

4. Losken HW, van Aalst JA, Mooney MP, et al.

Biodegradation of Inion fast-absorbing biodegradable plates and screws. *J Craniofac Surg* 2008;19:748-56.

5. Laughlin RM, Block MS, Wilk R, et al. Resorbable plates for the fixation of mandibular fractures: a prospective study. *J Oral Maxillofac Surg* 2007;65:89-96.

Cutaneous Fusariosis in Unprotected Snake Bite Wound of Farmer's Hand

Eun Taik Son¹, Hwan Jun Choi¹, Young Man Lee¹, Jun Hyuk Kim¹, Doo Hyun Nam¹, Hyun Deuk Cho²

Departments of ¹Plastic and Reconstructive Surgery and ²Pathology, Soonchunhyang University College of Medicine, Cheonan, Korea

Correspondence: Hwan Jun Choi

Department of Plastic and Reconstructive Surgery, Soonchunhyang University, College of Medicine, 31 Suncheonhyang 6-gil, Dongnam-gu, Cheonan 330-721, Korea

Tel: +82-41-570-2195, Fax: +82-41-574-6133, E-mail: medi619@hanmail.net

This work was supported by the Soonchunhyang University Research Fund.

No potential conflict of interest relevant to this article was reported.

Received: 18 Jul 2014 • Revised: 25 Aug 2014 • Accepted: 4 Sep 2014
pISSN: 2234-6163 • eISSN: 2234-6171
<http://dx.doi.org/10.5999/aps.2015.42.2.254> • Arch Plast Surg 2015;42:254-256

Copyright © 2015 The Korean Society of Plastic and Reconstructive Surgeons
This is an Open Access article distributed under the terms of the Creative Commons Attribution Non-Commercial License (<http://creativecommons.org/licenses/by-nc/3.0/>) which permits unrestricted non-commercial use, distribution, and reproduction in any medium, provided the original work is properly cited.

The genus *Fusarium* is widespread in soil, plants, and the air, and broad manifestations of human disease

can be caused by infection with it, which can be superficial, locally invasive, or disseminated infections, including mycotoxicosis [1]. One of the most frequent aspects of infection by *Fusarium* species is the development of skin lesions; such lesions are typically the only source for diagnosis [2]. Thus, diagnosis and treatment of human *Fusarium* infection is usually delayed, causing poor results.

We report on a case of cutaneous fusariosis caused by continuous soil and plant contamination of an open wound that formed after a snake bite on the hand. The infection was ultimately treated and there was no recurrence after three months.

The patient was an 81-year-old, otherwise healthy woman. She was a farmer and had a history of abusing oral corticosteroids due to arthritis from approximately five years until one year ago (2006 to 2011). She was transferred to our hospital with a painful progressive skin ulceration around her right third knuckle and proximal phalanx after a snake bite two weeks earlier (Fig. 1). After the snake bite, she continued working on the farm without wound protection and the bite wound worsened.

First, because she was healthy, the lesion was evaluated for bacterial infection and methicillin-resistant *Staphylococcus aureus* was cultured from a swab specimen. Intravenous vancomycin was continued for two weeks and the patient underwent serial surgical debridement, and, two weeks later, a full-thickness skin graft surgery was performed. However, one week after surgery, progressive eschar formation was observed from the distal tip of the graft to the distal aspect. At three weeks after surgery, a skin defect and eschar formed from the distal half of the grafted skin to the middle third of the proximal phalanx. We expected possibility of other kind of infection because wound healing was delayed and she has a history of working on the farm without wound protection. She was readmitted to the hospital, and a tissue biopsy was taken. Microscopic examination of the surgical specimen revealed fungal hyphae and necrotic tissue (Fig. 2). However, there was no evidence of immunocompromised status, such as neutropenia basis her laboratory finding and there was not any other systemic symptom. A diagnosis of cutaneous fusariosis was made, and the patient underwent aggressive surgical debridement.

Intravenous amphotericin B (Fungizone 50 mg; BMS Pharmaceutical Korea Ltd., Seoul, Korea) 1 mg/kg daily, was started and continued for one week and switched to oral voriconazole (Vfend 200 mg;

Pfizer Inc., Seoul, Korea) 200 mg twice daily for four weeks. After ensuring that there were no fungal hyphae or fungi growth in tissue culture, a second operation (full-thickness skin graft) was performed. Six months after the operation, there was no evidence of recurrence (Fig. 3).

The genus *Fusarium* is widely distributed in plants and soil in temperate and tropical climates. Microscopically, the hyphae of *Fusarium* have multiple filaments, which are hyaline, septate, 3–8 μ m in diameter, and typically branch at acute or right angles. The most frequent human *Fusarium* isolates are *Fusarium solani*, *Fusarium oxysporum*, and *Fusarium proliferatum*, however, species differentiation may be difficult except in specialized laboratories [3]. *Fusarium* species possesses several virulence factors, including the production of trichothecene and other mycotoxins. These mycotoxins can suppress humoral and cellular immunity, and cause break down of tissue [4]. Such skin breakdown may precede infection by up to one year [2].

The majority of immunocompetent patients (77%) have a history of recent skin breakdown at the lesion of cutaneous fusariosis, either as a result of trauma (54%) or preexisting onychomycosis (23%) [2]. Skin lesions may vary, including granulomas, ulcers, nodules, mycetomas, necrosis, panniculitis, and intertrigo [5].

For the diagnosis of cutaneous fusariosis, a meticulous physical examination is required for identification of suspicious skin lesions with tissue breakdown and all suspicious lesions should be

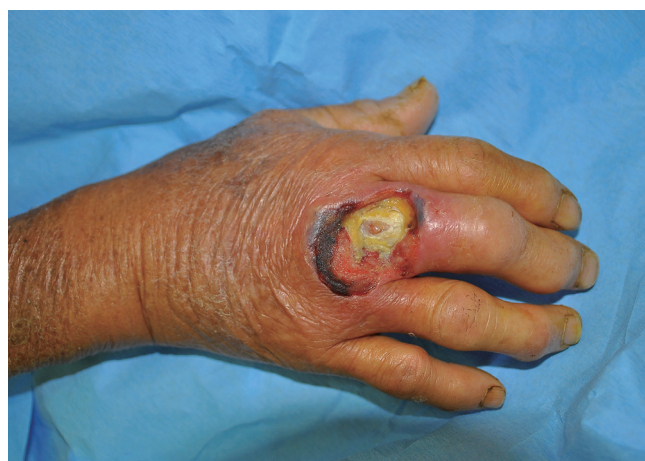

Fig. 1.

Photograph of the subject when she first visited the hospital. There was a painful progressive skin ulceration around the right third knuckle and proximal phalanx after a snake bite two weeks earlier.

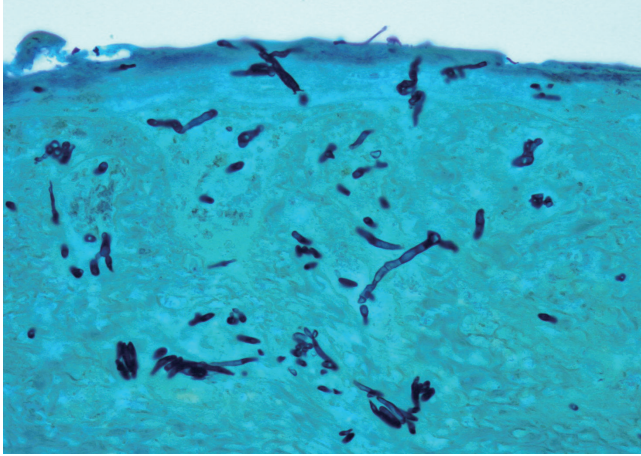


Fig. 2. Septate fungal hyphae of *Fusarium* species in a high-power view of a tissue biopsy specimen (GMS stain, $\times 400$).

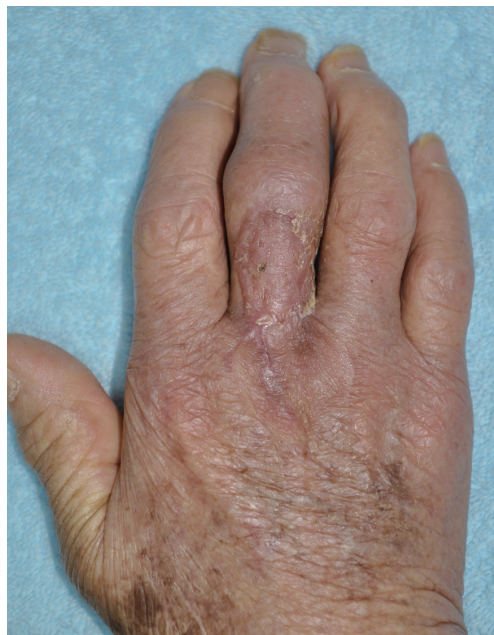

Fig. 3. A second operation (full-thickness skin graft) was performed, and, three months postoperatively, there was no evidence of recurrence.

cultured, and a biopsy should be performed [2]. If *Fusarium* species are identified in culture or biopsy, aggressive debridement should be performed and antifungal therapy should be administered. Previous guidelines recommended amphotericin B for treatment of fungal infections, including *Fusarium* infection, however, in a recent analysis, voriconazole was recommended as the most cost-effective therapy [4]. Treatment of cutaneous fusariosis is usually successful. Determination of the endpoint of antifungal treatment should be made by serial tissue cultures and biopsies, until there is no growth in culture and no fungal hyphae in a biopsy.

In our case, because methicillin-resistant *Staphylococcus aureus* infection was demonstrated by culture, a fungal infection was not considered initially and diagnosis was delayed. In addition, the patient had a history of long-term corticosteroid abuse, which had likely weakened her immune resistance to infection and had caused thinning of her skin. Her skin was broken by a snake bite, and she continued to work on a farm even after the bite without protecting the wound. These events allowed continuous penetration of *Fusarium* and might easily have enabled colonization.

In a patient who has chronic wounds with sustained farming, fungal infection should be suspected. Also, because skin breakdown due to infection may precede illness by up to one year, it is necessary to obtain a detailed history of the patients' behavior. In addition, a tissue biopsy should be recommended because it provides the only diagnostic clue.

References

1. Dignani MC, Anaissie E. Human fusariosis. *Clin Microbiol Infect* 2004;10 Suppl 1:67-75.
2. Nucci M, Anaissie E. Cutaneous infection by *Fusarium* species in healthy and immunocompromised hosts: implications for diagnosis and management. *Clin Infect Dis* 2002;35:909-20.
3. Fleming RV, Walsh TJ, Anaissie EJ. Emerging and less common fungal pathogens. *Infect Dis Clin North Am* 2002;16:915-33.
4. Al-Badriyeh D, Heng SC, Neoh CF, et al. Pharmacoeconomics of voriconazole in the management of invasive fungal infections. *Expert Rev Pharmacoecon Outcomes Res* 2010;10:623-36.
5. Nelson PE, Dignani MC, Anaissie EJ. Taxonomy, biology, and clinical aspects of *Fusarium* species. *Clin Microbiol Rev* 1994;7:479-504.