

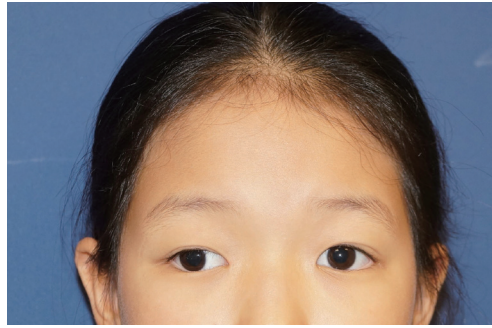

Fig. 5.
One year post-trauma.
Levator and papillary function
had almost recovered to the
normal range.

was limited to early steroid therapy and occlusion therapy. The prognosis of oculomotor nerve palsy varies according to its etiology and the associated neurological problems. Some authors suggest waiting for at least six months before strabismus surgery, which permits the cause of oculomotor palsy to be evaluated and allows for possible spontaneous recovery [2]. A surgical approach, including strabismus surgery and ptosis surgery, should be considered according to the degree of recovery. We suggest that plastic surgeons keep in mind that facial trauma may occur in combination with various cranial nerve injuries and therefore should evaluate patients with facial trauma for the symptoms and signs of cranial nerve injuries.

References

1. Kaido T, Tanaka Y, Kanemoto Y, et al. Traumatic oculomotor nerve palsy. *J Clin Neurosci* 2006;13:852-5.
2. Schumacher-Feero LA, Yoo KW, Solari FM, et al. Third cranial nerve palsy in children. *Am J Ophthalmol* 1999;128:216-21.
3. Elston JS. Traumatic third nerve palsy. *Br J Ophthalmol* 1984;68:538-43.
4. Saeki N, Yotsukura J, Adachi E, et al. Isolated superior division oculomotor palsy in a child with spontaneous recovery. *J Clin Neurosci* 2000;7:62-4.
5. Sato H, Hashimoto T, Yoneda S, et al. Lymphoma as a cause of isolated oculomotor nerve palsy. *J Clin Neurosci* 2011;18:1256-8.

Delayed Methicillin-Resistant *Staphylococcus aureus* Infection on a Mandibular Angle Fracture with Absorbable Plates

Han Moi Choi, Soon Heum Kim, Cheol Keun Kim, Hyun Gon Choi, Dong Hyeok Shin, Ki Il Uhm, Dongin Jo

Department of Plastic Surgery, Konkuk University Hospital, Konkuk University School of Medicine, Chungju, Korea

Correspondence: Dongin Jo
Department of Plastic Surgery, Konkuk University Hospital, Konkuk University School of Medicine, 82 Gugwon-daero, Chungju 380-704, Korea
Tel: +82-10-8742-0831, Fax: +82-43-840-8962, E-mail: dijo@medigate.net

No potential conflict of interest relevant to this article was reported.

Received: 13 May 2014 • Revised: 12 Jul 2014 • Accepted: 12 Jul 2014
pISSN: 2234-6163 • eISSN: 2234-6171
<http://dx.doi.org/10.5999/aps.2015.42.2.252> • *Arch Plast Surg* 2015;42:252-254

Copyright © 2015 The Korean Society of Plastic and Reconstructive Surgeons
This is an Open Access article distributed under the terms of the Creative Commons Attribution Non-Commercial License (<http://creativecommons.org/licenses/by-nc/3.0/>) which permits unrestricted non-commercial use, distribution, and reproduction in any medium, provided the original work is properly cited.

Absorbable fixation is used worldwide for bone fixation. Because it is absorbed into the body by a hydrolysis process, removal is unnecessary. Inflammation, swelling, and acute infection can occur [1], but with less frequency in delayed type infections [2]. The authors report on a case of infection that was delayed for one year in a patient who underwent mandibular fracture fixation using absorbable plates. A 17-year-old male arrived as an outpatient with a chief complaint of a left mandibular mass. His past history included seizure and mental retardation due to hydrocephalus (diagnosed at six months after birth) and a medication history of asthma. One year ago, he underwent a procedure of open reduction using absorbable plates on his mandible. Five weeks after fixation, wound dehiscence and purulent discharge was noted and revision was performed. Methicillin-resistant *Staphylococcus aureus* (MRSA) was cultured from discharge of the wound. Vancomycin 500 mg was administered in IV form for seven days until no microbium was cultured from the wound. After revision, the wound showed improvement.

When the patient visited our outpatient department, a firm round mass was palpated at the left mandibular margin (Fig. 1). The nature of the mass was hard and fixed with adjacent tissues. Redness, heating sense,

and swelling were observed around the mass. Communication was difficult due to the patient's status of hydrocephalus; however, avoidance of palpation indicated possible tenderness near the mass. The patient's initial white blood cell, C-reactive protein, erythrocyte sedimentation rate lab, and a plain radiograph showed no specific finding. Ultrasonography showed a small abscess in the left mandibular angle. Computed tomography angiography was performed for further evaluation and combined osteomyelitis and an abscess with osteophytes surrounding the mandible were suspected. Despite treatment with medication, the patient showed no improvement. Therefore, our department took the next step, resection of the osteomyelitic lesion with minor abscesses. Under general anesthesia, the patient was placed in a supine position. His previous operation site allowed an approach to the mandible, where the lesion was located. Partial division of the masseter muscle also allowed an approach to the mandible. The mass was composed of infected soft tissue and granulation tissue (Fig. 2). Some serous discharge and degradation parts of the implant were observed on the cortical bone. Swab culture and tissue biopsy was performed. There was no sign of osteomyelitis and cortical bone integrity was observed, therefore, bone resection was unnecessary. Finally, irrigation was performed followed by drain insertion and layer by layer suture. The drain was removed on postoperative day (POD) #2, leaving no sign of skin complication. On POD #5, vancomycin was applied due to the positive MRSA result from wound culture. Tissue biopsy showed some macrophages containing granulation tissue (Fig. 3). The patient had no abnormal lab results during the admission period. Two weeks after surgery, the patient had made a full recovery, and has remained in good health.

Biodegradable plate and screw are often used in craniofacial skeleton surgery. Polyglycolide, developed by Dexon in 1970, is the first absorbable fixation to be synthesized, followed by PDS, vicryl. Absorbable fixation is currently used successfully [3], with materials based on lactic, glycolic acid. Superior material is helpful in maintaining strength of surrounding tissues, thereby preventing inflammation, toxic effect, and carcinogenic response until the wound is completely healed. Degradation of the absorbable material is influenced by many factors. For example, size of implant, type of material, characteristics of insertion location of materials, vascularity of the

tissue surrounding implantation, age, general health, etc. There are two degradation phases, phase I (hydrolysis) and phase II. Phase I is an active degradation phase as contact with water is initiated. Phase II involves conversion of degradation into CO_2 , H_2O by macrophages, and initiation of the tricarboxylic acid cycle metabolism. Balance of hydrolysis and metabolism is important, due to the fact that if the amount of hydrolysis product exceeds the amount of metabolism, inflammation will occur. In this case, it is thought that infection resulted from a remnant of previous wound tissue and absorbable fixators. Complete absorption of absorbable fixators could take more than 12 months [4]. During that period, infection at absorbable fixators is possible. A degraded absorbable fixator acts like a culture medium of microbium.

According to research reported by Laughlin et al. [5], neither infection rate nor revision rate was higher for patients with a mandible fracture who underwent an operation using an absorbable plate, compared to metal fixation. Out of 50 patients with a mandible fracture, 6% had infection, 4% with hardware removal. In the control group described in the review article, out of 617 patients, 3.9% had nonunion/fibrous union, 13% with infection, and 18.9% had hardware removal. Accordingly, regular follow up is essential for use of absorbable fixators in patients. Infection is the most important and considerable

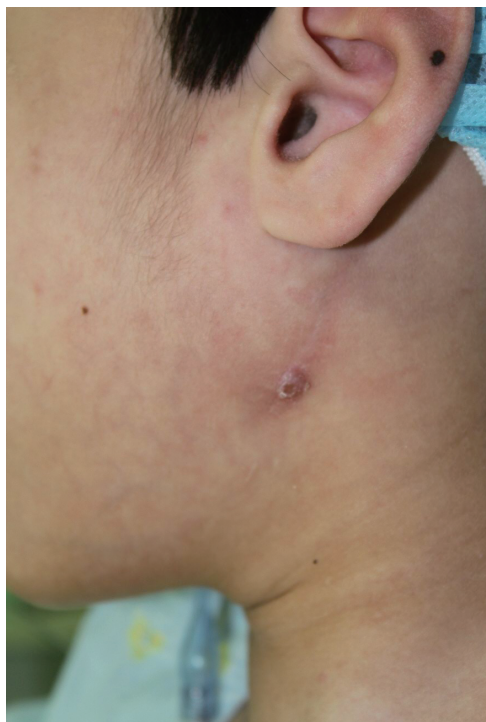

Fig. 1.
Preoperative view of the mass.

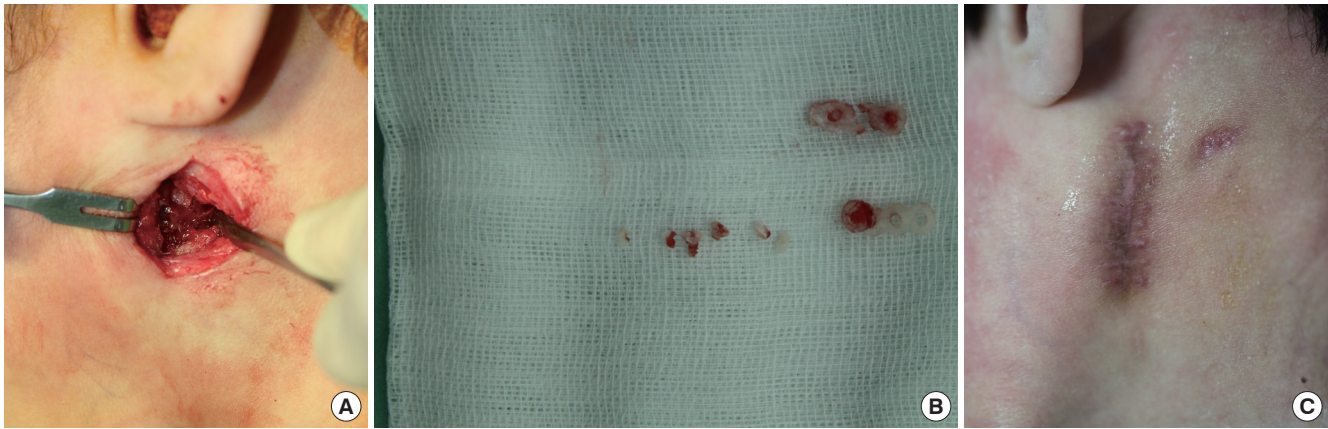


Fig. 2.

(A) Intraoperative view of the operation field. (B) Remnant of the absorbable plate and screw. (C) Follow-up photograph at 15 days postoperatively.

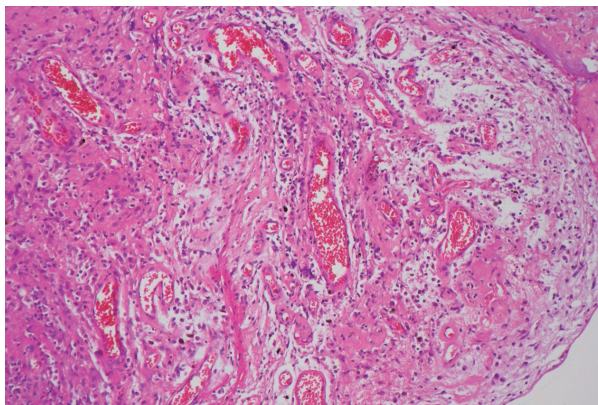


Fig. 3.

Microscopic finding of the mass. The specimen shows focal loose granulation tissue with some macrophages. The remaining portion shows fibrosis (H&E, $\times 40$).

complication in mandibular fracture fixation using the absorbable fixator method. Normally, where mass growth is initiated in an acute postoperative period, primary infection is most likely considerable.

However, in the case described above, where the mass showed late growth, circumstantial evaluation of the mass itself is important. Accurate knowledge of types of complication will eventually be helpful in proper management of operation site mass genesis.

References

1. Choi HJ, Kim W, Youn S, et al. Management of delayed infection after insertion of bioresorbable plates at the infraorbital rim. *J Craniofac Surg* 2012;23:524-5.
2. Lee JH, Chang JW, Choi MS, et al. Delayed infection after a zygoma fracture fixation with absorbable plates. *J Craniofac Surg* 2010;21:2018-9.
3. Tripathi N, Goyal M, Mishra B, et al. Zygomatic

complex fracture: a comparative evaluation of stability using titanium and bio-resorbable plates as one point fixation. *Natl J Maxillofac Surg* 2013;4:181-7.

4. Losken HW, van Aalst JA, Mooney MP, et al.

Biodegradation of Inion fast-absorbing biodegradable plates and screws. *J Craniofac Surg* 2008;19:748-56.

5. Laughlin RM, Block MS, Wilk R, et al. Resorbable plates for the fixation of mandibular fractures: a prospective study. *J Oral Maxillofac Surg* 2007;65:89-96.

Cutaneous Fusariosis in Unprotected Snake Bite Wound of Farmer's Hand

Eun Taik Son¹, Hwan Jun Choi¹, Young Man Lee¹, Jun Hyuk Kim¹, Doo Hyun Nam¹, Hyun Deuk Cho²

Departments of ¹Plastic and Reconstructive Surgery and ²Pathology, Soonchunhyang University College of Medicine, Cheonan, Korea

Correspondence: Hwan Jun Choi

Department of Plastic and Reconstructive Surgery, Soonchunhyang University, College of Medicine, 31 Suncheonhyang 6-gil, Dongnam-gu, Cheonan 330-721, Korea

Tel: +82-41-570-2195, Fax: +82-41-574-6133, E-mail: medi619@hanmail.net

This work was supported by the Soonchunhyang University Research Fund.

No potential conflict of interest relevant to this article was reported.

Received: 18 Jul 2014 • Revised: 25 Aug 2014 • Accepted: 4 Sep 2014
pISSN: 2234-6163 • eISSN: 2234-6171
<http://dx.doi.org/10.5999/aps.2015.42.2.254> • Arch Plast Surg 2015;42:254-256

Copyright © 2015 The Korean Society of Plastic and Reconstructive Surgeons
This is an Open Access article distributed under the terms of the Creative Commons Attribution Non-Commercial License (<http://creativecommons.org/licenses/by-nc/3.0/>) which permits unrestricted non-commercial use, distribution, and reproduction in any medium, provided the original work is properly cited.

The genus *Fusarium* is widespread in soil, plants, and the air, and broad manifestations of human disease