

Retrospective Analysis of the One-per-Million Tumescence Technique in Post-Burn Hand Deformity Surgeries

Theddeus OH Prasetyono¹, Astrid Felicia Koswara²

¹Division of Plastic Surgery, Department of Surgery, Faculty of Medicine, University of Indonesia and Cipto Mangunkusumo Hospital, Jakarta; ²Diponegoro 71 Jakarta 13410, Jakarta, Indonesia

Original Article

Background The use of a tourniquet in hand surgery is generally accepted as necessary to create a clear visualization of the operative field. This study aims to determine the effectiveness of one-per-million tumescent solution (1:1,000,000 epinephrine concentration) in creating a bloodless operative field in post-burn hand deformity surgeries performed without a tourniquet.

Methods This retrospective observational study was conducted on a series of 12 patients with post-burn hand deformities who underwent surgery between February 2013 and January 2014. A total of 29 operative fields were recorded. The one-per-million tumescent solution was used for hemostasis instead of a tourniquet. The clarity of the operative field, volume of solution injected, duration of surgery, scar thickness and density, and functional outcomes at least three months after the surgery were observed. The relationship of scar thickness and density with the clarity of the operative field was analyzed with the chi-square test.

Results Of the 29 operative fields in which the one-per-million tumescent technique was used, 48.2% were totally bloodless, 44.8% had minimal bleeding, and 6.9% had an acceptable level of bleeding. Both scar thickness and density were shown to have a significant relationship with operative field clarity ($P < 0.05$).

Conclusions The one-per-million tumescent technique is effective in facilitating post-burn hand deformity surgeries involving meticulous, multiple, and lengthy procedures by creating a relatively clear operative field without the use of a tourniquet. Although scar thickness and density are associated with the clarity of the operative field, this technique can be considered safe and effective in creating a clear operative field.

Keywords Burns / Contracture / Cicatrix / Epinephrine / Hand

Correspondence:

Theddeus OH Prasetyono
Division of Plastic Surgery, Department of Surgery, Faculty of Medicine, University of Indonesia and Cipto Mangunkusumo Hospital, Medical Staff Building 4th floor Jl. Diponegoro, 71 Jakarta 13410, Indonesia
Tel: +62-817858899
Fax: +62-21-3905556
E-mail: teddyohprasetyono@yahoo.com

This article contains supplemental Tables S1, S2, and Video S1.

No potential conflict of interest relevant to this article was reported.

Received: 16 Oct 2014 • Revised: 20 Nov 2014 • Accepted: 1 Dec 2014

pISSN: 2234-6163 • eISSN: 2234-6171 • <http://dx.doi.org/10.5999/aps.2015.42.2.164> • Arch Plast Surg 2015;42:164-172

INTRODUCTION

For centuries, tourniquets have been used to create clear operating fields in the extremities [1]. A pioneer in hand surgery, Ster-

ling Bunnell, once said: "Operating on a hand without a tourniquet is like trying to fix a watch in a bottle of ink" [2]. Hence, it has become an established paradigm that tourniquet use is required in extremity surgery, including contracture release sur-

gery for severely burned hands.

Burn scar excision is generally accompanied by significant blood loss [3,4]. This blood loss may be due to the higher vascularity of hypertrophic scar tissue compared to normal tissue [5]. Moreover, surgery for burn scars on the hand, with or without contracture, usually requires a relatively long amount of time (more than two hours) due to complex deformities in multiple digits and the tedious work of suturing the skin graft. This prolonged surgery can result in the prolonged use of a tourniquet, which has the potential to cause complications such as skin damage [6], pressure-induced nerve damage [6-8], and ischemic muscle damage [6]. To avoid such complications, alternative non-tourniquet techniques are a possibility for lengthy procedures.

Numerous studies have proven the safety of epinephrine with concentrations ranging from 1:80,000 to 1:400,000 in a tumescent solution when used for various upper extremity surgeries [9-14]. Our team [15,16] has reported the use of a 1:1,000,000 (one-per-million) epinephrine tumescent formula. This concentration is very low compared to earlier studies involving a tumescent solution. Nonetheless, the one-per-million tumescent solution has been used in a wide variety of hand and upper extremity cases. However, no study has focused exclusively on the use of tumescent injections in post-burn hand deformity surgery. Thus, this study was carried out to determine the effectiveness of a technique using the one-per-million tumescent solution in post-burn hand deformity surgery.

METHODS

A case series was conducted on the application of the one-per-million tumescent technique in surgery on post-burn hand deformities without the use of a tourniquet. Information was taken from the medical records of all patients who underwent post-burn hand deformity surgery from February 2013 to January 2014. This study protocol conformed to the principles outlined in the Declaration of Helsinki and received approval from the Institutional Review Board. We obtained written informed consent from each patient. Data were recorded on the clarity of the operative field, the quantity of the tumescent solution injected, the length of surgery, the assessment of the burn scar, and the functional outcomes. It was possible for one patient to have multiple operative fields.

The one-per-million tumescent solution was formulated as 1:1,000,000 epinephrine and 0.2% lidocaine in saline solution [15]. To obtain a bloodless surgical field, the tumescent solution was injected locally into the subcutaneous tissue and, if possible, the scar tissue until the skin area turned pale. Seven to

10 minutes after the last injection is mandatory waiting time before the first incision can be made.

The first author subjectively assessed the clarity of each operative field and then sorted them into four different categories: totally bloodless, minimal bleeding, acceptable bleeding, and bloody. A totally bloodless operative field was as bloodless as would have been achieved by pneumatic tourniquet use. Minimal bleeding refers to slight bleeding that does not affect the clarity of the operative field nor the ability to recognition of the anatomical structures. Acceptable bleeding includes bleeding that requires more gauze sweepings in order to keep the anatomical structures recognizable without causing difficulties to the surgeon performing the procedure. The last category, a bloody operative field, is defined as involving bleeding that disturbs the recognition of anatomical structures and requires the additional use of a pneumatic tourniquet [15].

The assessment of the thickness and density of burn scars was performed using modified Vancouver Scar Scale (VSS) categories. The thickness and density were assessed according to the VSS height and pliability categories, respectively [17]. Unlike the original VSS height measurement, which only measures the height of a burn scar from the surface level of surrounding normal skin, we assessed the scar thickness by summing the scar height both above and under the normal skin surface level. The thickness was categorized as thin, moderate, and thick. A thin burn scar was defined as having a depth of less than 2 mm. A moderate burn scar was defined as a scar with a thickness of 2–5 mm. Burn scars more than 5 mm thick were categorized as thick burn scars.

The density of burn scars was subjectively assessed. Burn scars were classified into three categories according to their density: pliable, moderate, and high. Pliable is equivalent to the VSS category of supple, implying a scar that yields with minimal resistance. Moderate density is similar to the VSS category of yielding, which means a yielding scar that has moderate resistance but does not form a solid mass. High density has the same meaning as the VSS category of firm, referring to a firm scar that moves as a solid inflexible unit [17]. The relationship of scar thickness and density with the clarity of the operative field was analyzed with the chi-square test.

To assess the outcome of the operations, we recorded overall function by measuring the range of motion of the respective hands, elbow, and axilla at least three months after each procedure. By modifying two range of motion assessment classifications as presented by Schwanholt et al. [18] and Schwarz [19], we sorted the final outcomes into four categories of overall active function: excellent, good, fair, and poor. Excellent function was defined as full extension (0 degrees) of all fingers, full to 170 degrees of elbow extension, and full to 170 degrees of axilla

abduction. Good function was defined as finger flexion of five degrees at active extension, evidence of webbing, 130 to 170 degrees of elbow extension, and 130 to 170 degrees of axilla abduction. Fair function was defined to include hands with flexion contractures from five to 30 degrees at active extension, 90 to 130 degrees of elbow extension, and 90 to 130 degrees of axilla abduction. Poor function was defined to include hands with flexion contracture over 30 degrees, elbow extensions of less than 90 degrees, and axilla abductions of less than 90 degrees.

Distinct criteria for evaluating abduction/hyperextension function were created to assess thumb abduction and any hyperextension of the fingers. Satisfactory function was defined as thumb abduction ≥ 50 degrees and/or no finger hyperextension, while mediocre function was defined as thumb abduction < 50 degrees and/or any degree of finger hyperextension (Supplemental Table S1).

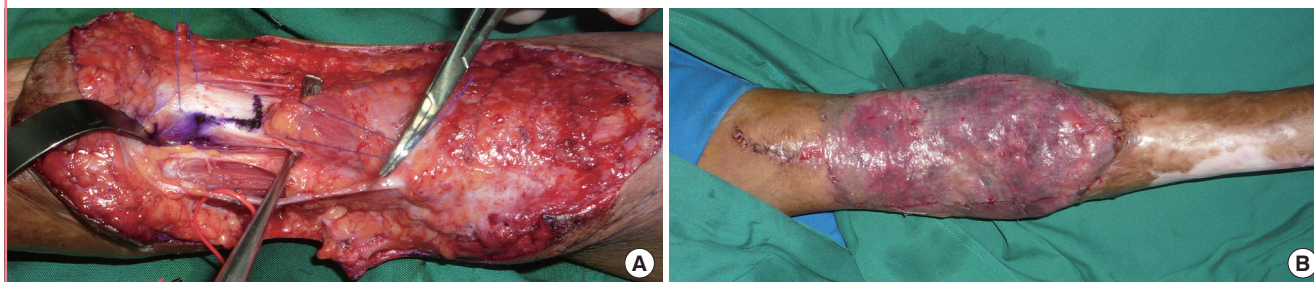
Fig. 1. Unification of adjacent operative fields

Operative field 19 in patient 5 consisted of three operative fields on the right hand. The three operative fields were located adjacent to one another, resulting in the confluence of injections. Thus, the three operative fields were ultimately characterized as a single operative field with regard to the assessment of operative field clarity.

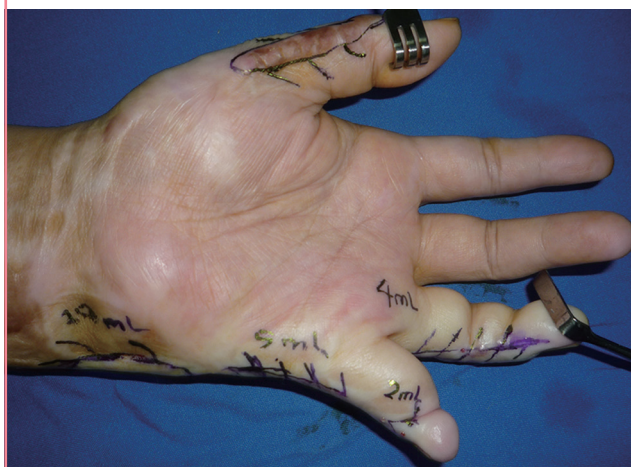

Fig. 2. A totally bloodless operative field

An example of a totally bloodless operative field, in patient 6, operative field 20. (A) The anatomical structures can be easily distinguished in this extensive operative field aimed at releasing elbow contracture. The operative field was designed for a procedure that would lengthen the biceps tendon. (B) An immediate postoperative picture shows a split thickness skin graft used to resurface the defect.



RESULTS

Overall, we treated 12 patients, including nine (75%) males and three (25%) females (Table 1), with various deformities due to burns on their hands and upper extremities. Their ages ranged from 1.3 years to 61 years, with an average of 19.9 years (± 19.182 years).

Initially, 35 operative fields were analyzed. Six of them were modified in the individual analysis due to the confluent effect of the injected solution with the neighboring fields, as shown in Fig. 1. As those six operative fields were merged with the neighboring fields, a total of 29 operative fields were included in the final analysis.

Of the 29 operative fields, 14 (48.2%) were totally bloodless, 13 (44.8%) had minimal bleeding, two (6.9%) had acceptable bleeding, and none had a bloody operative field. Fig. 2 shows an example of a totally bloodless operative field (Supplemental Video S1).

Measuring scar thickness showed that 16 (55.2%) operative fields had thin scars, nine (31.0%) had scars of moderate thickness, and four (13.8%) had thick scars. As for scar density, 14 (48.3%) operative fields contained pliable scars, 10 (34.5%) involved scars of moderate density, and five (17.2%) contained scars with high density (Supplemental Table S2).

All procedures were performed under general anesthesia. The surgery duration ranged from 80 to 450 minutes, with an average of 272.7 minutes (± 143.260 minutes). The volume of tumescent solution used ranged from two to 128 mL, with a median of 12 mL. No additional tumescent injections were given during surgery.

Some flaps were created to release the contractures and cover the resulting defects, which included multiple z-plasties, web triangular flaps, and islanded flaps. Without including the z-plasties, there were seven local and regional flaps; six triangular flaps, and one islanded digital flap. None of these seven flaps under-

Table 1. Patient characteristics and operative field information

Patient no.	Age (yr)	Sex	Operative field	Diagnosis	Procedure	No. of flaps (excluding multiple-Z)	Type of anesthesia (GA/LA) ^{a)}	Volume of TS (mL)	Clarity of operative field	Length of surgery (min)
1	39	Male	1 Left clawed little finger	Left clawed little finger	Lateral slip repositioning		GA	9	Totally bloodless	360
			2 Left first web space contracture	Left first web space contracture	Contracture release and FTSG			20	Totally bloodless	
			3 Right clawed little finger	Right clawed little finger	Lateral slip repositioning and multiple Z-plasty			18.5	Totally bloodless	
			4 Right second, third, and fourth web space contractures	Right second, third, and fourth web space contractures	Multiple Z-plasty, web triangular flap	1 TF		16	Totally bloodless	
2	23	Male	5 Right clawed little finger	Right clawed little finger	Dorsal PIPJ capsular plication and MPJ volar plate reconstruction with FDS graft		GA	21	Minimal bleeding	300
			Right second, third, and fourth web space contractures	Right second, third, and fourth web space contractures	Multiple Z-plasty and web triangular flap	1 TF				
			6 Right radial linear contracture	Right radial linear contracture	Multiple Z-plasty			5	Minimal bleeding	
			7 Left first web space contracture	Left first web space contracture	Multiple Z-plasty			12	Minimal bleeding	
3	24	Male	8 Left clawed little finger	Left clawed little finger	Dorsal PIPJ capsular plication and MPJ volar plate reconstruction with FDS graft		GA	8	Totally bloodless	180
			9 Linear contracture of left index finger	Linear contracture of left index finger	Multiple Z-plasty			8	Totally bloodless	
			10 Right clawed little finger	Right clawed little finger	MPJ volar plate plication			5	Totally bloodless	
			11 Right second web space contracture	Right second web space contracture	Z-plasty			4	Totally bloodless	
4	61	Male	12 Right axillar linear contracture	Right axillar linear contracture	Multiple Z-plasty		GA	90	Minimal bleeding	360
			13 Right first web space linear contracture	Right first web space linear contracture	Multiple Z-plasty			10	Minimal bleeding	
			14 Right index extension contracture	Right index extension contracture	Z-plasty			19	Minimal bleeding	
			Right second and third web space contracture	Right second and third web space contracture	Web triangular flap and STSG	1 TF				
5	42	Female	15 Right little finger flexion contracture	Right little finger flexion contracture	Contracture release and FTSG			9	Minimal bleeding	270
			16 Right wrist extension contracture	Right wrist extension contracture	Scar excision and FTSG		GA	8	Minimal bleeding	
			17 Right chronic scar ulceration of first, second, and third MPJs	Right chronic scar ulceration of first, second, and third MPJs	Scar excision and FTSG			49.5	Minimal bleeding	
			Right second web space contracture	Right second web space contracture	Web triangular flap and multiple Z-plasty	1 TF				
			Right clawed little finger and fourth web space contracture	Right clawed little finger and fourth web space contracture	Dorsal multiple Z-plasty, web Z-plasty, volar scar excision, and intramedullary pining					
			18 Left thumb extension linear hypertrophic scar contracture	Left thumb extension linear hypertrophic scar contracture	Scar excision and multiple Z-plasty			8	Minimal bleeding	

(Continued to the next page)

Table 1. Continued

Patient no.	Age (yr)	Sex	Operative field	Diagnosis	Procedure	No. of flaps (excluding multiple-Z)	Type of anesthesia (GA/LA/a)	Volume of TS (mL)	Clarity of operative field	Length of surgery (min)
	19		Left ring finger linear contracture		Multiple Z-plasty			24	Minimal bleeding	
			Left clawed little finger		Multiple Z-plasty, and volar plate reconstruction using FDS graft					
			Left ulnar deviation wrist contracture		Scar excision and multiple Z-plasty					
6	23	Male	Left elbow flexion contracture		Skin contracture release, biceps tendon lengthening, and STSG		GA	60	Totally bloodless	210
	21 ^{a)}		Severe extension contracture of left finger		Skin contracture release second, third, and fourth volar plate tightening, fifth volar plate reconstruction using FDS graft			58	Totally bloodless	340
	22 ^{a)}		Extension contracture in left fingers		Scar contracture release and FTSG second and third MP volar plate reconstruction second web reconstruction with islanded ulnar digital flap from index	1 IUDF		75	Minimal bleeding	435
7	4 yr 8 mo	Male	Left palm contracture, thumb and little finger flexion contracture, first web space contracture		Scar contracture release and FTSG		GA	25	Minimal bleeding	95
8	3.5	Male	Left little finger flexion contracture		Scar contracture release and STSG		GA	2.5	Totally bloodless	180
	25		Hypothenar skin donor					2.3	Totally bloodless	
9	11	Male	Flexion contracture of all right fingers		Scar contracture release		GA	14.5	Totally bloodless	405
10	2 yr and 10 mo	Female	Right ring finger linear flexion contracture		Scar contracture release		GA	2	Acceptable bleeding	80
11	1 yr and 4 mo	Male	Flexion contracture of left palm, thumb, and all fingers		Scar contracture release		GA	12	Acceptable bleeding	150
12	4	Female	Webbing and severe flexion contracture in the left third, fourth, and fifth fingers		Scar contracture release, triangular web flaps, and FTSG	2 TF	GA	19	Totally bloodless	180

GA, general anesthesia; LA, local anesthesia; TS, tumescant solution; FTSG, full thickness skin graft; TF, triangular flap; PIPJ, proximal inter phalangeal joint; FDS, flexor digitorum superficialis; MP, metacarpophalangeal; MPJ, metacarpophalangeal joint; STSG, split thickness skin graft; IUDF, islanded ulnar digital flap.

^{a)}Operative fields 21 and 22 were actually in a single patient, who underwent surgeries at different times.

Table 2. Relationship of operative field clarity to scar thickness and density

Variable	Clarity of operative field		P-value
	Totally bloodless	Minimum & acceptable bleeding	
Scar thickness			<0.05
Thin	12	4	
Moderate & thick	2	11	
Scar density			<0.05
Pliable	12	2	
Moderate & high	2	13	

went necrosis.

The clarity of the operative field, scar thickness, and scar density were then adjusted by combining minimal and acceptable bleeding, moderate thickness scars with thick scars, and moderate density scars with high density scars. Table 2 describes the relationship of the clarity of the operative field to scar thickness and scar density.

Table 3 shows hand function before and after surgery. Data were only available from eight patients who presented 20 operative fields, whereas the data of the other four subjects with nine operative fields were not available. Among the 20 operative fields examined, the outcome of overall active function was excellent in five cases, good in one case, fair in one case, and poor in four cases. For abduction-hyperextension, there were eight outcomes with satisfactory function and one with mediocre function.

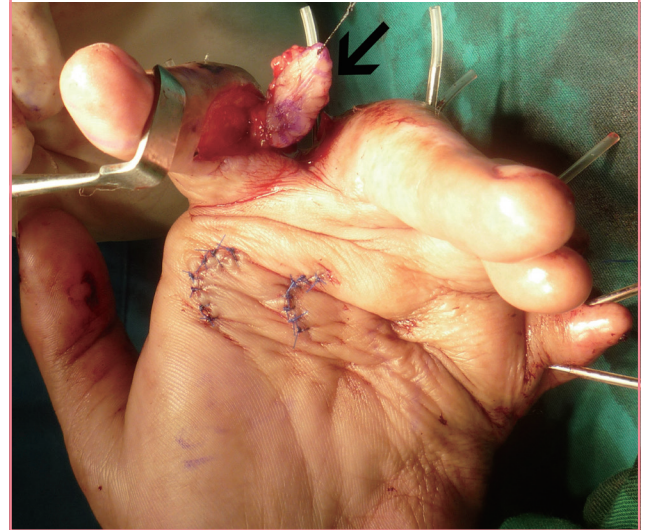DISCUSSION

To our knowledge, no published studies have yet focused specifically on the use of tumescent solution in burn hand contracture surgery, although there have been some sporadic reports of surgeries with a broad range of diagnoses that did not use a tourniquet [15,20]. These reports do not specifically discuss the characteristics of the burn scars and how they influence the effectiveness of the tumescent technique. We have reported that only three out of 29 (10.3%) burn contracture operative fields were totally bloodless, while the remaining cases involved minimal bleeding, except for one bloody operative field that was converted into a surgery with a tourniquet [15]. Interestingly, our current study shows different outcomes regarding the operative field clarity. Almost half of the cases in this study had totally bloodless operative fields and no case required the use of a tourniquet during surgery.

The duration of surgeries in this study was relatively long due to the complexity and severity of the cases. The longest surgery

Fig. 3. Islanded ulnar digital flap patency

A digital islanded flap (black arrow) was harvested from the ulnar side of the index finger to cover the second web space. The flap was performed in patient 6, operative field 22.



was 450 minutes long, whereas only two patients had procedures that took less than 120 minutes, which is the surgery duration that is the most commonly cited value for a safe tourniquet inflation period [21]. In a procedure lasting 450 minutes, it might be necessary to re-inflate the pneumatic tourniquet at least twice, which could potentially result in complications due to prolonged ischemia time. Thus, the one-per-million tumescent technique may help the surgeon to avoid lengthy and repeated tourniquet applications. Seven local and regional flaps were present in this study, and none showed any degree of necrosis. Even the islanded digital flap (Fig. 3), which rendered a perforator-based flap, successfully survived. This study therefore contributes more data on the safety of tumescent solution with regard to flap survivability.

It was found that out of the 14 totally bloodless operative fields, 12 cases involved thin burn scars with pliable density, while the remaining two cases were burn scars with moderate thickness and moderate density. Although burn scars in the minimal bleeding category were varied in their types of thickness and density categories, almost half of the operative fields had burn scars of moderate thickness and moderate density. All thick scars with high density produced acceptable bleeding, which provides the least clarity. Two conclusions can be drawn from these findings. First, a thin scar is approximately 11 times more likely to develop a bloodless operative field than scars of moderate thickness and thick scars (likelihood ratio = 11.011) are. This relationship between operative field clarity and scar thickness was found to be statistically significant. Second, the

Table 3. Hand functionality before and after surgery

No. of operative field	Diagnosis	Flexion and extension functionality before surgery	Outcomes	
			Flexion and extension functionality	Overall function/ Abduction-hyperextension
1	Left clawed little finger	Hyperextension of PIPJ	No hyperextension of PIPJ	Satisfactory
2	Left first web space contracture	Thumb abduction 45°	Thumb abduction 60°	Satisfactory
3	Right clawed little finger	Hyperextension of MPJ and flexion of PIPJ	Full flexion and extension of MPJ and PIPJ of right little finger	Excellent
4	Right second, third, and fourth web space contractures	Limited abduction of right fingers	Full abduction of right fingers	Excellent
5	Right clawed little finger	Hyperextension of MPJ and flexion of PIPJ	Right little finger PIPJ flexion 120°, no hyperextension of MPJ	Poor
	Right second, third, fourth web space contractures	Limited abduction of fingers	Full abduction of fingers	
6	Right radial linear thumb contracture	Limited thumb extension	Full thumb extension	Satisfactory
7	Left first web space contracture	Thumb abduction 40°	Thumb abduction 80°	Satisfactory
8	Left clawed little finger	Hyperextension of MPJ and flexion of PIPJ	No hyperextension and full flexion of MPJ in little finger, full flexion of PIPJ	Excellent
9	Linear contracture of left index finger	Limited finger extension	Extension of PIPJ 160°	Fair
10	Right clawed little finger	Hyperextension of MPJ	No hyperextension of MPJ	Satisfactory
11	Right second web space contracture	Limited abduction of fingers	Full second finger abduction	Excellent
12	Right axillar linear contracture	90° abduction and 90° extension of axilla	150° arm abduction and 180° extension	Good
13	Right first web space linear contracture	80° thumb abduction	90° thumb abduction	Satisfactory
14	Right index extension contracture	30° PIPJ flexion	90° PIPJ flexion	Poor
	Right second and third web space contracture	Limited abduction of fingers	30° abduction of fingers	Poor
15	Right little finger flexion contracture	30° PIPJ extension	120° PIPJ extension	Poor
16	Right wrist extension contracture	45° wrist flexion	Not available	Not available
17	Right chronic scar ulceration of first, second, and third MPJs	60° flexion of MPJs with chronic scarring	Not available	Not available
	Right second web space contracture	Limited abduction of fingers	Not available	Not available
	Right clawed little finger and fourth web space contracture	Hyperextension of MPJ and flexion of PIPJ	Not available	Not available
18	Left thumb extension linear hypertrophic scar contracture	Limited thumb flexion	Not available	Not available
19	Left ring finger linear contracture	Limited finger extension	Not available	Not available
	Left clawed little finger	Hyperextension of MPJ and flexion of PIPJ	Not available	Not available
	Left ulnar deviation wrist contracture	Limited wrist radial deviation	Not available	Not available
20	Left elbow flexion contracture	80° elbow extension	175° elbow extension	Excellent
21	Severe extension contracture ^{a)} of left fingers	90°–130° hyperextension in second to fifth MPJ	45°–60° hyperextension in second to fifth MPJ	Mediocre
22	Extension contracture ^{a)} in left fingers	45°–60° hyperextension in second to fifth MPJ	Not available	Not available
23	Left palm contracture, thumb and little finger flexion contracture, and first web space contracture	Limited extension of second, third, and fourth MPJ; IPJs extension of thumb and little finger; and thumb abduction	Full extension of all fingers and 80° thumb abduction	Satisfactory
24	Left little finger flexion contracture	Limited extension (90° PIPJ extension, ulnar rotation)	Not available	Not available
25	Hypothenar skin donor	Skin harvest (skin area with burn scar)	Not available	Not available
26	Flexion contracture of all right fingers	Limited extension of all fingers	Not available	Not available
27	Right ring finger linear flexion contracture	Limited extension	Not available	Not available
28	Flexion contracture of left palm, thumb, and all fingers	Limited palm opening, 80° thumb abduction, 80° second and fourth MPJ extension, 85° third and fifth MPJ extension	Limited palm opening, 85° thumb abduction, full extension of second to fifth MPJ	Satisfactory
29	Webbing and severe flexion contracture in the left third, fourth, and fifth fingers	Severe flexion and adduction	Full extension of left third finger, full passive extension of fourth finger, severe flexion of fifth finger, and full abduction of fingers	Poor (on the fifth finger)

PIPJ, proximal inter phalangeal joint; MPJ, metacarpophalangeal joint; IPJ, inter phalangeal joint.

^{a)}Operative fields 21 and 22 were actually in a single patient, who underwent surgeries at different times.

probability of pliable scars developing a bloodless operative field is 17 times higher than that of moderate and high-density scars (likelihood ratio = 16.905) are. This was also found to be statistically significant.

Out of the 20 operative fields for which follow-up was possible, 15 had adequate function of flexion and extension, one (operative field 21) was categorized as mediocre, and four (operative fields 5, 14, 15, and 29) were considered poor. Two out of the four poor outcomes (operative fields 14 and 15) and one mediocre outcome actually reflected an improvement in the patient's condition, with range of motion improvement ranging from 45 to 90 degrees. Despite the full correction of hyperextension of the metatarsophalangeal joint, the outcome of operative field 5 was still considered poor because the range of motion of the proximal interphalangeal joint did not improve. The last operative field with a poor outcome (operative field 29) preoperatively presented with a severe flexion and an adduction contracture in the third to fifth fingers. Even though full abduction and extension of the third and fourth fingers were achieved, the fifth finger could not be corrected due to diminished distal vascularization that occurred while it was being straightened. Therefore, this outcome was categorized as poor. However, the problem involving vascularization was likely not related to the use of the tumescent technique, as the finger returned to its normal vascularization after the removal of the K-wire. It seems that the cause was merely physical intolerance in the vessels due to mechanical straightening.

In summary, the one-per-million tumescent technique effectively creates a relatively clear operative field without the use of a tourniquet in surgeries for post-burn hand deformities, especially in meticulous, multiple, and lengthy procedures. Although scar thickness and density affect its implementation, this technique can be considered safe and effective in creating a clear operative field. Nevertheless, this study has several drawbacks. First, it was conducted without a control group; hence, the effectiveness of the tumescent technique could not be directly compared to the pneumatic tourniquet. Second, burn scar thickness was measured intraoperatively through the surgical wound. This means that the swelling effect of the injection was also included in the thickness measurement. The last drawback is that the clarity of the operative field and the density of the burn scar were assessed subjectively.

REFERENCES

1. Karia RA. Hemostasis and tourniquet. *Oper Tech Sports Med* 2011;19:224-30.
2. Flatt AE. Tourniquet time in hand surgery. *Arch Surg* 1972; 104:190-2.
3. Robertson RD, Bond P, Wallace B, et al. The tumescent technique to significantly reduce blood loss during burn surgery. *Burns* 2001;27:835-8.
4. Cartotto R, Musgrave MA, Beveridge M, et al. Minimizing blood loss in burn surgery. *J Trauma* 2000;49:1034-9.
5. van der Veer WM, Bloemen MC, Ulrich MM, et al. Potential cellular and molecular causes of hypertrophic scar formation. *Burns* 2009;35:15-29.
6. Oragui E, Parsons A, White T, et al. Tourniquet use in upper limb surgery. *Hand (N Y)* 2011;6:165-73.
7. Avci G, Akan M, Yildirim S, et al. Digital neurovascular compression due to a forgotten tourniquet. *Hand Surg* 2003;8: 133-6.
8. Odinson A, Finsen V. Tourniquet use and its complications in Norway. *J Bone Joint Surg Br* 2006;88:1090-2.
9. Denkler K. A comprehensive review of epinephrine in the finger: to do or not to do. *Plast Reconstr Surg* 2001;108: 114-24.
10. Wilhelmi BJ, Blackwell SJ, Miller JH, et al. Do not use epinephrine in digital blocks: myth or truth? *Plast Reconstr Surg* 2001;107:393-7.
11. Denkler K. Dupuytren's fasciectomy in 60 consecutive digits using lidocaine with epinephrine and no tourniquet. *Plast Reconstr Surg* 2005;115:802-10.
12. Chowdhry S, Seidenstricker L, Cooney DS, et al. Do not use epinephrine in digital blocks: myth or truth? Part II. A retrospective review of 1111 cases. *Plast Reconstr Surg* 2010; 126:2031-4.
13. Thomson CJ, Lalonde DH, Denkler KA, et al. A critical look at the evidence for and against elective epinephrine use in the finger. *Plast Reconstr Surg* 2007;119:260-6.
14. Lalonde DH, Lalonde JF. Discussion. Do not use epinephrine in digital blocks: myth or truth? Part II. A retrospective review of 1111 cases. *Plast Reconstr Surg* 2010;126:2035-6.
15. Prasetyono TO, Biben JA. One-per-mil tumescent technique for upper extremity surgeries: broadening the indication. *J Hand Surg Am* 2014;39:3-12.e7.
16. Prasetyono TH, Saputra DA, Astriana W. One-per-mil tumescent technique for bone and joint surgery in hand. *HAND* 2014;1-5.
17. Sullivan T, Smith J, Kermode J, et al. Rating the burn scar. *J Burn Care Rehabil* 1990;11:256-60.
18. Schwanholt C, Greenhalgh DG, Warden GD. A comparison of full-thickness versus split-thickness autografts for the coverage of deep palm burns in the very young pediatric patient. *J Burn Care Rehabil* 1993;14:29-33.
19. Schwarz RJ. Management of postburn contractures of the

- upper extremity. *J Burn Care Res* 2007;28:212-9.
20. Prasetyono TO. Tourniquet-free hand surgery using the one-per-mil tumescent technique. *Arch Plast Surg* 2013;40:129-33.
21. Cox C, Yao J. Tourniquet usage in upper extremity surgery. *J Hand Surg Am* 2010;35:1360-1.

Supplemental Table S1. Summary of categories definition

Supplemental data can be found at: <http://e-aps.org/src/sm/aps-42-164-s001.pdf>

Supplemental Table S2. Operative field distribution based on the thickness and density of scar

Supplemental data can be found at: <http://e-aps.org/src/sm/aps-42-164-s002.pdf>

Supplemental Video S1. One-per-mil tumescent technique in hand burn surgery.

Supplemental data can be found at: <http://e-aps.org/src/sm/aps-42-164-s003.mp4>

Supplemental Table S1. Summary of categories definition

Supplemental Table S1. Summary of categories definition			
Categories	Sub-categories	Definition	
Clarity of operative field	Totally bloodless	A bloodless operative field equal to that achieved by pneumatic tourniquet use	
	Minimal bleeding	Slight bleeding that does not affect the clarity of the operative field and the recognition of the anatomical structures	
	Acceptable bleeding	Bleeding that needs more gauze sweeping in order to keep the anatomical structure recognizable without rendering difficulties to the surgeon performing the procedures	
	Bloody	Bleeding that disturbs the recognition of anatomical structures and needs additional use of pneumatic tourniquet	
Scar thickness	Thin	Scar which thickness is less than 2 mm	
	Moderate	Scar which has a thickness of 2–5 mm	
	Thick	Scar which thickness is more than 5 mm	
Scar density	Pliable	Scar that yields with minimal resistance	
	Moderate	A yielding scar with moderate resistance but does not form a solid mass	
	High	A firm scar that moves as a solid inflexible unit	
Functional outcome	Overall function (finger extension, elbow extension, and axilla abduction)	Excellent	Full extension (0 degree) of all fingers, full to 170 degrees of elbow extension, and full to 170 degrees of axilla abduction
		Good	Finger flexion of 5 degrees at active extension, evidence of webbing, 130 to 170 degrees of elbow extension, and 130 to 170 degrees of axilla abduction.
		Fair	Finger flexion from 5 to 30 degrees at active extension, 90 to 130 degrees of elbow extension, and 90 to 130 degrees of axilla abduction
		Poor	Finger flexion over 30 degrees, less than 90 degrees of elbow extensions, and less than 90 degrees of axilla abduction
	Abduction-hyperextension (thumb abduction and finger hyperextension)	Nice	Thumb abduction > 50 degrees and/ or no finger hyperextension
		Mediocre	Thumb abduction < 50 degrees and/ or any degree of finger hyperextension

