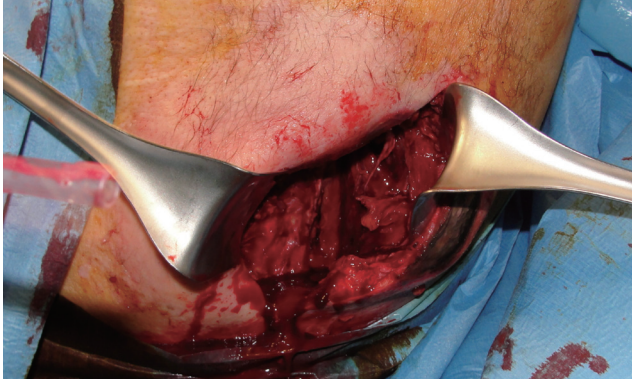



**Fig. 3.** Intraoperative view: drainage and surgical debridement have been performed.

plus intravenous corticoid administration within the first 36 hours may be sufficient to achieve healing, while surgical debridement is required in the case of late diagnosis. On the other hand, it may become complicated with infection and life-threatening conditions such as necrotizing fasciitis, myositis or sepsis, limb gangrene, paraplegia, or death [4]. Moreover, the area of poorly vascularized tissue often extends beyond the visible area of necrosis and, as a consequence, the undiagnosed and consequently untreated damaged tissue may be prone to bacterial colonization and very poor wound healing. In our case, the livedoid dermatitis of the right buttock was complicated with an extensive abscess and necrotizing fasciitis. The latter is an uncommon and rapidly spreading infection involving the superficial fascial plane and subcutaneous tissue with a high risk of systemic toxicity and complications like adult-respiratory distress syndrome, acute renal failure, cardiac failure, or even multi-organ failure. Risks factors include immunosuppression, diabetes, age older than 50 years, malnutrition, and peripheral vascular disease [5]. The mortality rate is around 34%, and it is classified into two types: type 1, which accounts for about two thirds of the cases, is polymicrobial and mainly occurs in association with significant co-morbidities, while type 2 is caused by group A *Streptococcus* mainly in patients with a history of trauma, intravenous drug abuse, or surgery [4]. These classification criteria were not applicable to our patient's condition, as microbiological investigation proved a *Staphylococcus aureus* mono-microbial infection. Furthermore, our patient was afebrile, while fever and chills are among the most common beginning symptoms of necrotizing fasciitis. In conclusion, embolia cutis medicamentosa is a very rare pathology whose risk factors remain to be completely elucidated. In most of cases, it presents with only local symptoms but, especially in the presence of comorbidities such as an immunocompromised state, complications are likely to arise and lead to the patient's death. Our case remarkably highlights the potentially serious consequences of Nicolau's syndrome. Plastic and dermatologic surgeons must be well aware that prevention, timing of diagnosis, and treatment are crucial for the patient's prognosis.

## References

1. Kim SK, Kim TH, Lee KC. Nicolau syndrome after intramuscular injection: 3 cases. *Arch Plast Surg* 2012;39:249-52.
2. Marangi GF, Gigliofiorito P, Toto V, et al. Three cases of embolia cutis medicamentosa (Nicolau's syndrome). *J Dermatol* 2010;37:488-92.
3. Beissert S, Presser D, Rutter A, et al. Embolia cutis medicamentosa (Nicolau syndrome) after intra-articular injection. *Hautarzt* 1999;50:214-6.
4. Sarani B, Strong M, Pascual J, et al. Necrotizing fasciitis: current concepts and review of the literature. *J Am Coll Surg* 2009;208:279-88.
5. Smith SR, Aljarabah M, Ferguson G, et al. Necrotizing fasciitis following saphenofemoral junction ligation with long saphenous vein stripping: a case report. *J Med Case Rep* 2010;4:161.

## Aesthetic Refinement of the Dog Ear Correction: The 90° Incision Technique and Review of the Literature

Luca Grasseti<sup>1</sup>, Davide Lazzeri<sup>2</sup>, Matteo Torresetti<sup>1</sup>, Manuela Bottoni<sup>1</sup>, Alessandro Scalise<sup>1</sup>, Giovanni Di Benedetto<sup>1</sup>

<sup>1</sup>Department of Plastic and Reconstructive Surgery, Marche Polytechnic University Medical School, Regional Hospital, Ancona; <sup>2</sup>Plastic and Reconstructive Surgery Unit, Hospital of Pisa, Pisa, Italy

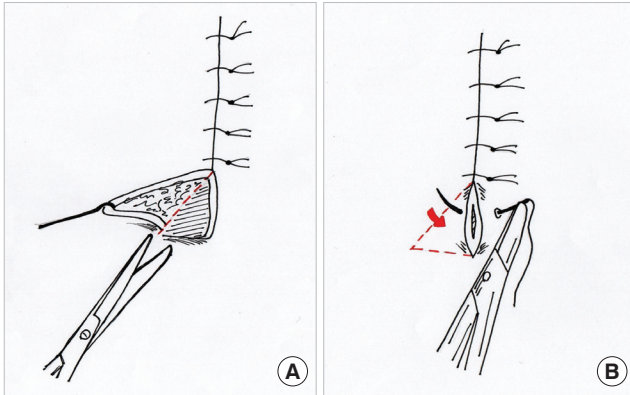
**Correspondence:** Luca Grasseti  
Department of Plastic and Reconstructive Surgery, Marche Polytechnic University, Via Conca, 71-60020 Ancona, Italy  
Tel: +39-071-596-5226, Fax: +39-071-596-3453, E-mail: luca.grasseti2000@gmail.com

No potential conflict of interest relevant to this article was reported.

Received: 29 Jan 2013 • Revised: 19 Mar 2013 • Accepted: 20 Mar 2013  
pISSN: 2234-6163 • eISSN: 2234-6171  
<http://dx.doi.org/10.5999/aps.2013.40.3.268> • Arch Plast Surg 2013;40:268-269

Copyright © 2013 The Korean Society of Plastic and Reconstructive Surgeons  
This is an Open Access article distributed under the terms of the Creative Commons Attribution Non-Commercial License (<http://creativecommons.org/licenses/by-nc/3.0/>) which permits unrestricted non-commercial use, distribution, and reproduction in any medium, provided the original work is properly cited.

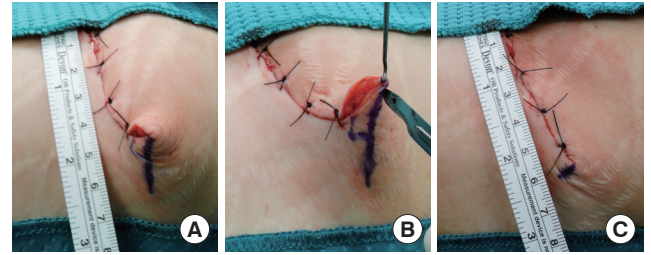
The closure of any circular or asymmetric wound results in puckering or excess of tissue known as dog ears. Tissue dynamics, wound geometry, surface contour, and surgical technique affect dog ear formation [1,2]. Despite good preoperative planning for skin management techniques including Burrow's triangle, V-Y advancement flap, M-plasty [3], and S-plasty [4], and despite following intraoperative procedures including proper undermining of a shallow wound, proper 90° angle of the scalpel blade, precise suture placement, and removal of excess underlying fat, sometimes a dog ear occurs anyhow. Meth-

**Fig. 1.**

The schema of our new technique for correcting a dog ear at the end of a wound. (A) Incision at a 90° angle to the long axis of the existing excision line to create a triangular advancement skin flap downward. As much of the triangular raised flap is removed as the correction requires. (B) The 90° incision created disappears as soon as the skin has been sutured. The steep protrusion of the dog ear disappears without either lengthening the wound or creating new scars. The red arrow shows the direction of the flap advancement used for dog ear removal.

ods for correcting dog ears include excision of the excess tissue in the shape of a triangle, crescent or ellipse; excision of conical folds of tissue at the end of the wound in the same direction as the long axis of the original wound; and excision of the dog ear at a 120° angle to the long axis of the existing excision line in a shape resembling a hockey stick [5]. They are extensively described in the literature, but they all lead to wound extension. Only M-plasty allows for reduction in the scar's length but produces a double-tailed scar, so if the total length with the two tails is considered, the new scar is still longer than the original one. We have developed a new and easy technique for dog ear correction without extending the length of the original wound.

To remove a dog ear, the wound should be sutured until the elevation becomes pronounced. A hook placed in the end of the wound defines the extent of the dog ear. The elevation is then excised by creating a 90° incision at the end of the wound where the dog ear appears. In this way, a small triangular advancement flap can be raised

**Fig. 2.**

Sequenced images of the 90° incision technique. (A) With an ink pen, a line is drawn at 90° along the base on one side of the standing full cone dog ear. (B) The apex of the dog ear is elevated with a skin hook. The line will be then incised, thus creating a triangular flap ready for removal. (C) After the triangular skin flap has been removed, the dog ear disappears without lengthening the wound.

upward or downward according to the skin region desired to be removed. This flap is brought across the wound so that the skin excess can be cut straightforwardly. A portion of the flap is then removed to the extent required and the 90° incision created will disappear as well (Figs. 1, 2).

The 90° incision technique enables correction of a dog ear without either lengthening the wound or creating new scars, thus improving the aesthetic outcome of the procedure.

## References

1. Weisberg NK, Nehal KS, Zide BM. Dog-ears: a review. *Dermatol Surg* 2000;26:363-70.
2. Dzubow LM. The dynamics of dog-ear formation and correction. *J Dermatol Surg Oncol* 1985;11:722-8.
3. Webster RC, Davidson TM, Smith RC, et al. M-plasty techniques. *J Dermatol Surg* 1976;2:393-6.
4. Zitelli JA. Tips for wound closure. Pearls for minimizing dog-ears and applications of periosteal sutures. *Dermatol Clin* 1989;7:123-8.
5. Toomey JM. "Practical suggestions on facial plastic surgery: how i do it"; subcutaneous pedicle flap reconstruction of lower nasal defects. *Laryngoscope* 1977;87:443-5.