

Indications, Outcomes, and Complications of Pedicled Propeller Perforator Flaps for Upper Body Defects: A Systematic Review

Davide Lazzeri¹, Georg M. Huemer², Fabio Nicoli³, Lorenz Larcher², Talal Dashti⁴, Luca Grassetti⁵, Qingfeng Li⁶, Yixin Zhang⁶, Giuseppe Spinelli⁷, Tommaso Agostini⁷

¹Plastic and Reconstructive Surgery Unit, Hospital of Pisa, Pisa, Italy; ²Section of Plastic, Aesthetic and Reconstructive Surgery, General Hospital Linz, Linz, Austria; ³Department of Plastic and Reconstructive Surgery, University of Tor Vergata, Rome, Italy; ⁴Al-Babtain Hospital for Burn and Plastic Surgery, Kuwait City, Kuwait; ⁵Department of Plastic and Reconstructive Surgery, Marche Polytechnic University Medical School, University Hospital, Ancona, Italy; ⁶Shanghai Ninth People's Hospital, Shanghai Jiao Tong University School of Medicine, Shanghai, China; ⁷Maxillofacial Surgery Unit, Hospital of Florence, Florence, Italy

Background The aim of this investigation was to systematically review the current literature to provide the best data for indications, outcomes, survival, and complication rates of pedicled propeller perforator flaps for upper body defects.

Methods A comprehensive literature review for articles published from January 1991 to December 2011 was performed using the PubMed, Medline, and Cochrane Databases. Articles without available full-text, single case reports or papers with excessive missing data were excluded. Papers reporting pedicle-perforator (propeller) flaps used for lower extremity reconstruction were excluded from meta-analysis.

Results From the initial 1,736 studies our search yielded, 343 studies qualified for the second stage of selection. Of 117 full-text reports screened, 41 studies, met the definitive inclusion and exclusion criteria. Of the selected 41 articles, 26 were case series, original papers or retrospective reviews and were included, whereas 15 were case report papers and therefore were excluded. Two hundred ninety-five propeller flaps were reported to have been used in a total of 283 patients. Indications include repair of trauma-induced injuries, post-trauma revision surgery, cancer resection, chronic infection, pressure sores, and chronic ulcers with a major complication rate (3.3%) comparable to that of free flaps. No specific exclusion criteria for the procedure were presented in the studies reviewed.

Conclusions Pedicled propeller flaps are a versatile and safe reconstructive option that are easy and quick to raise and that provide unlimited clinical solutions because of the theoretical possibility of harvesting them based on any perforator chosen among those classified in the body.

Keywords Pedicled flap / Review literature / Surgical flaps

Correspondence: Yixin Zhang
Department of Plastic and Reconstructive Surgery, Shanghai Ninth People's Hospital, Shanghai Jiao Tong University School of Medicine, 639 Zhi Zao Ju Road, Shanghai 200011, China
Tel: +86-21-23271699
Fax: +86-21-63051858
E-mail: zhangyixin6688@hotmail.com

No potential conflict of interest relevant to this article was reported.

Received: 6 Aug 2012 • Revised: 12 Dec 2012 • Accepted: 18 Dec 2012
pISSN: 2234-6163 • eISSN: 2234-6171 • <http://dx.doi.org/10.5999/aps.2013.40.1.44> • Arch Plast Surg 2013;40:44-50

INTRODUCTION

The propellar flap was introduced with a published series on

random subcutaneous pedicle flaps that were elevated and rotated approximately 90 degrees to release scar contractures in the cubital and axillary regions. The knowledge of vessel perforator

anatomy, angiosomes, and perforasomes led to the evolution of pedicled perforator flaps, which have simplified the reconstructive options for surgeons in almost every area of the body. After the publication of this pioneering paper, more recent publications have documented the wide clinical application of this technique.

Since pedicled propeller perforator flaps for lower extremity reconstruction have been already analyzed the primary aim of this systematic review was to identify indications, outcomes and survival and complication rates for the use of pedicle propeller perforator flaps in reconstructions of the head and neck, trunk and upper extremities.

METHODS

Search

A broad search of the PubMed, Medline, and Cochrane databases was conducted in December of 2011 using the term “perforator flap”, and 1,736 original studies published between 1991 and 2011 were identified (Fig. 1). Articles without available full-text, single case reports or papers with excessive missing data were excluded. Papers reporting pedicle-perforator (propeller) flaps used for lower extremity reconstruction were excluded from meta-analysis.

After the first step of the selection process, the retrieved arti-

cles were fully analyzed. Articles reporting a case series in which pedicled propeller perforator flaps were used in human patients for head and neck, trunk and upper extremity reconstruction were included in the final step of the review. If details of the procedure were unclear, the article was excluded. Review papers on this topic that did not present any new cases were excluded.

RESULTS

Of the initial 1,736 studies yielded from our search (Fig. 1), 343 studies qualified for the second stage of selection, and, after the screening of 117 full-text papers, 41 studies met the definitive inclusion criteria. Of the selected 41 articles, 25 were case series, original papers or retrospective reviews [1-25] and were included, whereas 15 were case report papers and therefore were excluded. Among the reports that were included, two hundred eighty-eight propeller flaps have been reported to have been used in a total of 276 patients. The results of the present review are summarized in Table 1.

Head and neck

A review of the literature revealed a total of 4 articles on the head and neck representing 44 propeller flaps in as many patients [1-4]. The patients had undergone surgery secondary to tumor [4], hidradenitis suppurativa [3] or trauma-induced soft-tissue

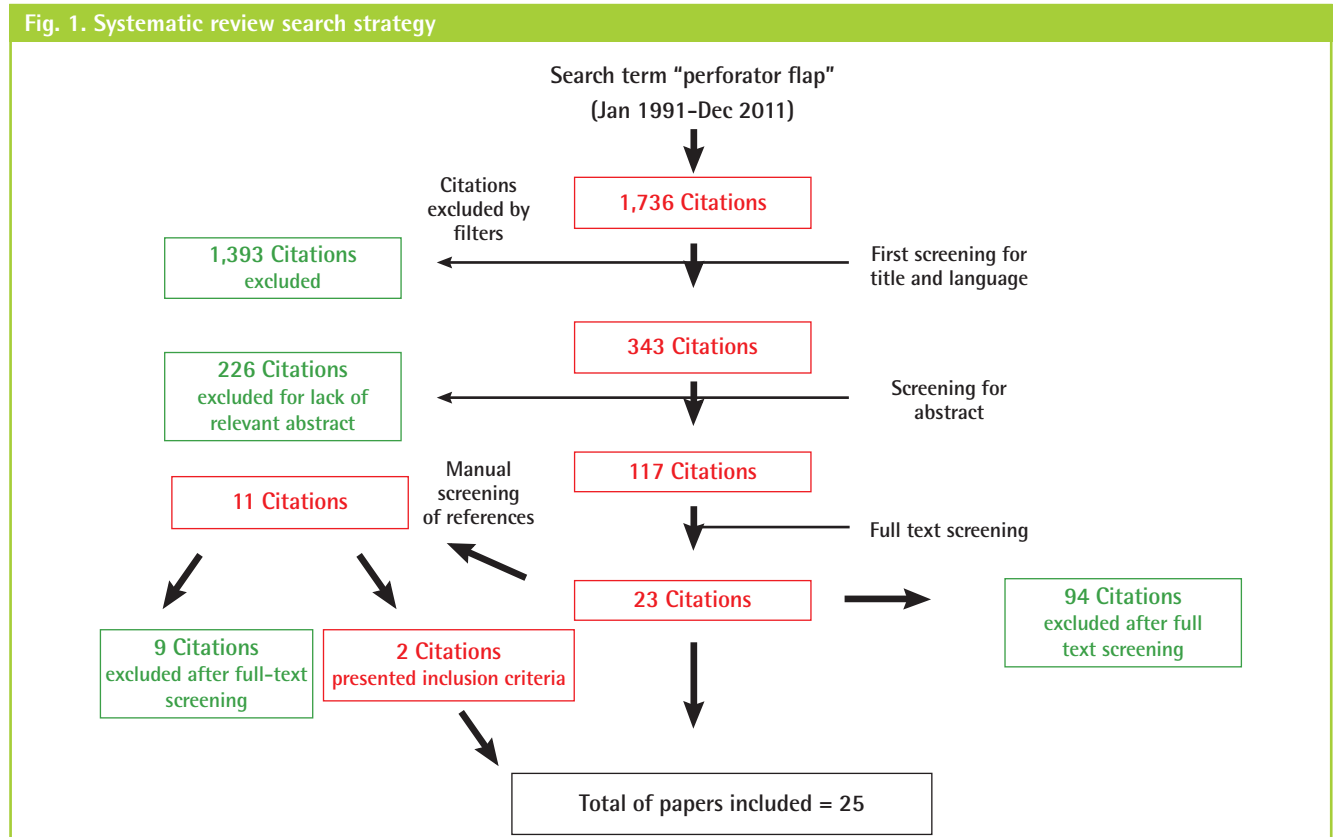


Table 1. Summary of the most common^{a)} pedicled propeller perforator flaps for upper body defects

	Source artery	No. of case	Age (yr, average)	Defect region	Diagnosis: etiology of loss of substance	Flap size (cm, average)	Flap design (shape)	Donor site management	Preoperative exam
Head & neck	LNA [1]	6	63.8	Ala nasi	BCC	1.8×2	Freestyle	Primary closure	Doppler
	FA [2,3]	19	NA	Nose, upper lip, cheek, lower lip, naso-labial fold	BCC, hidradenitis suppurativa, melanoma, oral cancer	2.4×1.6	Freestyle	Primary closure	Doppler
	STA [3]	11	NA	Nose	BCC, breast cancer	7×3.8	Freestyle	Primary closure	Doppler
	PAA [3,4]	5	NA	Helical root, retroauricular, neck	Cancer, dermatofibrosarcoma protuberans, fibroadenoma	8.7×3.7	Elliptical, free style	Primary closure	Doppler
Upper limb	RA [2,3,6]	45	NA	Upper extremity, distal upper extremity, dorsal hand, wrist	Trauma, post-burn contracture, electrical burn, tumor, bullet, SCC	NA	Freestyle, elliptical, bilobed	Primary closure, skin grafting	Doppler
	UA [17,19,24]	8	NA	Hand, volar forearm	Radial forearm flap donor site, trauma, deep abrasion, degloving, open fracture+degloving, SCC	10×4.2	Freestyle, elliptical	Primary closure, skin grafting	Doppler
Trunk and perineal	TDA [2,3,17]	9	NA	Lateral thoracic wall, breast, scapula, axilla	Pleural TBC, empyema, thoracic window, port-A-Cath exposure, SCC	16.3×9.5	Freestyle	Primary closure	Doppler
	IMA [2,8]	14	44.6 (range, 15-71)	Neck, sternal, breast, clavicular, chest	Anterior chest keloid, BCC, sarcoma, cancer metastases, thermal burn, postmediastinitis	15.4×6.8	Freestyle, oval, bilobed	Primary closure	Doppler, MDCTA
	ICA [4,5,17]	9	NA	Breast, lower back	Lack of volume, scarring, oral cancer, port-A-Cath exposure, SCC	19.3×7	Freestyle	Primary closure	Doppler
	LA [2,17]	10	63.5 (range, 18-69)	Back	Sarcoma, pressure sore, SCC, donor site closure of DSA flap	20.8×9.7	Freestyle	Primary closure	Doppler
	SGA [2,3,7-13,18,19]	52	56.4 (range, 21-83)	Sacral, vaginal, gluteal, trochanteric	Pressure sore, rectal adenocarcinoma, radiation ulcer, hidradenitis suppurativa, pilonidal cysts, scar contracture, intergluteal crease	16.6×10.4	Multi-island flap, stellate, rectangular, freestyle, elliptical	Primary closure	Doppler, MDCTA
	IGA [2,10-13,19]	13	49.6 (range, 29-83)	Ischiatic, gluteal, thigh, vaginal, perineal	Soft tissue defect, sarcoma, anal carcinoma, enterocutaneous fistula, pressure sore, hidradenitis suppurativa, rectal adenocarcinoma	15.3×6.9	Rectangular, elliptical, freestyle	Primary closure	Doppler, MDCTA
	Unspecified gluteal [14,15]	18	54.8	Lower back, sacrum, ischium, scapula	Pressure sores, spine surgery, SCC, melanoma, sebaceous carcinoma	7.5×9	Elliptical, freestyle	Primary closure	Doppler

LNA, lateral nasal artery; BCC, basal cell carcinoma; FA, facial artery; NA, not available; STA, supratrochlear artery; PAA, posterior auricular artery; RA, radial artery; SCC, squamous cell carcinoma; UA, ulnar artery; TDA, thoraco-dorsal artery; TBC, tuberculosis; IMA, internal mammary artery; MDCTA, multirow detector computed tomographic angiography; ICA, intercostal artery; LA, lumbar artery; DSA, dorsal scapular artery; SEA, superior epigastric artery; SGA, superior gluteal artery; IGA, inferior gluteal artery.

^{a)}Most common refers to at least 5 cases of the type of flap appearing in the literature included in this meta-analysis.

defects, which affected the following various anatomical sites: the ala [1] and dorsum of the nose [2], naso-labial folds [2], upper and lower lips [3], cheek [3], ear [4], and neck [3]. A total of 19 local propeller flaps within an area adjacent to the defect were harvested from the facial artery perforators [2,3]. In 11 cases [3], the supratrochlear perforator was used as the feeder vessel, and in 6 cases [3], the lateral nasal artery perforators were used as feeder vessels. The posterior auricular artery was the source vessel for 5 flaps [3,4], whereas only 3 cases of transverse cervical artery pedicled propeller flap were described [2,3]. Preoperative Doppler mapping of the perforator vessels was performed in all

cases using a handheld device [1-4]. All flaps were dissected in the superfascial/supra-superficial musculoaponeurotic system (SMAS) plane until reaching the vicinity of the marked perforator. The donor site was closed primarily in all patients. Complete flap survival was obtained in all flaps, although 6 patients had minor complications (Table 2). Three cases among the lateral nasal artery propeller series suffered venous congestion that resolved spontaneously [1]. D'Arpa et al. [3] successfully managed a case of arterial insufficiency (supratrochlear artery propeller) using derotation and delayed rerotation of the flap. These authors also managed a case of partial necrosis from venous congestion (fa-

Table 2. Pedicled propeller perforator flaps for upper body defects. Analysis of complications

Complication	Minor complication			Major complication				
	Complication	Risk factor	Source artery	Management and outcome	Complication	Risk factor	Source artery	Management and outcome
Head & neck	3 Cases of venous congestion [1]	NA	LNA	Spontaneous resolution				
	Partial necrosis for venous congestion [3]	NA	FA	Secondary healing				
	Arterial insufficiency [3]	NA	STA	Salvage by derotation and delayed rerotation				
	<i>Total of 5 minor complications/44 flaps → 11.3% overall complication rate</i>							
Trunk and perineum	Hematoma [2]	NA	IMA	NA	Total flap loss due to vasopressor for cardiac failure [2]	DM, CRF, dialysis, morbid obesity	IMA	NA
	Distal hip flap necrosis [2]	NA	LA	Conservative management	Wound dehiscence [11]	None	IGA	Local rotation flap
	Infection, dehiscence [2]	DM, AH, CAD, stents, prior RT	IGA	Secondary healing	Total flap loss [11]	None	PSA	NA
	Minimal drainage [9]	NA	SGA	Secondary healing	2 Cases of flap necrosis [14]	NA	IGA/SGA	2 Cases of local advancement flap
	Minor wound dehiscence at the donor site [10]	DM	SGA	Revision surgery				
	Hematoma [10]	None	SGA	Secondary healing	Partial flap loss [19]	Prior RT	SGA	Contralateral SGA perforator flap
	3 Cases of wound dehiscence [18]	DM, MI, CRF, AD, PD, quadriplegia	SGA	2 Cases of local revision surgery (resuturing),				
	3 Cases of wound dehiscence [19]	Prior RT	SGA	1 Case of skin grafting				
	4 Cases of minor wound dehiscence [13]	NA	Gluteal	3 Cases of local revision surgery (resuturing)				
	Hematoma [14]	NA	Gluteal	3 Cases of resuturing, 1 case of dressings				
	Wound dehiscence [14]	NA	Gluteal	Evacuation				
	Partial flap loss [15]	NA	Gluteal	Debridement followed by secondary healing				
	Hematoma [15]	NA	Gluteal	Delayed wound closure				
	Venous congestion [15]	NA	Gluteal	Evacuation				
	Wound dehiscence [19]	Prior RT	IGA	Spontaneous resolution				
				Local revision surgery (resuturing)				
				<i>Total of 22 minor complications/145 flaps → 15.1% rate</i>				
				<i>Total of 28 complications/145 flaps → 19.3% overall complication rate</i>				
Upper limb	Venous congestion [23]	NA	SubP	Spontaneous resolution	Venous congestion leading to necrosis [3]	NA	RA	Failed venous supercharging salvage, 90% Necrosis. Skin graft 28th day
	Partial graft loss [23]	NA	SubP	Conservative management	20% distal flap necrosis due to venous congestion [3]	NA	RA	Abdominal flap for coverage of the residual defect
					Venous congestion [3]	NA	UA	Salvage with venous supercharging
					Necrosis of 40% of flap [25]	None	SUCA	Debridement and skin grafting
				<i>Total of 3 minor complications/99 flaps → 3% rate</i>				
				<i>7 Total complications/99 flaps → 7% overall complication rate</i>				
				<i>Total of 30 minor complications/288 flaps → 10.4% rate</i>				
				<i>Total of 40 complications/288 flaps → 13.8% overall complication rate</i>				
					<i>Total of 6 major complications/144 flaps → 4.1% rate</i>			

NA, not available; LNA, lateral nasal artery; FA, facial artery; STA, suprathroclear artery; IMA, internal mammary artery; LA, lumbar artery; DM, diabetes mellitus; CRF, chronic renal failure; AH, arterial hypertension; CAD, coronary artery disease; IGA, inferior gluteal artery; RT, radiation therapy; SGA, superior gluteal artery; PSA, parasacral artery; AD, Alzheimer's disease; PD, Parkinson's disease; SubP, subcutaneous pedicle; DIMA, dorsal intermetacarpal artery; RA, radial artery; UA, ulnar artery; SUCA, superior ulnar collateral artery.

cial artery propeller) employing secondary healing.

Trunk and perineal region

Fifteen articles reporting 145 pedicled propeller flaps in the trunk and perineal region performed in 141 patients were included in this study [2,3,5-17]. Double flaps were used in 4 patients [2,8,19]. The etiologies of the defects included pressure sores [2,3,6,9-11,14,17,18], post-burn sequelae [5,7,8], trauma [6], tumor resection [2,3,8,9,13,15-17], and for sacral radiation ulcer and osteoradionecrosis [19] in almost all patients. Propeller flaps were seldom used for closure of a surgical donor [2], for spine surgery [15] and coverage of Port-A-Cath device exposure [3] and for defects following keloid removal [2], pilonidal cysts [7,8,11] and hidradenitis suppurativa [12].

The gluteal artery perforator propeller flap was the most frequently performed flap [2,3,6-15,18,19], followed by flaps that used the internal mammary [2,8], lumbar [2,17], intercostal arteries [2,3,17] or lateral circumflex femoral artery [18], as the blood supply.

The donor area was primarily closed in all cases. Overall, the flap survival rate was 80.7%, and only 28 patients experienced complications. Four hematomas were drained postoperatively [2,10,14,15]. Wound dehiscence was managed conservatively in 14 cases [2,9,10,13,18,19], and 2 patients required revision with either debridement and skin grafting [14] or local rotation flaps [11]. Distal tip [2] and partial flap necrosis [15,19] occurred in 3 cases and healed uneventfully in 2 patients; in one case a contralateral superior gluteal artery perforator flap was necessary [19]. Four flaps were lost and, in 2 of the cases [14], replaced with local advancement flaps. No information was available regarding the other 2 cases [10]. Among the patients with minor complications, 2 were diabetic [10,18], and 5 were cardiopathic and had received previous radiation therapy at the donor site [2,19]. One of the 2 cardiopathic patients also suffered from diabetes. One partial flap loss due to initial venous congestion required debridement of the flap and coverage with contralateral superior gluteal artery perforator flap because conservative treatment failed [19]. One total flap loss was due to the high dose vasopressors necessary for a patient suffering cardiac insufficiency in the immediate postoperative period [2], and another flap failed in a previously healthy patient [11]. No data regarding comorbidities was available for the remaining patients, who experienced minor and major complications [9,13-15].

Upper limb

Ninety-one upper limb patients were treated with 99 propeller flaps [2,3,7,20-25] for hand, axilla and elbow post-burn contracture [20-23,25] as well as trauma and post-trauma sequelae

[2,6,7,23-25], tumor excision [2,3,25], closure of the surgical donor site [3], bursitis [23] and radiodermatitis [23]. Eight patients received double flap reconstructions [20]. Many (n = 45) of the propeller flaps used the radial artery perforators [2,3,6,23,25] as the axes, and 39 [20-22] were nourished by a subcutaneous random pedicle, using the "central axis flap methods" originally described by Hyakasoku et al. [5]. The source vessels used for the remaining flaps were equally distributed among vessels of the upper limb [2,3,7,22,25]. Flap design and harvesting were performed according to preoperative Doppler evaluations in all cases, except in those studies in which a random subcutaneous pedicle was adopted. In these studies, no mapping of the perforator was provided [20,22]. In a single investigation perforator flaps were planned by mapping the perforators through the use of multirow-detector computed tomography angioscanning [7]. Direct closure of the donor site was achieved in 53 cases [2,7,20-24] and with a skin graft in 4 cases [2,21-24]. In the other 42 cases, these data were not available [3,6,20,25].

A flap suffering from venous congestion was not re-explored because the congestion resolved spontaneously [22]. Necrosis of the distal 40% of the flap (superior ulnar collateral artery perforator flap) in one patient due to flow congestion after primary closure of a flap defect in the arm required debridement and skin grafting. Distal ischemia worsened because of flap thinning just before the inset [24]. Three cases of venous congestion occurred in 2 radial [3,23] and 1 ulnar [3] artery forearm perforator flaps. In a case of necrosis, the residual defect after the debridement (necrosis of 20% of the flap) was covered with an abdominal flap [23]. Two flaps were treated with salvage venous supercharging. The ulnar artery perforator flap survived, and the radial artery perforator flap failed, more than likely as a result of delayed re-exploration. The latter was debrided and grafted 1 month later postoperatively [3]. The comorbidities of the patients who experienced minor and major complications were not stated within the papers [3,23,24].

DISCUSSION

With the present investigation we have systematically reviewed the current literature on this topic, providing additional insight on pedicled propeller flap safety and feasibility for upper body defect reconstructions with indications including defects following trauma and post-trauma revision surgery, cancer resection, chronic infection, pressure sores, and chronic ulcers (Tables 1, 2). Within the literature analyzed, 288 propeller flaps were used in a total of 276 patients with an overall complication rate of 13.8% (Table 2) [1-25]. Although this data should raise further concerns regarding the safety of propeller flaps, the major com-

plication rate (3.4%) is comparable to that of other series of free flaps.

There are contrasting opinions regarding the use of the supra- or subfascial plane for dissection. Although the chosen dissection plane is usually subfascial, there is no difference in the survival rate between fasciocutaneous [2,9-11,15,23,24] and adipocutaneous [1-3,6,17,23,25] propeller flaps (in one third of the articles reviewed, these data were not available [5,7,8,12,13,16,20-22]). Although the fascia is not necessary to augment the blood supply, in almost all papers, the subfascial approach is suggested for surgeons who have little experience in perforator surgery because this technique allows for efficient flap harvest and a clear visualization and isolation of the pedicle [2,3,25]. Although, in general, subfascial dissection is technically easier, suprafascial dissection leaves a less consistent donor site defect and makes flap dissection simpler at the sites where the muscular septa join the muscular fascia [2,3,25].

The location of the best perforator closest to the defect has been detected preoperatively with a handheld Doppler in almost all cases. In a few papers either multidetector-row computed tomography angiography (MDCTA) [7,8,23] or computed tomography angiography (CTA) [13,16] were adopted. From the review the superiority of MDCTA over the other less invasive imaging techniques should be presumed even if comparative studies are required, because it allows for determining a more precise location of the perforator and its subcutaneous course through 3D reconstruction imaging [7,9,23]. Anyway, using a handheld Doppler scanner to locate perforators followed by a quite generous incision to verify and choose the perforator during surgical exploration has been preferred by almost all authors. In this way different potentially useful perforators were made visible and the best one for the size and location was chosen. This procedure was considered less time-consuming, less expensive, repeatable and, with increased ability to perform propeller flaps, safe [1-6,9-19,21-25]. In no paper was Doppler imaging indicated to be the cause of inaccurate preoperative assessment (absence of perforator).

Propeller flap surgery should follow these principles. Flaps should be based on perforators as close to the midline or a fixed point (shoulder, elbow, and wrist in the upper extremity) as possible and be marked along the axis of the main source vessel. The safest orientation of the main axis of the flaps is transverse (perpendicular to midline) for the trunk and longitudinal for the upper extremity [2,3]. This positioning allows the vascular axis of flow between the perforator vascular territories to follow the direction of linking vessels [2,3]. Consequently, it is of great significance to consider the axiality of the blood flow when the skin paddle flap is designed because the perforasomes from the

same source artery are filled preferentially over adjacent vascular territories from other source arteries [7]. Due to highly variable anatomy, no rule regarding the maximal number of perforasomes to be included in a single-perforator flap has been validated [2,3]. Furthermore, it has been assumed that hyperperfusion in a single perforator flap leads to increased filling pressure, triggering the recruitment of neighboring perforasome territories. However, it is still unknown whether a limitation in the size of the perforator-based propeller flap should exist. Thus, questions regarding the correlation between the size of a perforator, its perfusion, and the largest volume of tissue that it can safely sustain remain unanswered and no precise guidelines on flap size can be suggested. In our review, two of the largest flaps nourished by a single 1-mm perforator measured 25×30 cm (750 cm², superior gluteal artery perforator) and were successfully used to resurface a 15×20 cm sacral defect [9], respectively. Thus, some authors have suggested that the real limitation of the flap size nourished by a single perforator should most likely be its design to allow donor site closure, rather than concerns about vascularity [3]. The empiric principle of the length-to-width ratio used for fasciocutaneous flaps needs to be revised and should not be applied to achieve a mathematic rule of safety for perfusion of freestyle pedicled-propeller flaps [3]. The eccentric location of the perforator defines the edge of the two blades of the propeller, splitting it into two skin islands, each with its own ratio. That is, a flap measuring 22×4 cm should not be considered as having a 5.5:1 ratio, but a perforator entering the flap at a point 8 cm from the tip splits the flap in two 8×4 cm and 14×4 cm minor skin island flaps with 2:1 and 3.5:1 ratios, respectively. To enlarge safely the original size of the perforator-based propeller, the location of a dominant perforator for supercharging in the distal part of the flap is confirmed preoperatively [8]. During flap elevation the perforator and its concomitant vein is left attached at the distal part of the extended flap, then they are anastomosed with the recipient vessels after the flap inset in the recipient site [8]. Venous supercharging alone may be adopted when venous insufficiency occurs by anastomosing a vein of the flap or a vein of a second perforator to a vein of the recipient site [2,3].

Pedicled propeller perforator flaps have widened the array of options for reconstructive surgeons. Because of their relatively recent introduction, skepticism has overshadowed their safety in clinical practice. This review showed that the major complication rate (3.4%) is comparable to those of free flaps that are widely considered safe. The ability to employ any perforator found close to the defect, which is capitalized upon with the propeller flap technique, grants the surgeon the freedom to customize skin islands, resurface defects with importation of undamaged tissue for easy closure without tension, and create pleasant cosmetic

outcomes without the sacrifice of any recipient vessels and with the preservation of muscle function.

REFERENCES

1. Karsidag S, Ozcan A, Sumer O, et al. Single-stage ala nasi reconstruction: lateral nasal artery perforator flap. *J Craniofac Surg* 2010;21:1887-9.
2. Lecours C, Saint-Cyr M, Wong C, et al. Freestyle pedicle perforator flaps: clinical results and vascular anatomy. *Plast Reconstr Surg* 2010;126:1589-603.
3. D'Arpa S, Cordova A, Pignatti M, et al. Freestyle pedicled perforator flaps: safety, prevention of complications, and management based on 85 consecutive cases. *Plast Reconstr Surg* 2011;128:892-906.
4. Schonauer F, Vuppapapati G, Marlino S, et al. Versatility of the posterior auricular flap in partial ear reconstruction. *Plast Reconstr Surg* 2010;126:1213-21.
5. Hyakusoku H, Iwakiri I, Murakami M, et al. Central axis flap methods. *Burns* 2006;32:891-6.
6. Bravo FG, Schwarze HP. Free-style local perforator flaps: concept and classification system. *J Plast Reconstr Aesthet Surg* 2009;62:602-8.
7. Ayestaray B, Ogawa R, Ono S, et al. Propeller flaps: classification and clinical applications. *Ann Chir Plast Esthet* 2011;56:90-8.
8. Ono S, Chung KC, Hayashi H, et al. Application of multi-detector-row computed tomography in propeller flap planning. *Plast Reconstr Surg* 2011;127:703-11.
9. Xu Y, Hai H, Liang Z, et al. Pedicled fasciocutaneous flap of multi-island design for large sacral defects. *Clin Orthop Relat Res* 2009;467:2135-41.
10. Jakubietz RG, Jakubietz MG, Jakubietz DF, et al. Ischial pressure sores: reconstruction using the perforator-based reverse flow musculocutaneous 180 degrees propeller flap. *Microsurgery* 2009;29:672-5.
11. Korambayil PM, Allalasundaram K, Balakrishnan T. Perforator propeller flaps for sacral and ischial soft tissue reconstruction. *Indian J Plast Surg* 2010;43:151-7.
12. Unal C, Yirmibesoglu OA, Ozdemir J, et al. Superior and inferior gluteal artery perforator flaps in reconstruction of gluteal and perianal/perineal hidradenitis suppurativa lesions. *Microsurgery* 2011;31:539-44.
13. Wagstaff MJ, Rozen WM, Whitaker IS, et al. Perineal and posterior vaginal wall reconstruction with superior and inferior gluteal artery perforator flaps. *Microsurgery* 2009;29:626-9.
14. Jakubietz RG, Jakubietz DF, Zahn R, et al. Reconstruction of pressure sores with perforator-based propeller flaps. *J Reconstr Microsurg* 2011;27:195-8.
15. Eom JS, Hong JP. Lower back defect coverage using a free-style gluteal perforator flap. *Ann Plast Surg* 2011;67:516-9.
16. Higuera Sune MC, Lopez Ojeda A, Narvaez Garcia JA, et al. Use of angioscanning in the surgical planning of perforator flaps in the lower extremities. *J Plast Reconstr Aesthet Surg* 2011;64:1207-13.
17. Oh TS, Hallock G, Hong JP. Freestyle propeller flaps to reconstruct defects of the posterior trunk: a simple approach to a difficult problem. *Ann Plast Surg* 2012;68:79-82.
18. Mun GH, Jo YW, Lim SY, et al. Pedicled perforator flap of stellate design. *J Plast Reconstr Aesthet Surg* 2008;61:1332-7.
19. Cheon YW, Lee MC, Kim YS, et al. Gluteal artery perforator flap: a viable alternative for sacral radiation ulcer and osteoradionecrosis. *J Plast Reconstr Aesthet Surg* 2010;63:642-7.
20. Murakami M, Hyakusoku H, Ogawa R. The multilobed propeller flap method. *Plast Reconstr Surg* 2005;116:599-604.
21. Aslan G, Tuncali D, Cigsar B, et al. The propeller flap for post-burn elbow contractures. *Burns* 2006;32:112-5.
22. Hosny H, El-Shaer W. The eight-limb modified propeller flap: a safer new technique. *Burns* 2011;37:905-9.
23. Ono S, Sebastin SJ, Yazaki N, et al. Clinical applications of perforator-based propeller flaps in upper limb soft tissue reconstruction. *J Hand Surg Am* 2011;36:853-63.
24. Bhat S, Shah A, Burd A. The role of freestyle perforator-based pedicled flaps in reconstruction of delayed traumatic defects. *Ann Plast Surg* 2009;63:45-52.
25. Mateev MA, Ogawa R, Trunov L, et al. Shape-modified radial artery perforator flap method: analysis of 112 cases. *Plast Reconstr Surg* 2009;123:1533-43.

Discussion**Indications, Outcomes, and Complications of Pedicled Propeller Perforator Flaps For Upper Body Defects**

Goo-Hyun Mun

Department of Plastic Surgery, Samsung Medical Center, Sungkyunkwan University School of Medicine, Seoul, Korea

In this article, "Indications, outcomes, and complications of pedicled propeller perforator flaps for upper body defects: A systematic review," Lazzeri et al. extensively reviewed the current literature to determine the reliability of this technique. The authors summarized the result for each of three different regions: the head and neck, upper limbs, and trunk and perineum. Among them, the trunk and perineum regions showed the highest complication rate. I think the larger flap size and higher proportion of patients having serious comorbid conditions in this group have contributed to the increased chance of surgical complications. The authors emphasized the reliability of this technique, stating that the pedicled perforator flap for upper body defects can provide safety comparable to the conventional free flap. Although, in my experience, a very low rate of complications in pedicled perforator flap surgery throughout the body can be observed, direct comparison of the complication rate between the pedicled perforator flap with the free flap oversimplifies the findings. Pedicled perforator flaps tend to be chosen for reconstruction of smaller defects without composite tissue loss and their usage is relatively limited to certain perforator locations.

Recently, a similar systematic literature review was performed by Gir et al. [1] for pedicled perforator flaps in the lower extremities and identified a total complication rate of 25.8%, which is almost twice that of the upper body reported in this study. The higher incidence of vasculopathy affecting the source vessel of the perforator pedicle in the lower leg of the aged patient group

could contribute to this discrepancy. In the risk factor analysis on the lower extremities of Gir et al. [1], age, cause of defect, and size of flap are not related to the complication rate, but location of defect is. The distal third of the lower leg had increased the rate of complications. In this study on the upper body, although the authors listed risk factors with each case suffering complications, a statistical analysis of relevant variables was not included. Thus it is impossible for readers to reach a firm conclusion on the safety of the pedicled perforator flap in the upper body region. The small sample size for each specific flap in this review could have made it difficult to elucidate the risk factors statistically. Furthermore, despite the fact that surgical technical factors such as competency of fine perforator dissection are among the most powerful variables, it is difficult to standardize them for analysis. A true meta-analysis based on a higher volume of cases which will be gathered in the future would provide a more solid conclusion on the proper indications and risk factors for each type of pedicled perforator flap.

I commend that the authors conduct an extensive review of the literature of pedicled perforator flaps in the upper body, and this contribution would be a starting point toward obtaining evidence on this topic.

REFERENCE

1. Gir P, Cheng A, Oni G, et al. Pedicled-perforator (propeller) flaps in lower extremity defects: a systematic review. *J Reconstr Microsurg* 2012;28:595-601.

Correspondence: Goo-Hyun Mun
Department of Plastic Surgery, Samsung Medical Center, Sungkyunkwan University School of Medicine, 81 Irwon-ro, Gangnam-gu, Seoul 135-710, Korea
Tel: +82-2-3410-2233, Fax: +82- 2-3410-0036, E-mail: gh.mun@samsung.com

No potential conflict of interest relevant to this article was reported.

Received: 6 Jan 2013 • Revised: 7 Jan 2013 • Accepted: 8 Jan 2013
pISSN: 2234-6163 • eISSN: 2234-6171
<http://dx.doi.org/10.5999/aps.2013.40.1.51> • Arch Plast Surg 2013;40:51