

## Case Report

# Failure of iodine uptake in microscopic pulmonary metastases after recombinant human thyroid-stimulating hormone stimulation

## ABSTRACT

Elevated thyroid stimulating hormone (TSH) is required when preparing for radioactive iodine therapy in patients with differentiated thyroid cancer. Recombinant human TSH (rhTSH: Thyrogen; Genzyme Corporation, Cambridge, MA) avoids hypothyroidism and has been commonly used in place of thyroid hormone withdrawal (THW) in this process. We describe a 31-year-old woman with sclerosing variant of papillary thyroid cancer with multiple lymph node metastases and elevated postoperative thyroglobulin suggesting the presence of distant metastases, who was found to have miliary pulmonary metastases on the posttherapy I-131 scan after THW, but not visible on the post therapy scan after rhTSH preparation.

**Keywords:** Hypothyroidism, radioiodine, recombinant human thyroid-stimulating hormone, thyrogen, thyroid cancer

## INTRODUCTION

Prior to the availability of recombinant human thyroid-stimulating hormone (rhTSH), patients who needed radioactive iodine (RAI) therapy routinely underwent thyroid hormone withdrawal (THW) to become sufficiently hypothyroid before RAI therapy. rhTSH avoids the hypothyroid symptoms of THW, was approved in the United States by the Food and Drug Administration (FDA) for remnant ablation in 2007, and has been commonly used in preparation for RAI therapy. Currently, rhTSH is not approved by the FDA for the use in patients with metastatic or persistent disease but has been offered off-label to patients who may not tolerate THW and who are unable to mount TSH elevation such as patients with hypopituitarism. Although two retrospective studies showed comparable efficacy between rhTSH and THW in patients with distant metastases,<sup>[1,2]</sup> iodine kinetics have been demonstrated to be different between rhTSH and THW.<sup>[3-5]</sup> We describe a patient with pulmonary military metastases that failed to take up iodine after <sup>131</sup>I therapy prepared by rhTSH. The metastases were revealed on the posttherapy scan after <sup>131</sup>I prepared by THW.

## CASE REPORT

A 31-year-old woman with a history of mesenchymal chondrosarcoma was found to have an FDG avid thyroid nodule on surveillance positron emission tomography-computed tomography (PET/CT). There was no evidence of distant metastases other than a few nonspecific lung nodules up to 4 mm on all cross-sectional imaging she underwent for the surveillance of chondrosarcoma. Additional evaluation with neck ultrasound and fine needle aspiration revealed papillary thyroid carcinoma. She underwent total thyroidectomy and left central and lateral

**COURTNEY LAWHN-HEATH, ROBERT R. FLAVELL, EUNICE Y. CHUANG<sup>1</sup>, CHIENYING LIU<sup>2</sup>**

Department of Radiology and Biomedical Imaging, University of California, <sup>1</sup>Department of Medicine, Division of Endocrinology and Metabolism, University of California, San Francisco, <sup>2</sup>Department of Endocrinology, Southern California Permanente Medical Group, Fontana, CA, USA


**Address for correspondence:** Dr. Courtney Lawhn-Heath, Department of Radiology and Biomedical Imaging, University of California, 505 Parnassus Avenue, M-391, San Francisco, CA, USA. E-mail: courtney.lawhnheath@ucsf.edu

**Submitted:** 05-Apr-2019, **Accepted:** 17-May-2019, **Published:** 14-Jan-2020

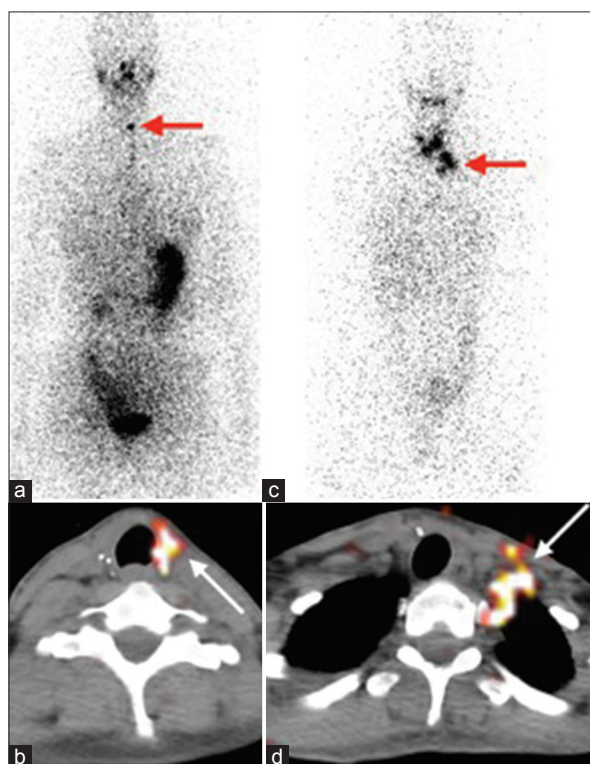
This is an open access journal, and articles are distributed under the terms of the Creative Commons Attribution-NonCommercial-ShareAlike 4.0 License, which allows others to remix, tweak, and build upon the work non-commercially, as long as appropriate credit is given and the new creations are licensed under the identical terms.

**For reprints contact:** reprints@medknow.com

**How to cite this article:** Lawhn-Heath C, Flavell RR, Chuang EY, Liu C. Failure of iodine uptake in microscopic pulmonary metastases after recombinant human thyroid-stimulating hormone stimulation. World J Nucl Med 2020;19:61-4.

Access this article online	
<b>Website:</b> www.wjnm.org	<b>Quick Response Code</b> 
<b>DOI:</b> 10.4103/wjnm.WJNM_29_19	

modified neck dissection. Pathology revealed a 3 cm diffuse sclerosing variant of papillary thyroid cancer in the left lobe with lymphovascular invasion and minimal extrathyroidal extension. Seventeen of the resected 31 lymph nodes were positive for metastases, many with extranodal extension (TNM-T3N1bMx). Five weeks postoperatively in June 2014, thyroglobulin (Tg) was 18.1 µg/L on levothyroxine suppression. Because of a history of depression, the patient was prepared for RAI therapy by rhTSH. <sup>123</sup>I scan [Figure 1a and b] demonstrated focal uptake in the thyroid bed with no evidence of cervical or distant metastases and an uptake of 0.6%. The patient then received 150 mCi of <sup>131</sup>I, a dose selected due to high-risk pathologic features and higher than expected postoperative Tg on levothyroxine suppression.



**Figure 1:** Diagnostic <sup>123</sup>I whole body scan (a) and axial fused single-photon emission computed tomography/computed tomography (b) demonstrated focal uptake in the thyroid bed (arrow) with no evidence of cervical or distant metastases. Posttherapy <sup>131</sup>I planar imaging (c) and axial fused single-photon emission computed tomography/computed tomography (d) demonstrated multiple foci of uptake in the neck compatible with nodal metastases (arrow)

Tg was stimulated to 133.8 µg/L on the day of RAI therapy 24 h after rhTSH stimulation, a level that is suggestive of distant metastases, with a TSH level of 103.84 mIU/L [Table 1].

However, posttherapy <sup>131</sup>I imaging [Figure 1c and d] demonstrated multiple areas of neck uptake consistent with cervical nodal metastases but no distant metastases. A follow-up neck ultrasound showed a few nonspecific nonenlarged cervical lymph nodes. Four months after RAI therapy, Tg was 18.6 µg/L on levothyroxine suppression, similar to the pretherapy level of 18.1 [Table 1]. Repeat CT and PET/CT for the surveillance of mesenchymal chondrosarcoma were unremarkable, demonstrating no evidence of metastases. Evaluation for heterophile antibodies against Tg was negative. Approximately 1 year after the initial RAI therapy, due to persistent although relatively stable Tg elevation, she underwent repeat RAI therapy prepared by THW in August 2015.

Pretherapy <sup>123</sup>I scan [Figure 2] demonstrated subtle uptake in the neck with faint uptake in the lower thorax but no definitive distant metastatic disease. However Tg was stimulated to 495 µg/L with a concurrent TSH of 92 mIU/L, again suggesting the presence of distant metastases [Table 1]. The patient was treated with 100 mCi of <sup>131</sup>I empirically for both therapeutic and diagnostic purposes. Posttherapy <sup>131</sup>I scan [Figure 3] demonstrated diffuse bilateral pulmonary uptake in addition to multifocal uptake in the neck. A noncontrast chest CT performed soon after RAI therapy was again negative with no correlate to the diffuse pulmonary <sup>131</sup>I uptake, suggestive of microscopic metastatic disease.

The patient's Tg levels have remained elevated but relatively stable, fluctuating mostly between 15 and 28 µg/L on TSH suppression (<0.1 mIU/L). The patient's last chest CT in November 2018 continued to show no evidence of macroscopic pulmonary metastases.

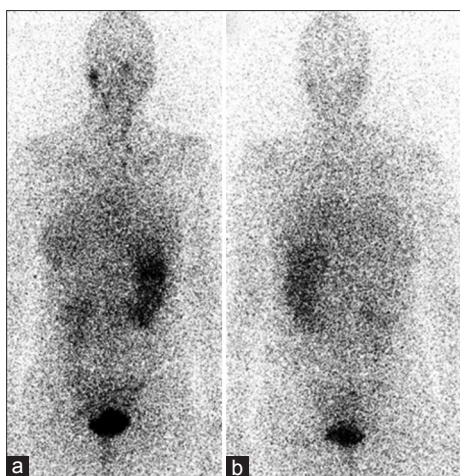
## DISCUSSION

Our case demonstrates a failure of iodine uptake in extensive microscopic pulmonary metastatic foci after rhTSH stimulation despite a higher dose of <sup>131</sup>I compared to THW.

**Table 1: Thyroglobulin levels after recombinant human thyroid-stimulating hormone stimulation versus thyroid hormone withdrawal**

Date	May 2014	June 2014	August 2014	October 2014	March 2015	June 2015	August 2015	August 2015	November 2015	March 2016	May 2018
Tg (µg/dL)	18.1	133.8	15.3	18.6	19.1	24.5	268.1	495.3	29.2	23.2	15.9
TSH (mIU/L)	0.35	103.84	0.10	0.24	0.27	0.20	75.57	92.34	0.41	0.51	0.02
Event		rhTSH					THW	THW			
		RAI						RAI			

The patient's Tg levels have remained elevated but relatively stable, fluctuating mostly between 15 and 25 µg/L (with negative Tg antibodies) on TSH suppression (<0.1 mIU/L). The patient's last chest CT in November 2018 continued to show no evidence of macroscopic pulmonary metastases. TSH: Thyroid-stimulating hormone; Tg: Thyroglobulin; rhTSH: Recombinant human thyroid-stimulating hormone; RAI: Radioactive iodine; THW: Thyroid hormone withdrawal; CT: Computed tomography

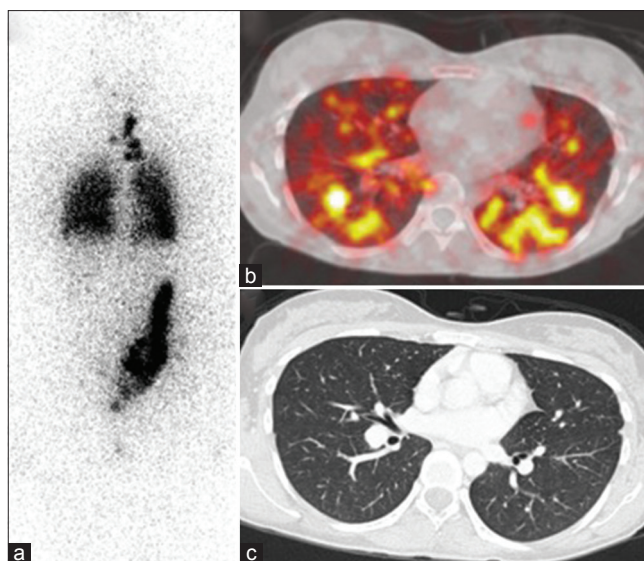


**Figure 2:** Approximately 1 year after initial radioactive iodine therapy, diagnostic  $^{123}\text{I}$  anterior (a) and posterior (b) images demonstrated two subtle foci of uptake at the left base of neck with faint uptake in the lower thorax but no definitive distant metastatic disease

Although rhTSH aided RAI, therapy for remnant ablation has been found to be better tolerated and to result in noninferior clinical outcomes compared to THW in randomized controlled studies.<sup>[5,6]</sup> Prospective studies using rhTSH for  $^{131}\text{I}$  therapy for metastatic disease are lacking. The two retrospective studies<sup>[1,2]</sup> using rhTSH in patients with distant metastases showed similar outcomes, but both studies employed dosimetry to determine RAI dosing [Figure 2].

Several studies have demonstrated altered iodine kinetics following rhTSH compared to the hypothyroid phase after THW.<sup>[3-5]</sup> With rhTSH,  $^{131}\text{I}$  effective half-life in the remnant was shown to be longer<sup>[4]</sup> and radiation dose to blood was lower.<sup>[5]</sup> However, studies by Pötzi *et al.*,<sup>[3]</sup> using dosimetry analyses and  $^{123}\text{I}$ , found rhTSH to be associated with lower iodine uptake and shorter median effective half-life in metastatic lesions. Impaired renal clearance during the hypothyroid phase after THW may be responsible for longer iodine retention with THW.<sup>[4]</sup> It has also been postulated that rhTSH's glycosylation pattern, which is distinct from endogenous pituitary TSH, might have led to different responses in iodine uptake because of variability in the TSH receptors on the tumor cells.<sup>[7]</sup>

Although progression of disease is a possible explanation for the discrepant uptake between rhTSH and THW, the relatively stable Tg levels between the 1<sup>st</sup> and the 2<sup>nd</sup> RAI therapy suggest otherwise. The more elevated Tg after THW (495  $\mu\text{g/L}$ ) versus rhTSH (133.8  $\mu\text{g/L}$ ) does not imply disease progression. First, Tg measurement after rhTSH in our patient took place only 24 h after the final rhTSH injection because of physical isolation required after  $^{131}\text{I}$  therapy. The expected Tg level at 24 h after the final rhTSH dose is lower than the maximally stimulated Tg expected at 72 h<sup>[8]</sup>;



**Figure 3:** Posttherapy  $^{131}\text{I}$  whole body scan (a) and fused axial single-photon emission computed tomography-computed tomography through the thorax (b) demonstrated diffuse bilateral pulmonary uptake in addition to multifocal uptake in the neck. A noncontrast chest computed tomography performed at the time for further evaluation (c) demonstrated no correlate to the diffuse pulmonary  $^{131}\text{I}$  uptake

second, stimulated Tg after rhTSH is known to be lower than stimulated Tg after THW.<sup>[9]</sup> The difference is thought to be due to more continuous and prolonged endogenous TSH stimulation in THW, leading to increased Tg synthesis and lower renal clearance rate in patients with hypothyroidism [Figure 3].<sup>[9]</sup>

Although military metastases were revealed on the post therapy scan after THW to explain the patient's chronically elevated Tg, our patient has continued to have persistent stable disease based on persistent but stably elevated Tg. It is unclear if a higher  $^{131}\text{I}$  dose might have resulted in a different clinical outcome.

Taïeb *et al.*<sup>[10]</sup> described a case similar to ours in which pulmonary micrometastases did not take up iodine after rhTSH stimulation but took up iodine consistently when  $^{131}\text{I}$  therapy was prepared by THW. Driedger and Kotowycz (reference) also documented two cases with metastases that failed to concentrate iodine after rhTSH stimulation but were able to concentrate iodine after THW in osseous and pulmonary metastases in both cases, as well as cervical lymph node metastases in one of the two cases.<sup>[7]</sup> Our case differs from prior reports in that the distant metastases were not apparent on cross-sectional imaging.

Although rhTSH avoids hypothyroid symptoms and is equally effective as THW for remnant ablation, prospective randomized control studies are lacking in patients with residual disease and distant metastases. rhTSH should be

used cautiously in these situations. Our case adds to previous case reports, both in 2004,<sup>[7,10]</sup> and serves as a reminder that THW-aided RAI therapy is preferred in patients with distant metastases.

#### Declaration of patient consent

The authors certify that they have obtained all appropriate patient consent forms. In the form the patient(s) has/have given his/her/their consent for his/her/their images and other clinical information to be reported in the journal. The patients understand that their names and initials will not be published and due efforts will be made to conceal their identity, but anonymity cannot be guaranteed.

#### Acknowledgment

We are grateful to the support of Randall Hawkins, MD, for his contribution in successfully bringing out this manuscript.

#### Financial support and sponsorship

Nil.

#### Conflicts of interest

There are no conflicts of interest.

#### REFERENCES

1. Klubo-Gwiedzinska J, Burman KD, Van Nostrand D, Mete M, Jonklaas J, Wartofsky L, *et al.* Radioiodine treatment of metastatic thyroid cancer: Relative efficacy and side effect profile of preparation by thyroid hormone withdrawal versus recombinant human thyrotropin. *Thyroid* 2012;22:310-7.
2. Tala H, Robbins R, Fagin JA, Larson SM, Tuttle RM. Five-year survival is similar in thyroid cancer patients with distant metastases prepared for radioactive iodine therapy with either thyroid hormone withdrawal or recombinant human TSH. *J Clin Endocrinol Metab* 2011;96:2105-11.
3. Pötzi C, Moameni A, Karanikas G, Preitfellner J, Becherer A, Pirich C, *et al.* Comparison of iodine uptake in tumour and nontumour tissue under thyroid hormone deprivation and with recombinant human thyrotropin in thyroid cancer patients. *Clin Endocrinol (Oxf)* 2006;65:519-23.
4. Hänscheid H, Lassmann M, Luster M, Thomas SR, Pacini F, Ceccarelli C, *et al.* Iodine biokinetics and dosimetry in radioiodine therapy of thyroid cancer: Procedures and results of a prospective international controlled study of ablation after rhTSH or hormone withdrawal. *J Nucl Med* 2006;47:648-54.
5. Pacini F, Ladenson PW, Schlumberger M, Driedger A, Luster M, Kloos RT, *et al.* Radioiodine ablation of thyroid remnants after preparation with recombinant human thyrotropin in differentiated thyroid carcinoma: Results of an international, randomized, controlled study. *J Clin Endocrinol Metab* 2006;91:926-32.
6. Schlumberger M, Catargi B, Borget I, Deandreis D, Zerdoud S, Bridji B, *et al.* Strategies of radioiodine ablation in patients with low-risk thyroid cancer. *N Engl J Med* 2012;366:1663-73.
7. Driedger AA, Kotowycz N. Two cases of thyroid carcinoma that were not stimulated by recombinant human thyrotropin. *J Clin Endocrinol Metab* 2004;89:585-90.
8. Haugen BR, Pacini F, Reiners C, Schlumberger M, Ladenson PW, Sherman SI, *et al.* A comparison of recombinant human thyrotropin and thyroid hormone withdrawal for the detection of thyroid remnant or cancer. *J Clin Endocrinol Metab* 1999;84:3877-85.
9. Pacini F, Molinaro E, Lippi F, Castagna MG, Agate L, Ceccarelli C, *et al.* Prediction of disease status by recombinant human TSH-stimulated serum Tg in the postsurgical follow-up of differentiated thyroid carcinoma. *J Clin Endocrinol Metab* 2001;86:5686-90.
10. Täieb D, Jacob T, Zotian E, Mundler O. Lack of efficacy of recombinant human thyrotropin versus thyroid hormone withdrawal for radioiodine therapy imaging in a patient with differentiated thyroid carcinoma lung metastases. *Thyroid* 2004;14:465-7.