

Interesting Cases

Unexpected rare metastases of renal cell carcinoma

ABSTRACT

Renal cell carcinomas (RCCs) commonly metastasize to the lungs and bones and rarely to the parathyroid, maxillary sinus, and adrenals. It is indeed very rare to have these all these metastases occurring simultaneously in an individual. We share a case of 67-year-old woman provisionally treated for parathyroid carcinoma but subsequently found to actually have metastatic RCC to the left maxillary sinus, parathyroid, lungs, and adrenals on ^{18}F -fluorodeoxyglucose positron emission tomography–computed tomography.

Keywords: ^{18}F -fluorodeoxyglucose, maxillary sinus, metastatic, parathyroid, positron emission tomography–computed tomography, renal cell carcinoma

INTRODUCTION

Renal cell carcinomas (RCCs) are known to have unpredictable patterns of metastases though the common sites are still the lungs and bones. It is rare to have metastases occurring in the parathyroid, maxillary sinus, and adrenals individually but even rarer to have these all these metastases occurring simultaneously.

CASE REPORT

A 67-year-old woman with no past medical history of significance, presented in March 2018, with a progressively enlarging left neck swelling. Fine-needle aspiration of the swelling was inconclusive, and she had total thyroidectomy due to the clinical suspicion of thyroid carcinoma at the inferior pole of the left thyroid gland. However, the histopathological examination of the surgical specimen revealed left inferior pole intrathyroidal clear-cell parathyroid carcinoma with thyroid capsular invasion (measuring 40 mm × 30 mm × 25 mm) and no involved regional lymph nodes. The panel of immunohistochemistry (IHC) tests performed were suggestive of parathyroid carcinoma. As her postsurgical intact parathyroid hormone (iPTH) and calcium levels were normal postsurgery, no further treatment was offered. However, she presented within 5 months with a new swelling at the left thyroid bed

with her iPTH and calcium levels still within normal range. ^{18}F -Fluorodeoxyglucose (^{18}F -FDG) positron emission tomography–computed tomography (PET-CT) was performed as a different pathology was suspected in view of the rapid reoccurrence of disease [Figures 1 and 2].

Based on the imaging findings, the metabolically active lesions were more likely secondary to metastatic clear cell RCC, and this was subsequently reconfirmed with re-examination of the initial surgical specimen and further IHC tests which demonstrated stronger staining for RCC, CD10, and PAX8 markers (compared to focal positivity in the initial IHC test).

DISCUSSION

RCC is a relatively common cancer with the global age-standardized incidence rate of 4.5/100,000 people/year. Unfortunately, the mortality is high despite newer targeted therapies with global age-standardized mortality rate of 1.8 per 100,000 people/

ALEX CHEEN HOE KHOO, YEW TEIK CHEONG¹

Departments of Nuclear Medicine and ¹Surgery,
Penang Adventist Hospital, Pulau Pinang, Malaysia


Address for correspondence: Dr. Alex Cheen Hoe Khoo,
Department of Nuclear Medicine, Penang Adventist Hospital, 456,
Jalan Burma 10350 Georgetown, Pulau Penang, Malaysia.
E-mail: dr.alexkhoo@gmail.com

Submitted: 21-Feb-2019, **Accepted:** 28-May-2019, **Published:** 14-Jan-2020

This is an open access journal, and articles are distributed under the terms of the Creative Commons Attribution-NonCommercial-ShareAlike 4.0 License, which allows others to remix, tweak, and build upon the work non-commercially, as long as appropriate credit is given and the new creations are licensed under the identical terms.

For reprints contact: reprints@medknow.com

How to cite this article: Khoo AC, Cheong YT. Unexpected rare metastases of renal cell carcinoma. World J Nucl Med 2020;19:89-91.

Access this article online	
Website: www.wjnm.org	Quick Response Code 
DOI: 10.4103/wjnm.WJNM_14_19	

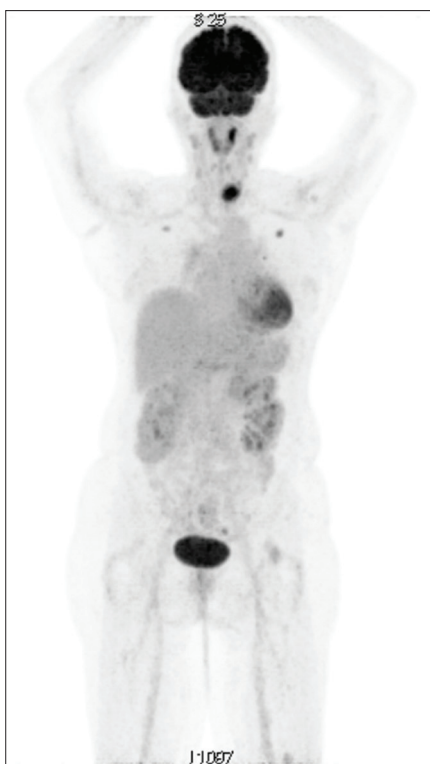


Figure 1: The maximal intensity projection of the ^{18}F -fluorodeoxyglucose positron emission tomography-computed tomography is shown with intense uptake seen at the left thyroid bed, bilateral lungs and mild uptake at the bilateral suprarenal regions

year.^[1] A large majority of the tumors are clear cell renal carcinoma (75%) followed by Types 1 and 2 papillary renal cancers, microphthalmia-associated transcription family translocation kidney cancers, chromophobe kidney cancer, and oncocytoma.^[2]

The identification of clear-cell carcinoma can be challenging due to the overlap in morphologic features from different primary sites. There are many kinds of clear cell carcinoma, including parathyroid, kidney, and liver. In view of IHC results and the rarity of metastatic RCC to the parathyroid gland, the initial diagnosis of parathyroid carcinoma was made. To our best knowledge, this is the 3rd case report in literature of RCC metastasis to the parathyroid gland.^[3] The utility of ^{18}F -FDG PET/CT in parathyroid carcinoma is not well established in the literature, but Evangelista *et al.* have demonstrated its benefit in the staging, restaging, and postsurgery evaluation of parathyroid carcinoma.^[4] Retrospectively, ^{18}F -FDG PET/CT could have been beneficial in the initial staging and incidentally establish the presence of metastatic RCC.

Surgery remains the only curative treatment available in spite of all the significant advancement in drug therapies. Unfortunately, curative surgery is only possible for patients with localized, locally advanced, and limited metastatic disease. Immunotherapies (interleukin-2 and interferon- 2α) were

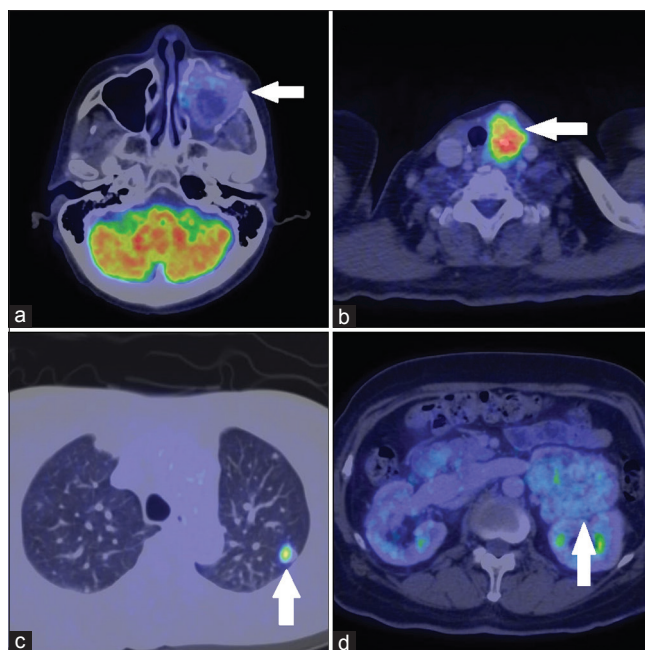


Figure 2: The fused axial positron emission tomography-computed tomography images – (a-d) show metastatic disease in the left maxillary antrum, left thyroid bed, left lung and left adrenal respectively with increased ^{18}F -fluorodeoxyglucose uptake

commonly used in the past, but in the recent years, multikinase inhibitors (sorafenib, sunitinib, and pazopanib) and mammalian target of rapamycin inhibitors (e.g., everolimus) have shown promising outcomes.^[5]

Imaging plays a role in the staging of confirmed RCC and detection of metastatic disease.^[6] The role of ^{18}F -FDG PET-CT in primary RCC is limited due to masking by physiological urinary excretion as demonstrated by many early clinical observations. ^{18}F -FDG PET-CT is very useful in the detection of metastatic disease, especially in this case where metastatic diseases to the left maxillary antrum, thyroid bed, lungs and adrenals were detected.^[7] In fact, a meta-analysis of 14 studies has shown that ^{18}F -FDG PET-CT has a pooled extrarenal lesion sensitivity and specificity of 91% and 88%, respectively.^[8] The occurrence of metastatic RCC to the parathyroid gland, maxillary antrum, and adrenals is rare, and unfortunately, all of these lesions were detected in this particular case. It should be highlighted that it is more common for RCC to metastasize to the lungs and bone.^[9] Nevertheless, RCC is among the most common infraclavicular tumor to metastasize to the head and neck region after breast and lung cancer.^[10]

CONCLUSION

^{18}F -FDG PET-CT is indeed a useful modality in staging metastatic RCC and may have a role in staging primary RCC due to the unpredictable metastatic nature of the disease.

Declaration of patient consent

The authors certify that they have obtained all appropriate patient consent forms. In the form the patient(s) has/have given his/her/their consent for his/her/their images and other clinical information to be reported in the journal. The patients understand that their names and initials will not be published and due efforts will be made to conceal their identity, but anonymity cannot be guaranteed.

Financial support and sponsorship

Nil.

Conflicts of interest

There are no conflicts of interest.

REFERENCES

1. Ferlay J, Colombet M, Soerjomataram I, Mathers C, Parkin DM, Piñeros M, *et al.* Estimating the global cancer incidence and mortality in 2018: GLOBOCAN sources and methods. *Int J Cancer* 2019;144:1941-53.
2. Linehan WM. Genetic basis of kidney cancer: Role of genomics for the development of disease-based therapeutics. *Genome Res* 2012;22:2089-100.
3. Torregrossa L, Rotondo MI, Cacciato Insilla A, Galleri D, Guidoccio F, Miccoli P, *et al.* Metastasis of renal cell carcinoma to the parathyroid gland 16 years after radical nephrectomy: A case report. *Oncol Lett* 2016;12:3224-8.
4. Evangelista L, Sorgato N, Torresan F, Boschini IM, Pennelli G, Saladini G, *et al.* FDG-PET/CT and parathyroid carcinoma: Review of literature and illustrative case series. *World J Clin Oncol* 2011;2:348-54.
5. Grimm MO, Wolff I, Zastrow S, Fröhner M, Wirth M. Advances in renal cell carcinoma treatment. *Ther Adv Urol* 2010;2:11-7.
6. Liu Y. The place of FDG PET/CT in renal cell carcinoma: Value and limitations. *Front Oncol* 2016;6:201.
7. Sankineni S, Brown A, Cieciera M, Choyke PL, Turkbey B. Imaging of renal cell carcinoma. *Urol Oncol* 2016;34:147-55.
8. Wang HY, Ding HJ, Chen JH, Chao CH, Lu YY, Lin WY, *et al.* Meta-analysis of the diagnostic performance of [18F] FDG-PET and PET/CT in renal cell carcinoma. *Cancer Imaging* 2012;12:464-74.
9. Gong J, Maia MC, Dizman N, Govindarajan A, Pal SK. Metastasis in renal cell carcinoma: Biology and implications for therapy. *Asian J Urol* 2016;3:286-92.
10. Ofo E, Mandavia R, Jeannon JP, Odell E, Simo R. Renal cell carcinoma metastasis to the parathyroid gland: A very rare occurrence. *Int J Surg Case Rep* 2014;5:378-80.