

Effectiveness and tolerability of nimotuzumab in unresectable, locally advanced/metastatic esophageal cancer: Indian hospital-based retrospective evidence

Sundaram Subramanian, Nithya Sridharan, V. Balasundaram, Sameer Chaudhari¹

Abstract

Context: Epidermal growth factor receptor (EGFR) is overly expressed in esophageal squamous cell carcinoma (ESCC) and is important prognostic and predictive biomarker. Nimotuzumab is a humanized anti-EGFR monoclonal antibody and has documented promising clinical outcomes and survival rates in various solid tumors with high EGFR expression. **Aims:** Attempt to fill gap on paucity of data in India on the efficacy of Nimotuzumab in the treatment of locally advanced/metastatic ESCC. **Settings and Design:** Hospital records of 15 patients with unresectable, locally advanced/metastatic esophageal cancers, histologically confirmed squamous cell carcinoma being treated with Nimotuzumab along with standard treatments from October 2006 to November 2016 were retrospectively analyzed. **Subjects and Methods:** The tumor response rate and overall survival (OS) were analyzed. All patients were assessed for toxicity and adverse events (AEs) as per Common Terminology Criteria for Adverse Events (CTCAE) v4. **Results:** Majority had lower thoracic esophageal cancer. Tumor response rate observed was as follows 33% had a complete response, 67% had a partial response, and objective response rate was 100%. Survival rate at 1-, 3-, and 5-year was 58.33%, 29.17%, and 29.17%, respectively. Median OS was 26.8 months (95% confidence interval, 2.63–not reached). No Grade III or Grade IV AEs were observed. No added toxicity was observed due to nimotuzumab. **Conclusions:** Nimotuzumab combined with standard treatment in locally advanced/metastatic ESCC improved the survival rate and achieved a better tumor response rate without accumulation of toxicity and was well tolerated.

Key words: Advanced, antibodies, carcinoma, esophageal neoplasms, inoperable, metastatic, monoclonal, nimotuzumab, overall survival, squamous cell, tumor response

Introduction

Esophageal cancer is the eighth most common cancer worldwide with an annual incidence of 456,000 new cases.^[1] In India, it is the fourth most common cause of cancer-related deaths.^[2] The incidence of esophageal carcinoma varies widely by geographical location. In Asian belt, the predominant histological type is squamous cell carcinoma, whereas adenocarcinoma is predominant in western countries.^[3] Tobacco consumption in various forms, alcohol, hot beverages, and poor nutrition remain the predominant predisposing factors.^[2,3] Esophageal squamous cell carcinoma (ESCC) is the most common type in the Indian subcontinent and distal third of the esophagus being the most common site.^[2,4]

The cornerstone of curative treatment has been surgery. However, for a variety of reasons, the majority of patients are not suitable for surgery. More than 50% have locally advanced unresectable or metastatic tumors at diagnosis.^[5] The mainstay of nonsurgical treatment is chemotherapy or radiotherapy, either alone or in combination (chemoradiotherapy). Chemoradiotherapy has now become the standard treatment in patients with locally advanced or metastatic ESCC but is associated with increased risk of toxicity and the 5-year survival being <20%.^[6,7] Therefore, the need for balancing the clinical outcome and toxicity without compromising the survival benefit has led to the development of biological-targeted therapies as novel treatment options.

Epidermal growth factor receptor (EGFR) is overly expressed in 43%–89% squamous cell esophageal carcinomas.^[8,9] The EGFR overexpression is strongly associated with increased metastasis, decreased survival, poor prognosis, and treatment resistance.^[10-12] Nimotuzumab is an anti-EGFR humanized monoclonal antibody. Several clinical studies conducted in various solid tumors with

EGFR overexpression have documented promising results with improvement in the tumor response rate and overall survival (OS) with minimal treatment-related toxicities.^[13-16] Thus, nimotuzumab has garnered increasing interest among researchers.

Recently, studies in the Asian belt have documented growing evidence on improved tumor response and survival rates in esophageal carcinoma with nimotuzumab in combination with standard treatment/regimens with minimal toxicities.^[17-21]

In India, there exists a paucity of data in the literature on the efficacy of nimotuzumab with standard treatment in esophageal carcinoma. Therefore, in the present study, we retrospectively evaluated the effectiveness and tolerability of nimotuzumab combined with standard treatment in locally advanced or metastatic esophageal cancer patients.

Subjects and Methods

This retrospective study evaluated the effectiveness and tolerability of nimotuzumab with standard treatment. We reviewed the hospital records of ESCC patients treated with nimotuzumab combined with standard treatment (chemotherapy or radiotherapy or concurrent chemoradiotherapy) from October 2006 till November 2016 at V. S. Hospital and Madras Cancer Center, Chennai (India). The study was approved by the Institutional Review Board.

The study cases were selected based on the following inclusion criteria (a) patients of age 18 years and above, (b) patients with Stage III–IV, (c) histologically confirmed squamous cell carcinoma of the esophagus, (d) patients with locally advanced or recurrent/metastatic esophageal carcinoma, (e) patients with Eastern Cooperative Oncology Group (ECOG) performance

This is an open access journal, and articles are distributed under the terms of the Creative Commons Attribution-NonCommercial-ShareAlike 4.0 License, which allows others to remix, tweak, and build upon the work non-commercially, as long as appropriate credit is given and the new creations are licensed under the identical terms.

For reprints contact: reprints@medknow.com

How to cite this article: Subramanian S, Sridharan N, Balasundaram V, Chaudhari S. Effectiveness and tolerability of nimotuzumab in unresectable, locally advanced/metastatic esophageal cancer: Indian hospital-based retrospective evidence. *South Asian J Cancer* 2019;8:112-5.

Access this article online

Quick Response Code:



Website: www.sajc.org

DOI: 10.4103/sajc.sajc_89_18

V. S Hospital and Cancer Center, Chennai, Tamil Nadu, ¹Medical advisor, Biocon Ltd, Bengaluru, Karnataka, India

Correspondence to: Dr. Nithya Sridharan, E-mail: nithya.hhk@gmail.com

score ≤ 2 , and (f) patients treated with nimotuzumab (200 mg weekly) combined with standard treatment. We excluded patients of nonesophageal cancers and patients previously treated with other anti-EGFR-based therapy. Clinical data of patients were collected from hospital records, which included the diagnosis, age, gender, pathological type, tumor stage, tumor grade, ECOG score, and clinical course with the details of standard care treatment and nimotuzumab therapy.

Evaluating parameters

The Response Evaluation Criteria in Solid Tumors 1.1 were used to evaluate tumor response to the treatment. Complete remission (CR), partial remission (PR), stable disease (SD), and progression disease was calculated. The objective response rate (ORR) was also calculated. OS was defined as the time from date of diagnosis to the date of death due to any causes or the last follow-up/last contact. Adverse events (AEs) were collected and graded by the National Cancer Institute's Common Toxicity Criteria version 4.

Statistical analysis

Statistical analysis was conducted using STATA software (version. 12, StataCorp., Texas, USA). Data were expressed in descriptive statistics. Median OS along with 95% confidence interval (CI) was estimated by the Kaplan–Meier method.

Results

General characteristics

A total of fifteen ($n = 15$) patients of locally advanced or recurrent/metastatic ESCC was found to be eligible and considered for the final analysis. The mean age of the enrolled patients was 55.33 ± 13.3 years with seven males (47%) and eight females (53%). The most common anatomical site of the tumor was lower thoracic esophagus (53.33%) followed by middle thoracic esophagus (27.7%). Majority of patients had a good performance status (ECOG 0–1). The baseline characteristics and type of standard treatment in unresectable, locally advanced or recurrent/metastatic ESCC patients are listed in Table 1.

Effectiveness

The tumor response rate observed was as follows 33% of patients had a complete response and 67% of patients had partial response. The objective response rate was 100% [Table 2].

Survival outcome – in this retrospective analysis, we observed that the 1-, 3-, and 5-year OS rates achieved with nimotuzumab combined with standard treatment were 58.33%, 29.17%, and 29.17%, respectively [Figure 1]. The median OS was 26.8 months (95% CI, 2.63–not reached).

Safety and toxicity

The common AEs observed during treatment were vomiting (25%) followed by neutropenia (20.8%) and esophagitis (16.7%). The detailed toxicity and their grades of the combination therapy are summarized in Table 3. No grade three, four, and five toxicities were observed.

Discussion

The findings of the present retrospective analysis indicate that addition of nimotuzumab to standard treatment improved the therapeutic response and survival in patients with unresectable, locally advanced and recurrent/metastatic esophageal cancer.

Table 1: Baseline characteristics of patients with unresectable, local advanced/metastatic esophageal squamous cell carcinoma

Characteristics	Value (%)
Total patients (n)	15
Mean age (years)±SD	55.33±13.32
Median age in years (IQR)	50 (45, 50, 67)
Age group (years)	
35-45	4 (27)
46-57	4 (27)
58-69	4 (27)
70-80	3 (20)
Gender	
Male	7 (47)
Female	8 (53)
Performance status	
ECOG - 0	6 (40)
ECOG - 1	9 (60)
Anatomical sub-sites esophagus	
Upper thoracic esophagus	2 (13.3)
Middle thoracic esophagus	4 (27.7)
Lower thoracic esophagus	8 (53.3)
Upper and middle thoracic esophagus	1 (6.7)
Stage	
Stage III	9 (60)
Stage IV	6 (40)
Type of standard treatment	
CT + nimotuzumab	3 (20)
RT + nimotuzumab	1 (6.7)
CTRT + nimotuzumab	6 (40)
ICT + nimotuzumab	1 (6.7)
ICT, CTRT + nimotuzumab	3 (20)
ICT + nimotuzumab, CTRT + nimotuzumab	1 (6.7)

CT=Chemotherapy, CTRT=Chemoradiotherapy, ICT=Induction chemotherapy, RT=Radiotherapy, ECOG: Eastern Cooperative Oncology Group, IQR=Interquartile range, SD=Standard deviation

Table 2: Overall tumor response in patients treated with nimotuzumab and standard treatment

Overall tumor response	n (%)
CR	5 (33.3)
PR	10 (66.7)
SD	0
PD	0
ORR	15 (100)

CR=Complete response, PR=Partial response, SD=Stable disease, PD=Progressive disease, ORR=Objective response rate

Table 3: Common adverse events encountered during the treatment

Adverse events	Grade 1-2	Grade 3-4	Total number (%)
Vomiting	6	0	6 (25)
Neutropenia	5	0	5 (20.8)
Anemia	2	0	2 (8.4)
Esophagitis	4	0	4 (16.7)
Skin rash	3	0	3 (12.5)
Mucositis	1	0	1 (4.2)
Diarrhea	1	0	1 (4.2)
Fatigue	2	0	2 (8.4)
Total			24 (100)

Esophageal cancer is aggressive cancer. Despite advances in its treatment standard, the outcome is unsatisfactory due to poor local control and distant metastasis, with a 5-year survival

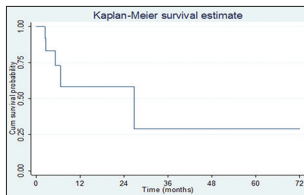


Figure 1: Kaplan-Meier overall survival curve of patients with unresectable, local advanced or recurrent/metastatic esophageal squamous cell carcinoma treated with nimotuzumab and standard treatment

rate <20%.^[6,7] Concurrent chemoradiotherapy is a valuable treatment option in advanced esophageal cancer. In the advanced setting, median survival beyond 1 year has not been achieved with any combination chemotherapy.^[7] Therefore, alternative novel treatment strategies are being explored to improve efficacy and prolong the survival rate without compromising the safety.

EGFR is an important prognostic and predictive biomarker in ESCC. The EGFR overexpression is strongly associated with increased metastasis, decreased survival, poor prognosis, and treatment resistance.^[8-12] Thus Inhibiting EGFR pathway can inhibit tumor cell proliferation, differentiation, tumor angiogenesis, and promote treatment response of chemotherapy and radiation.^[11]

Nimotuzumab (BIOMab EGFR®) is a newer, humanized anti-EGFR MAb, which blocks the EGFR activation and its downstream signaling by binding to the extracellular domain of the EGFR with intermediate affinity and high specificity.^[7,22] It also enhances the radiosensitivity in esophageal cancer cells by inhibiting the EGFR/Akt/DNA-PKcs signaling pathway and reducing ATM and Rad51 activities.^[23] Nimotuzumab requires bivalent binding for stable attachment, which leads to selective binding to cells expressing moderate to high EGFR levels. When EGFR density is low, such as in normal tissues, monovalent interaction of nimotuzumab is transient, thus sparing healthy tissues and avoiding severe toxicities.^[24] This probably explains the unique benign safety profile and minimal treatment-related toxicities of nimotuzumab in comparison with other anti-EGFR Mabs.

To the best of our knowledge, this is the first Indian study documenting scientific (retrospective) evidence on the effectiveness, survival benefits, and tolerability of Nimotuzumab in combination with standard treatment in Indian patients with unresectable, locally advanced/metastatic ESCC.

In the present retrospective analysis, the addition of nimotuzumab to the standard treatment resulted in improved tumor response and survival in unresectable, locally advanced and recurrent/metastatic squamous cell esophageal cancer. The tumor response rate observed was as follows 33% of patients had a complete response and 67% of patients had partial response. The objective response rate was 100%. The OS benefit achieved with the combination at 1-, 3- and 5-year were 58.33%, 29.17 and 29.17% respectively. The median OS was 26.8 months (95% CI, 2.63 - not reached). Interestingly, these findings of favorable therapeutic and survival benefits are similar to nimotuzumab studies conducted in the Asian belt.^[17-21]

Studies in the Asian belt have documented evidence on improved tumor response and survival rates with nimotuzumab in combination with various investigator's choice of standard treatment in esophageal carcinoma.^[17-21]

Nimotuzumab combined radiotherapy

In Phase II, clinical trial by Liang *et al.* treated 42 patients with esophageal cancers with the combination of radiotherapy and nimotuzumab.^[17] The median survival time observed was 14 months, and the median progression-free survival (PFS) was 10 months with the combination. The 2 and 3 years' OS rates were 33.3% and 26.2%, respectively, and the corresponding PFS rates were 24.5% and 22.1%. In this study, most patients achieved CR at 6 months after the treatment, suggesting a delayed therapeutic effect. The study also documented that EGFR overexpression was common and patients with a higher EGFR expression group (EGFR, +++) had a higher OS and a median survival time compared to low expression (EGFR, ++) group. Nimotuzumab was well tolerated in this study with no serious AEs.^[17]

A study by Guo *et al.*, in elderly patients with ESCC have also documented that the combination of nimotuzumab combined with radiotherapy was effective and tolerable. Elderly patients experienced Grade I/II radiation esophagitis, but no Grade III/IV toxicities were reported. No hematological, gastrointestinal, hepatic, or renal toxicities were observed in the study.^[25] Thus, the combination of nimotuzumab combined with radiotherapy was well tolerated in geriatric subset.

Nimotuzumab combined with chemotherapy

A prospective Phase II study by Lu *et al.* evaluated the efficacy and safety of the combination of nimotuzumab with paclitaxel and cisplatin (total parenteral nutrition) in 56 patients as first-line treatment for advanced ESCC.^[18] In the study, ORR was 51.8% and disease control rate (DCR) (CR + PR + SD) was 92.9%. The median OS observed in all the patients was 20.2 months. Among patients with local-regional advanced disease, the median OS was not reached. Among patients with metastatic disease, median OS time was 14 months. The most common Grade III/IV toxicities were neutropenia (46.4%), nausea (48.3%), alopecia (78.6%), anorexia (42.8%), vomiting (55.4%), arthralgia (62.5%), and anorexia (5%). Addition of nimotuzumab to the standard TP regimen was found to be safe and well tolerated.^[18]

Similarly, Han *et al.*, retrospectively analyzed the evaluated the safety and efficacy of nimotuzumab in combination with chemotherapy regimens in patients with locally advanced/metastatic esophageal cancer.^[19] The study documented that the objective response rate was 38.1% and disease control rate was 81%. The mean progression-free survival was seven months, and the 18-month OS was 10%. The most common AEs observed were myelosuppression, anemia, and leukopenia. No long-term drug-related toxicity was observed during the follow-up. Nimotuzumab in combination with standard chemotherapy regimen in this study achieved better clinical outcomes, without accumulation of toxicity and was well tolerated.^[19]

Nimotuzumab combined with chemoradiotherapy

Lai *et al.*, in a retrospective study observed the efficacy and toxicities of combined nimotuzumab with chemoradiotherapy in 43 patients with locally advanced and metastatic ESCC.^[20] At 1 month after the treatment, objective response rate was 65.12%, and disease control rate was 86.05%. The 1- and 2-year OS rates were 67.44% and 27.91%, respectively. The median OS was 15.5 months, and the median PFS was

8.83 months. Multivariate analysis showed that the patients with more cycles (>6 times) of nimotuzumab treatment had a better PFS and OS than those with fewer cycles (≤ 6 times).^[20]

Similarly, Wang *et al.*, retrospectively recruited 66 patients with ESCC treated with nimotuzumab and chemoradiotherapy/radiotherapy.^[21] Patients who received more than 1,200 mg of nimotuzumab (200 mg/week for six cycles, which equals to 1,200 mg in total) were classified as the high-dose group, and the remaining patients were classified as the low-dose group. The 1-, 2-, and 3-year OS rates in the low-dose and high-dose groups were 66.9%, 50.0%, 31.5% and 90.0%, 80.0%, 66.7%, respectively ($P = 0.04$). Multivariate analysis showed that the high-dose group had better survival than the low-dose group. Taken together, high-dose nimotuzumab showed limited toxicity and improved survival in patients with ESCC. The median OS for the low-dose group was 22.1 months, whereas that of the high-dose group was not reached at the end of the study.^[21]

In Indian setting, there is a paucity of evidence in literature on Nimotuzumab in ESCC. An individual case report by Sharma, in a 70-year-old obese female with locally advanced ESCC has recognized the effectiveness of nimotuzumab in combination with chemoradiotherapy. In the case report, the patient responded well to the combination therapy and resulted in the near absence of tumor lesion, which was evident on a repeat, posttreatment whole-body positron emission tomography-computed tomography scan. The therapy was well tolerated without any significant adverse effects.^[26]

In the present study, the common AEs observed during treatment were vomiting followed by neutropenia and esophagitis, which are similar to documented studies.^[19,20] No grade III, IV, and V toxicity was observed. No anti-EGFR-related toxicity such as severe skin rash, infusion reactions, or hypomagnesemia was observed. Nimotuzumab was observed to be safe with no additional potentiating AEs encountered.

In summary, the study suggests that the addition of nimotuzumab to standard treatment to be a promising, novel and effective treatment option in Indian patients with unresectable, locally advanced/metastatic squamous cell esophageal cancer. Further prospective, multicenter, randomized clinical trials are warranted to validate these interesting findings.

The study had few limitations: first, the study design was retrospective with a single arm assessment. Second, the sample size was small. Third, the retrospective data included patients treated with heterogeneous standard treatment.

Conclusion

The addition of Nimotuzumab to standard treatment improved the survival rate, achieved a better tumor response rate and was well-tolerated in unresectable, locally advanced/ metastatic ESCC.

Acknowledgment

We would like to thank Ramez Ahmed, Medical Affairs- Biocon, for his valuable inputs and transcribing the manuscript.

Financial support and sponsorship

Nil.

Conflicts of interest

There are no conflicts of interest.

References

1. Bray F, Jemal A, Grey N, Ferlay J, Forman D. Global cancer South Asian Journal of Cancer ♦ Volume 8 ♦ Issue 2 ♦ April-June 2019

- transitions according to the human development index (2008-2030): A population-based study. *Lancet Oncol* 2012;13:790-801.
2. Samarasam I. Esophageal cancer in India: Current status and future perspectives. *Int J Adv Med Health Res* 2017;4:5-10.
3. Pennathur A, Gibson MK, Jobe BA, Luketich JD. Oesophageal carcinoma. *Lancet* 2013;381:400-12.
4. Cherian JV, Sivaraman R, Muthusamy AK, Jayanthi V. Carcinoma of the esophagus in Tamil Nadu (South India): 16-year trends from a tertiary center. *J Gastrointest Liver Dis* 2007;16:245-9.
5. Enzinger PC, Mayer RJ. Esophageal cancer. *N Engl J Med* 2003;349:2241-52.
6. Zingg U, Divalentino D, McQuinn A, Mardzuki A, Thompson SK, Karapetis CS, *et al.* Outcome for esophageal cancer following treatment with chemotherapy and radiotherapy but not esophagectomy: Nonsurgical treatment of esophageal cancer. *Clin Exp Gastroenterol* 2009;2:75-83.
7. Zhu LL, Yuan L, Wang H, Ye L, Yao GY, Liu C, *et al.* A meta-analysis of concurrent chemoradiotherapy for advanced esophageal cancer. *PLoS One* 2015;10:e0128616.
8. Harari PM. Epidermal growth factor receptor inhibition strategies in oncology. *Endocr Relat Cancer* 2004;11:689-708.
9. Hanawa M, Suzuki S, Dobashi Y, Yamane T, Kono K, Enomoto N, *et al.* EGFR protein overexpression and gene amplification in squamous cell carcinomas of the esophagus. *Int J Cancer* 2006;118:1173-80.
10. Yu WW, Guo YM, Zhu M, Cai XW, Zhu ZF, Zhao WX, *et al.* Clinicopathological and prognostic significance of EGFR over-expression in esophageal squamous cell carcinoma: A meta-analysis. *Hepatogastroenterology* 2011;58:426-31.
11. Wykosky J, Fenton T, Furnari F, Cavene WK. Therapeutic targeting of epidermal growth factor receptor in human cancer: Successes and limitations. *Chin J Cancer* 2011;30:5-12.
12. Joseph B, Sruthi K, Vishwanath L. EGFR Targeting in oesophageal squamous cell carcinoma: Potential role and rationale. *Clin Oncol* 2017;2:1247.
13. Ramakrishnan MS, Eswaraiah A, Crombet T, Piedra P, Saurez G, Iyer H, *et al.* Nimotuzumab, a promising therapeutic monoclonal for treatment of tumors of epithelial origin. *MAbs* 2009;1:41-8.
14. Saurez-Martínez G, Bencomo-Yanes A. Nimotuzumab effective immunotherapy for the treatment of malignant epithelial tumors. *Biotechnol Apl* 2014;31:159-67.
15. Reddy BK, Lokesh V, Vidyasagar MS, Shenoy K, Babu KG, Shenoy A, *et al.* Nimotuzumab provides survival benefit to patients with inoperable advanced squamous cell carcinoma of the head and neck: A randomized, open-label, phase IIb, 5-year study in Indian patients. *Oral Oncol* 2014;50:498-505.
16. Xu S, Ramos-Suzarte M, Bai X, Xu B. Treatment outcome of nimotuzumab plus chemotherapy in advanced cancer patients: A single institute experience. *Oncotarget* 2016;7:33391-407.
17. Liang J, Mingyan E, Wu G, Zhao L, Li X, Xiu X, *et al.* Nimotuzumab combined with radiotherapy for esophageal cancer: Preliminary study of a phase II clinical trial. *Onco Targets Ther* 2013;6:1589-96.
18. Lu M, Wang X, Shen L, Jia J, Gong J, Li J, *et al.* Nimotuzumab plus paclitaxel and cisplatin as the first line treatment for advanced esophageal squamous cell cancer: A single centre prospective phase II trial. *Cancer Sci* 2016;107:486-90.
19. Han X, Lu N, Pan Y, Xu J. Nimotuzumab combined with chemotherapy is a promising treatment for locally advanced and metastatic esophageal cancer. *Med Sci Monit* 2017;23:412-8.
20. Lai X, Gu Q, Zheng X, Liu G, Feng W, Lin X, *et al.* Combined nimotuzumab with chemoradiotherapy in patients with locally advanced or metastatic esophageal squamous cell carcinoma: A retrospective study. *J Cancer Res Ther* 2016;12:89-95.
21. Wang C, Fu X, Cai X, Wu X, Hu X, Fan M, *et al.* High-dose nimotuzumab improves the survival rate of esophageal cancer patients who underwent radiotherapy. *Onco Targets Ther* 2016;9:117-22.
22. Perez R, Moreno E, Garrido G, Crombet T. EGFR-targeting as a biological therapy: Understanding nimotuzumab's clinical effects. *Cancers (Basel)* 2011;3:2014-31.
23. Liu H, Yang W, Gao H, Jiang T, Gu B, Dong Q, *et al.* Nimotuzumab abrogates acquired radio resistance of KYSE5E-150R esophageal cancer cells by inhibiting EGFR signaling and cellular DNA repair. *Onco Targets Ther* 2015;8:509-18.
24. Garrido G, Tikhomirov IA, Rabasa A, Yang E, Gracia E, Iznaga N, *et al.* Bivalent binding by intermediate affinity of nimotuzumab: A contribution to explain antibody clinical profile. *Cancer Biol Ther* 2011;11:373-82.
25. Guo JH, Chen MQ, Chen C, Lu HJ, Xu BH. Efficacy and toxicity of nimotuzumab combined with radiotherapy in elderly patients with esophageal squamous cell carcinoma. *Mol Clin Oncol* 2015;3:1135-8.
26. Sharma JP. Nimotuzumab in combination with chemo-radiotherapy in a case of locally advanced oesophageal malignancy. *J Case Rep* 2016;6:313-6.