

## Letter to the Editor

# Mucosal melanoma of the head-and-neck region: A single institutional clinical experience

DOI: 10.4103/sajc.sajc\_326\_18

Dear Editor,

Due to the rarity of mucosal melanoma, the scientific knowledge is limited compared to its cutaneous counterpart. Weber reported the first case of mucosal melanoma of the head-and-neck region in 1856.<sup>[1]</sup> The largest case series of mucosal melanoma of the head-and-neck region was reported by Bachar *et al.*<sup>[2]</sup> with 61 patients over 41 years and in India, Gupta *et al.*<sup>[3]</sup> reported 42 patients over the period of 8 years. This is one such attempt with four cases over 1 year.

A 26-year-old female patient presented with the complaints of epistaxis and nasal obstruction. Computed tomography-scan (CT) revealed a large expansile soft-tissue mass in the right maxillary sinus extending into the nasal cavity, right upper alveolar arch, right orbit, and right buccal space. Biopsy and immunohistochemistry confirmed the diagnosis of malignant melanoma [Figures 1 and 2].

The patient underwent right total maxillectomy with right orbital exenteration and the bony margin was involved by tumor. Adjuvant radiotherapy of 60 Gy in 6 weeks was delivered. Unfortunately, 4 months after the completion of

treatment, the patient developed recurrent right submandibular lymphnode, bilateral lung metastasis along with nodular lesions in retroperitoneal and right infrarenal region. The patient was started on palliative chemotherapy (paclitaxel + carboplatin). After three cycles of chemotherapy, contrast-enhanced CT scan (CECT) showed all the retroperitoneal and infrarenal lesions had regressed completely, whereas there was a partial reduction in the right submandibular lymphnode and lung metastasis. In view of the good response, the patient was given three more cycles of the same chemotherapy regimen. After 1 month, the follow-up CECT scan showed residual right submandibular lymph node and persisting bilateral lung metastasis. The patient was put on Tablet Sorafenib. Due to toxicity, she was shifted to an alternative chemotherapy regimen (dacarbazine + cisplatin). After three cycles, positron-emission tomography (PET-CT scan) showed the persistence of the previous disease and an appearance of new metastatic involving right iliac bone for which the patient received palliative radiotherapy. At present, the patient is put on tablet Imatinib and has a stable disease condition until the last follow-up.

A 43-year-old male presented with complaint of blackish mass in the right buccal mucosa. The biopsy from this lesion confirmed melanocarcinoma. He underwent inferior partial maxillectomy, and the postoperative histopathology showed malignant melanoma. All margins were uninvolved by tumor

(Continue on page 30...)

(Letter to the editor continue from page 26...)

with no perineural invasion or lymphovascular invasion [Figure 3].

The patient received immunotherapy as adjuvant treatment. However, after 3 months of disease-free interval, the patient had regional recurrence in right level II lymphnode confirmed by fine-needle aspiration cytology (FNAC) and PET-CT scan [Figure 4]. The patient underwent bilateral modified radical neck dissection.

Following which the patient received radiotherapy of 60 Gy in 6 weeks. The patient had no evidence of disease until last follow-up.

A 62-year-old male presented with complaints of Left nasal blockage, protruding Left nasal mass covering the whole of the Left nasal cavity and swelling in the Left side of the hard palate. The CECT-scan showed a locally advanced lesion in the Left nasal cavity, Left maxillary cavity which was extending to the oral cavity along with liver and lung metastasis. The biopsy and immunohistochemical of nasal mass confirmed the diagnosis of malignant mucosal melanoma [Figures 5 and 6].

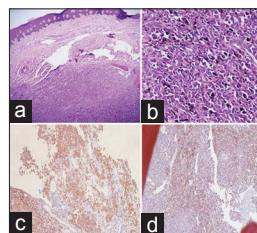
The patient was treated with palliative chemotherapy (dacarbazine, cisplatin, and vinblastine X six cycles). Later, he received palliative radiotherapy for epistaxis. At the last follow-up, the patient had no bleeding from the local site and had a stable disease.

The patient was treated with palliative chemotherapy (dacarbazine, cisplatin, and vinblastine X six cycles). Later, he received palliative radiotherapy for epistaxis. At the last follow-up, patient had no bleeding from the local site and had stable disease.

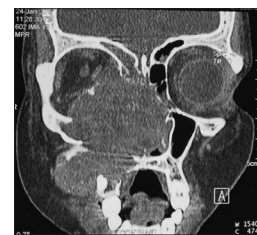A 68-year-old female presented with complaints of bulging of the left eye with occasional bleeding from the left eye. CT-scan showed an intraorbital mass on the posterolateral wall of the left orbit. She underwent left orbital exenteration, and the postoperative histopathology confirmed the diagnosis of malignant melanoma of the eye. Neck dissection was planned, but the patient was lost to follow-up [Table 1].

In western studies,<sup>[2,4]</sup> the mean age was 65–70 years. In an Indian study,<sup>[3]</sup> mean age was 53 years which was similar to our series (49.7 years). The majority of mucosal melanoma arises in the sinonasal and oral cavity<sup>[2,3]</sup> which correlates with our study. According to Szabo,<sup>[5]</sup> this is mainly due to the high density of melanocytes in these regions.

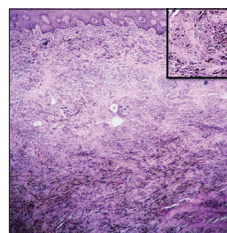
According to many studies,<sup>[2,6,7]</sup> the female patients were relatively younger and had a better prognosis. The female patient in our series is the youngest. Nasal obstruction,



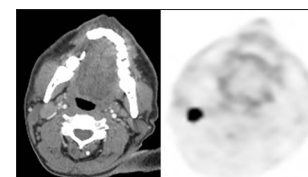
**Figure 1: (a) Stratified squamous epithelium lined tissue with underlying diffuse sheets of epithelioid melanocytes along with brownish-black pigment (H and E). (b) Individual tumour cells showing clear cytoplasm and pleomorphic vesicular nuclei with prominent nucleoli (H and E). (c) HMB 45 expression. (d) Melan-A positivity**



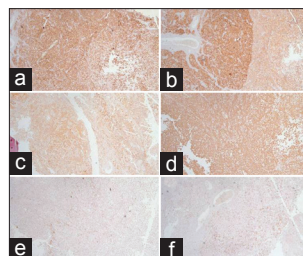
**Figure 2: Computed tomography-scan reconstructed saggital view**



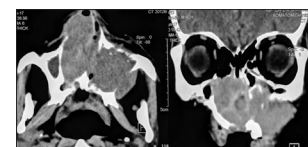
**Figure 3: Stratified squamous epithelium lined tissue with underlying sheets of epithelioid melanocytes arranged in an organoid pattern and fascicles of spindled melanocytes along with brownish-black pigment. Inset-epithelioid melanocytes showing indistinct cytoplasmic borders and pleomorphic vesicular nuclei with prominent nucleoli**



**Figure 4: Computed tomography-scan and positron emission tomography scan showing right level II lymphnode involvement**



**Figure 5: (a) Diffuse positivity for HMB 45. (b) Diffuse positivity for Melan A. (c) Diffuse positivity for S 100. (d) Vimentin expression by tumour cells. (e) Negative staining for CK 20 and (f) negative staining for synaptophysin**



**Figure 6: Computed tomography-scan (axial and reconstructed saggital view) showing a large sino-nasal mass**

and epistaxis were the most common symptoms in our sinonasal melanoma patients which is similar to a study by Meleti *et al.*<sup>[6]</sup>

(Continue on page 34...)

(Letter to the editor continue from page 30...)

**Table 1: Summarised Observations**

Characteristic	n
Sex	
Male	2
Female	2
Site	
Sino-Nasal	2
Buccal mucosa	1
Orbit	1
Extent	
Localized	3
Metastatic	1
Treatment	
Surgery	3
Immunotherapy	1
Chemotherapy	2
Radiotherapy	3

According to Bakkal *et al.*,<sup>[8]</sup> the local, regional, and systemic recurrences were 20%, 50%, and 80%, respectively, and all patients with metastasis had lung involvement. Two of our patients who had metastatic disease had lung involvement, and one had developed regional recurrence. As surgery is the primary modality of treatment,<sup>[9]</sup> three of our patients who had localized disease underwent surgery.

Mendenhall *et al.*<sup>[9]</sup> stated that the radiation could reduce local recurrence but has no survival benefit. One of our patients who underwent adjuvant radiotherapy had developed distant metastasis after 3 months of disease-free survival (DFS). Another patient who received immunotherapy as adjuvant treatment developed regional recurrence after 3 months of DFS.

As noted by various studies,<sup>[6,10]</sup> our experience with these patients showed that the outcome was not affected by treatment modality chosen. With the use of hypofractionation schedules and newer treatment delivery techniques, radiotherapy presently improves loco-regional control<sup>[7,11]</sup> in malignant melanoma which was once thought to be radio-resistant.<sup>[12]</sup> However, larger case series and longer follow-up are required to bring further light to this topic.

#### Declaration of patient consent

The authors certify that they have obtained all appropriate

patient consent forms. In the form the patient(s) has/have given his/her/their consent for his/her/their images and other clinical information to be reported in the journal. The patients understand that their names and initials will not be published and due efforts will be made to conceal their identity, but anonymity cannot be guaranteed.

#### Acknowledgment

We would like to show our gratitude to our departmental staff and colleagues, especially Dr. Nighat Hussain, Additional Professor and Dr. Vandita Singh, Assistant Professor from the Department of Pathology, All India Institute of Medical Sciences, Raipur, for their assistance in preparation in the manuscript.

#### Financial support and sponsorship

Nil.

#### Conflicts of interest

There are no conflicts of interest.

**Mathumitha Ramesh, Siddhartha Nanda, Biplab Misra**

Department of Radiotherapy, All India Institute of Medical Sciences, Raipur, Chhattisgarh, India

Correspondence to: Dr. Siddhartha Nanda,  
E-mail: sidnanda@yahoo.com

#### References

1. Weber CO. Surgical Experience and Research, in Addition to Interesting Observations from the Surgical Clinic and the Protestant Hospital Bonn. Berlin, Germany: Reimer G; 1859. p. 304-5.
2. Bachar G, Loh KS, O'Sullivan B, Goldstein D, Wood S, Brown D, *et al.* Mucosal melanomas of the head and neck: Experience of the princess Margaret hospital. *Head Neck* 2008;30:1325-31.
3. Gupta T, Agarwal J, Singh S, Ghosh-Laskar S, Chaturvedi P, Kane S, *et al.* Mucosal melanoma of the head and neck: Tata memorial hospital experience. *Int J Head Neck Surg* 2010;1(3):141-5.
4. Manolidis S, Donald PJ. Malignant mucosal melanoma of the head and neck: Review of the literature and report of 14 patients. *Cancer* 1997;80:1373-86.
5. Szabo G. The number of melanocytes in human epidermis. *Br Med J* 1954;1:1016-7.
6. Meleti M, Leemans CR, de Bree R, Vescovi P, Sesenna E, van der Waal I, *et al.* Head and neck mucosal melanoma: Experience with 42 patients, with emphasis on the role of postoperative radiotherapy. *Head Neck* 2008;30:1543-51.
7. Wada H, Nemoto K, Ogawa Y, Hareyama M, Yoshida H, Takamura A, *et al.* A multi-institutional retrospective analysis of external radiotherapy for mucosal melanoma of the head and neck in Northern Japan. *Int J Radiat Oncol Biol Phys* 2004;59:495-500.

(Continue on page 40...)

*(Letter to the editor continue from page 34...)*

8. Bakkal FK, Başman A, Kızıl Y, Ekinci Ö, Gümüşok M, Ekrem Zorlu M, *et al.* Mucosal melanoma of the head and neck: Recurrence characteristics and survival outcomes. *Oral Surg Oral Med Oral Pathol Oral Radiol* 2015;120:575-80.
9. Mendenhall WM, Amdur RJ, Hinerman RW, Werning JW, Villaret DB, Mendenhall NP, *et al.* Head and neck mucosal melanoma. *Am J Clin Oncol* 2005;28:626-30.
10. Gaze MN, Kerr GR, Smyth JF. Mucosal melanomas of the head and neck: The Scottish experience. The Scottish melanoma group. *Clin Oncol (R Coll Radiol)* 1990;2:277-83.
11. Ballo MT, Ang KK. Radiation therapy for malignant melanoma. *Surg Clin North Am* 2003;83:323-42.
12. Paterson R. Classification of tumors in relation to radiosensitivity. *Br J Radiol* 1933;6:218-33.

---

This is an open access journal, and articles are distributed under the terms of the Creative Commons Attribution-NonCommercial-ShareAlike 4.0 License, which allows others to remix, tweak, and build upon the work non-commercially, as long as appropriate credit is given and the new creations are licensed under the identical terms.

**How to cite this article:** Ramesh M, Nanda S, Misra B. Mucosal melanoma of the head-and-neck region: A single institutional clinical experience. *South Asian J Cancer* 2019;8:26-40.

© 2018 The South Asian Journal of Cancer | Published by Wolters Kluwer - Medknow