

# Retinoblastoma: A retrospective analysis of 141 patients from 1983 to 2013 at a tertiary care hospital in Nagpur, India

Rohit S. Kabre, Krishna M. Kamble<sup>1</sup>

## Abstract

**Purpose:** There is scarcity of data regarding clinical presentation and outcome of retinoblastoma patients in India. **Objectives:** The objective of this study was to assess the clinical profile of retinoblastoma patients in a tertiary care hospital in India from 1983 to 2013. **Subjects and Methods:** A retrospective analysis of clinical records of 141 patients with retinoblastoma registered from 1983 to 2013 at Government Medical College, Nagpur, India, was conducted. Demographics, clinical features, modes of treatment, and outcome of the patients were assessed. **Results:** Majority of patients (81 [57.45%]) presented in the age group of 1–3 years and were males. One hundred and fourteen patients (80.85%) had unilateral disease, while rare presentations of trilateral/quadrilateral retinoblastoma were also noted. Proptosis was seen in 81 (57.45%) patients as presenting symptom. Eighty-nine patients (63.12%) had locally invasive disease-involving sites. Forty-four patients (31.19%) developed distant metastasis. Surgical management and external beam radiotherapy were followed in majority of patients. Trend of increased usage of chemotherapy was seen from the mid-1990s. One hundred and twelve patients (79.43%) died with the disease. **Conclusions:** Data from this study show late diagnosis, leading to poor outcome for patients with advanced retinoblastoma, which is in accordance with data from other developing countries. Even though management of patients changed in accordance with changing standard of care over the decade, mortality remained high.

**Key words:** Advanced stage, changing trend, retinoblastoma

## Introduction

Retinoblastoma is the most frequent childhood intraocular tumor with a global incidence of 1:20,000 births.<sup>[1]</sup> Global incidence data for retinoblastoma show an approximate 50-fold variation, which is highly atypical for a pediatric tumor. Incidence of Retinoblastoma on a global scale is 11/ million children in 5 years and younger age group. In India, incidence rate stands at 0.6 cases per 100,000 children. Nagpur Cancer Registry reports a prevalence of 0.1/100,000 population. Management of retinoblastoma has changed during years with a survival rate of >95% in developed countries.<sup>[2,3]</sup> However, in developing countries, cure rates of <50% are observed, primarily because of advanced disease at the time of diagnosis.<sup>[4–6]</sup> Data detailing the clinical presentation and treatment outcomes of retinoblastoma, especially in Indian settings, are scarce, and hence, this study was undertaken to assess the clinical profile of patients with retinoblastoma.

## Subjects and Methods

A retrospective cohort study was conducted by reviewing clinical records of all retinoblastoma patients ( $n = 141$ ) registered from 1983 to 2013 at Government Medical College and Hospital, Nagpur, India. The Institutional Ethics Committee approval was obtained. The diagnosis of retinoblastoma was based on history and physical examination with complete ocular examination. Demographics, clinical presentation, follow-up examinations, and outcome of the patients were noted.

## Results

One hundred and sixty-two eyes in 141 patients were diagnosed with retinoblastoma. Numbers of patients recorded during the first decade (1982–1993), second decade (1994–2003), and third decade (2004–2013) were 72, 44, and 25, respectively. The mean follow-up of all patients was 112 days (0–791).

Clinical profile of the patients has been described in Table 1. Figure 1 shows appreciable change in trends during the management of retinoblastoma patient over three decades.

## Discussion

Retinoblastoma is a rare disease of early childhood. Due to extremely low incidence, the features of retinoblastoma patients are not routinely assessed. In developing countries such as India, it is important to identify the clinical features on presentation and complications of these patients. Data from developed countries and urban treatment centers in India show leukocoria (white eye) as a leading presenting symptom (early diagnosis) along with excellent survival status with the highest level of quality of life. The present study shows data in sync with data from developing countries with respect to late diagnosis, advanced stage at presentation & poor outcomes/loss of follow up.<sup>[7–11]</sup> Presentation for late cases varies from proptosis to fungating mass with secondaries.<sup>[12]</sup> Presentation of proptosis in majority of cases can be attributed to the delay in seeking consultation by the patient.<sup>[13]</sup> Extraocular retinoblastoma is very rare in developed countries (2%–5%).<sup>[14]</sup> In developing nations, extraocular disease contributes to half of all retinoblastoma cases presenting to a tertiary care referral center, which is in accordance with the findings of this study.<sup>[15,16]</sup>

Reese–Ellsworth grading, formulated in 1960, has been widely used to predict the outcome of retinoblastoma treated with external beam radiotherapy (EBRT); however, as chemotherapy gradually replaced radiotherapy, new staging system was developed to predict the outcome for eyes treated with chemotherapy and focal treatments, which were international intraocular retinoblastoma. Majority of cases presented in an advanced stage. These findings were in accordance with data from other developing nations.<sup>[7,10,11]</sup>

This is an open access journal, and articles are distributed under the terms of the Creative Commons Attribution-NonCommercial-ShareAlike 4.0 License, which allows others to remix, tweak, and build upon the work non-commercially, as long as appropriate credit is given and the new creations are licensed under the identical terms.

**For reprints contact:** reprints@medknow.com

**How to cite this article:** Kabre RS, Kamble KM. Retinoblastoma: A retrospective analysis of 141 patients from 1983 to 2013 at a tertiary care hospital in Nagpur, India. *South Asian J Cancer* 2019;8:195–7.

Access this article online

Quick Response Code:



Website: www.sajc.org

DOI: 10.4103/sajc.sajc\_314\_18

Department of Radiation Oncology, P.D. Hinduja Hospital, Mumbai, <sup>1</sup>Department of Radiation Therapy and Oncology, Government Medical College and Hospital, Nagpur, Maharashtra, India  
**Correspondence to:** Dr. Rohit S. Kabre,  
 E-mail: rohitkabre1986@gmail.com

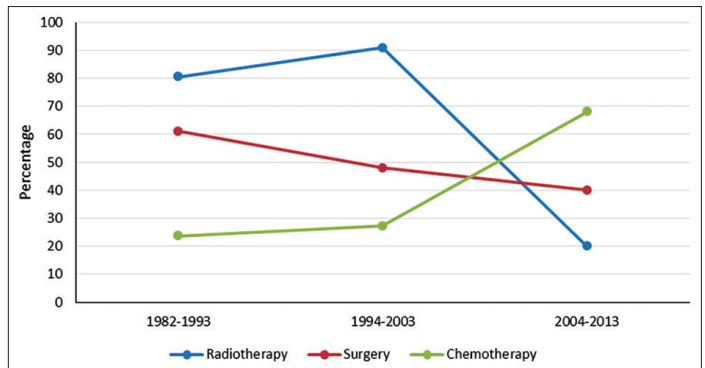
**Table 1: Demographics and clinical profile (n=141 patients)**

Variables	Frequency, n (%)
<b>Age at diagnosis (years)</b>	
<1	2 (1.5)
1-3	81 (57.5)
>3	58 (41.1)
<b>Gender distribution</b>	
Males	81 (57.5)
Females	60 (42.5)
<b>Laterality</b>	
Unilateral	114 (80.9)
Bilateral	24 (17)
Trilateral	2 (1.4)
Quadrilateral	1 (0.7)
<b>Presenting signs and symptoms</b>	
White eye	36 (25.5)
Orbital swelling/proptosis	81 (57.5)
Painful eye	10 (7.1)
Loss of vision	12 (8.5)
Squint	2 (1.4)
<b>Complications</b>	
Calcification	45 (31.9)
Retinal hemorrhage	15 (10.6)
Vitreous seeding	1 (0.7)
Retinal detachment	7 (5)
Other*	73 (51.8)
<b>Presence of local invasion</b>	
Optic nerve and soft-tissue involvement	36 (25.5)
Multiple site involvement	12 (8.5)
Bone erosion	4 (2.8)
No local invasion	52 (36.9)
<b>Distant metastasis</b>	
Extracranial	26 (18.4)
Intracranial	16 (11.3)
Both intracranial and extracranial	2 (1.4)
<b>Grouping as per Reese-Ellsworth classification (n=139)</b>	
1	4 (2.9)
2	8 (5.8)
3	23 (16.6)
4	14 (10.1)
5	90 (64.8)
<b>Grouping as per the International Classification of Retinoblastoma (n=139)</b>	
A	3 (2.2)
B	13 (9.4)
C	14 (10.1)
D	24 (17.3)
E	85 (61.2)
<b>Mode of treatment#</b>	
<b>Surgical</b>	
Enucleation	65 (46.1)
Exenteration	9 (6.4)
Craniotomy and excision	1 (0.7)
<b>Nonsurgical</b>	
Adjuvant/neoadjuvant chemotherapy#	46 (32.6)
<b>Radiotherapy</b>	
Radical intent	29 (20.6)
Adjuvant (postoperative)	46 (32.6)
Palliation (due to metastasis)	28 (19.9)

**Table 1: Contd...**

Variables	Frequency, n (%)
<b>Outcome after therapy</b>	
Recurrence	54 (38.3)
Disease free at the last follow-up	43 (30.5)
Unknown (lost for follow-up)	44 (31.2)
<b>Outcome on long-term follow-up</b>	
Mortality	112 (79.43)
Alive without disease	13 (9.21)
Lost for follow-up	16 (11.3)

\*Perforation of globe, staphyloma, raised ICT, raised IOT, fungating growth, lymphadenopathy. #All patients, except one, received VAC regimen of chemotherapy. VAC=Vincristine, adriamycin, cyclophosphamide, ICT=Intra-cranial tension, IOT=Intra-ocular tension



**Figure 1: Trends in the management of retinoblastoma over the years. Data expressed in percentages. Over the years, an increase in chemotherapeutic approach as treatment of choice, slight decrease in surgical approach and sharp decrease in radiotherapy approach have been observed in the management of retinoblastoma**

**Twinning is Winning**

- Institutions in developed countries mentor programs in countries with limited resources to develop paediatric cancer units.
- Facilitate alliances among private-sector institutions & NGO's
- Use of telemedicine(Orbis Cyber-Sight e-consultation)

**Public Health Campaign**

- Education of lay population, teachers, and health care providers
- Awareness campaign linked to an immunization campaign
- Flyers and posters distribution on specific days

**Long Term Goals**

- Development of a National Retinoblastoma Program.
- Disease-specific network for providing a framework for rational referrals.
- Regional centers of reference can be developed.
- National Retinoblastoma Registry.

**Figure 2: Recommendations for improving management of retinoblastoma in developing countries**

Surgical management and EBRT are considered standard treatment protocol for eyes with advanced stage. Resource deficiency, unavailability, and cost of drugs till 1990s precluded the use of chemotherapy in majority of patients in this study. However, with changing guidelines and availability of standard drugs, number of patients receiving chemotherapy increased appreciably, coinciding with decrease in patient being treated with surgery and EBRT, which has been observed in Figure 1. EBRT was the only alternative to enucleation until the mid-1990s and is still an option to treat large tumors.<sup>[17]</sup> Scarce supply of ketamine till 1990s as anesthetic agent used

for immobilizing pediatric patients before radiation therapy session prompted use of hypofractionated RT, which enabled treatment to be completed in less duration. Dose prescribed in patients treated with radical intent was 36 Gy/9 fractions in 2–3 weeks, which was equivalent to conventional 50 Gy/5 times per week fractionation.<sup>[18]</sup>

Treatment abandonment as well as loss to follow-up has also been reported from other developing countries,<sup>[10,19,20]</sup> which could be attributed to no response/progressive disease in an advanced stage, inability to accept enucleation as form of treatment, inability to cope up with frequency of follow-up, illiteracy, poverty, and negligence.

To unearth grim situation, specifically in India, as per one retinoblastoma world statistical analysis, China recorded 1095 retinoblastoma patients in 2013 in 28 established Retinoblastoma Treatment Centers (RTB), while Pakistan showed 312 patients in 6 RTBs, while in India, 1730 patients took treatment in 11 RTBs. Various approaches for improvement in the management of retinoblastoma in developing countries<sup>[19]</sup> have been summarized in Figure 2.

### Conclusions

Data from this study show late diagnosis, leading to poor outcome for patients with advanced retinoblastoma, which is in accordance with data from other developing countries. Even though management of patients changed in accordance with changing standard of care over the decade, mortality remained high. Inequality in patient access to health care is the reality in India. This study underlines this well-known fact and brings forth strategies which can lead to improvement of this scenario.

### Financial support and sponsorship

Nil.

### Conflicts of interest

There are no conflicts of interest.

### References

- Shields JA, Shields CL. Retinoblastoma in Intraocular Tumors – A Text and Atlas. 2<sup>nd</sup> ed. Philadelphia, USA: Lippincott Williams and Wilkins; 2007. p. 294-318.
- Berman EL, Donaldson CE, Giblin M, Martin FJ. Outcomes in retinoblastoma, 1974-2005: The children's hospital, Westmead. Clin Exp Ophthalmol 2007;35:5-12.
- MacCarthy A, Birch JM, Draper GJ, Hungerford JL, Kingston JE, Kroll ME, *et al.* Retinoblastoma in Great Britain 1963-2002. Br J Ophthalmol 2009;93:33-7.
- Bowman RJ, Mafwiri M, Luthert P, Luande J, Wood M. Outcome of retinoblastoma in east Africa. Pediatr Blood Cancer 2008;50:160-2.
- Bhurgri Y, Muzaffar S, Ahmed R, Ahmed N, Bhurgri H, Usman A, *et al.* Retinoblastoma in Karachi, Pakistan. Asian Pac J Cancer Prev 2004;5:159-63.
- de Camargo B, de Oliveira Santos M, Rebelo MS, de Souza Reis R, Ferman S, Noronha CP, *et al.* Cancer incidence among children and adolescents in Brazil: First report of 14 population-based cancer registries. Int J Cancer 2010;126:715-20.
- Kaimbo DK, Kilangalanga J, Missotten L. Exophthalmias in zaire. Bull Soc Belge Ophtalmol 1995;259:199-204.
- Kaimbo WK, Mvitu MM, Missotten L. Presenting signs of retinoblastoma in Congolese patients. Bull Soc Belge Ophtalmol 2002;283:37-41.
- Kayembe L. Retinoblastoma: 21-year review. J Fr Ophtalmol 1986;9:561-5.
- Bekibebe CO, Ayede AI, Asaolu OO, Brown BJ. Retinoblastoma: The challenges of management in Ibadan, Nigeria. J Pediatr Hematol Oncol 2009;31:552-5.
- Kivelä T. Trilateral retinoblastoma: A meta-analysis of hereditary retinoblastoma associated with primary ectopic intracranial retinoblastoma. J Clin Oncol 1999;17:1829-37.
- Du W, Pogoriler J. Retinoblastoma family genes. Oncogene 2006;25:5190-200.
- Antoneli CB, Steinhorst F, Ribeiro Kde C, Chojniak MM, Novaes PE, Arias V, *et al.* The pediatrician's ability to recognize the presenting signs and symptoms of retinoblastoma. Rev Assoc Med Bras (1992) 2004;50:400-2.
- Jubran RF, Erdreich-Epstein A, Butturini A, Murphree AL, Villablanca JG. Approaches to treatment for extraocular retinoblastoma: Children's hospital Los Angeles experience. J Pediatr Hematol Oncol 2004;26:31-4.
- Kanski JJ 2<sup>nd</sup>. Clinical Ophthalmology – A Systematic Approach. Oxford: Butterworth-Heinemann; 1992. p. 401-5.
- Bakhshi S, Bakhshi R. Genetics and management of retinoblastoma. J Indian Assoc Pediatr Surg 2007;12:109-11.
- Abramson DH, Beaverson KL, Chang ST, Dunkel IJ, McCormick B. Outcome following initial external beam radiotherapy in patients with Reese-Ellsworth group Vb retinoblastoma. Arch Ophthalmol 2004;122:1316-23.
- Fletcher GH 3<sup>rd</sup>. Textbook of Radiotherapy. Philadelphia: Lea & Febiger; 1980. p. 504.
- Ali AA, Elsheikh SM, Elhaj A, Osman N, Abuidris D, Eltayeb EA, *et al.* Clinical presentation and outcome of retinoblastoma among children treated at the national cancer institute (NCI) in Gezira, Sudan: A single institution experience. Ophthalmic Genet 2011;32:122-5.
- Mukhtar AU, Kagame K. Pathological study of retinoblastoma in Mbarara, Uganda. Cent Afr J Med 2000;46:13-6.