

# Correlation of digital mammography and digital breast tomosynthesis features of self-detected breast cancers with human epidermal growth factor receptor type 2/neu status

Chaitra Sonthineni, Namita Mohindra<sup>1</sup>, Vinita Agrawal<sup>2</sup>, Zafar Neyaz<sup>1</sup>, Neeraj Jain<sup>1</sup>, Sabaretnam Mayilvagnan, Gaurav Agarwal

## Abstract

**Context:** Breast cancer is a heterogeneous disease with several histological subtypes. Its prognosis and management are influenced by human epidermal growth factor receptor type 2 (HER2/neu) expression. Varying grades of HER2/neu overexpression are likely to have different morphological features. Digital breast tomosynthesis (DBT) enhances lesion visibility and hence that it may reveal features closer to histomorphological findings. **Aims:** The aim of this study is to correlate digital mammography (DM) and DBT findings of self-detected tumors with HER2/neu status, to determine whether differences in imaging features can help predict the degrees of HER2/neu overexpression. **Settings and Design:** Prospective study conducted in a tertiary care hospital. **Methods:** For 100 consecutive patients with self-detected lumps, DM and DBT data were reviewed by two radiologists who were blinded to histopathology. Of these, 63 patients with histologically proven breast cancer were recruited and their DM and DBT findings compared and correlated with HER2/neu status (scores 0–3+). **Statistical Analysis:** Pearson's Chi-squared test and Fisher's exact test were used (SPSS version 22.0, IBM). **Results:** Morphology of lesions at both DM and DBT varied with HER2/neu status ( $P = 0.04$  and  $0.015$ , respectively). HER2-0 tumors mostly presented as masses without microcalcifications (88.8%), while most of HER2-3+ tumors as masses or asymmetries with microcalcifications (61.9%). The presence or absence of calcifications varied significantly with HER2/neu status. Breast imaging-reporting and data system (BI-RADS) scoring varied significantly ( $P < 0.001$ ) with higher HER2 signal, more frequently associated with BI-RADS 5 score. **Conclusion:** DM and DBT features vary with the intensity of HER2 immunostaining. Higher BI-RADS scores, microcalcifications, and spiculated margins are frequently associated with HER2/neu 3+ lesions.

**Key words:** Breast carcinoma, digital breast tomosynthesis, digital mammography, human epidermal growth factor receptor type 2/neu, immunohistochemistry

## Introduction

In India, self-detected breast lumps are the most common presentation of breast cancer.<sup>[1]</sup> The prognosis and management is influenced by several factors, including the level of expression of human epidermal growth factor receptor type 2 (HER2/neu) gene; overexpression of which is reported in 15%–25% of cases in the west<sup>[2]</sup> and in up to 46.3% of cases in India.<sup>[3]</sup>

HER2/neu overexpression is associated with higher cell proliferation and more neoangiogenesis,<sup>[4]</sup> leading to more aggressive tumors which may have distinct macroscopic and imaging features.<sup>[5]</sup> Identification of these could improve our understanding of biological behavior and guide management. Digital mammography (DM) is the mainstay of imaging and digital breast tomosynthesis (DBT) helps in better lesion characterization, by reducing the masking effect of overlapping tissues.<sup>[6,7]</sup>

We hypothesized that the imaging features on DM and DBT would correlate with the degree of HER2/neu expression.

## Methods

### Patient population

This study included consecutive patients with self-detected breast lumps who underwent breast imaging during the period from January 2016 to October 2016. Their DM and DBT images were saved and were reevaluated specifically for this study separately by two radiologists who were unaware of the cytopathology and/or histopathology findings and the original mammography report. Any patients who had had a breast intervention (e.g., core, incisional, or excisional biopsy) before

DM, had a benign breast disease at histology or in whom Immuno-histochemistry (IHC) was inadequate were excluded from the study.

### Image acquisition

DM and DBT of each side were acquired using Hologic Selenia Dimensions mammographic equipment (Hologic Inc., USA) using “combo-mode” in craniocaudal and mediolateral oblique projections, during the same breast compression. Total time taken for acquisition of DBT view on each side was approximately 3 s and mean radiation dose for a single breast view in combo-mode was about 1.45 mGy. The images were reviewed using a mammographic workstation (Securview, Hologic) that included two Barco 5.0-megapixel monitors.

### Mammogram analysis

Mammograms were evaluated according to the American College of Radiology Breast Imaging Reporting and Data System (BI-RADS) 5<sup>th</sup> edition (2013) lexicon.<sup>[8]</sup> In each case, bilateral scans were reviewed by two radiologists with 7 and 10 years' experience in breast imaging, respectively. Reporting was done in two sessions by each radiologist; the initial session included recording of breast composition, lesion location, morphological type, and margins on DM alone. The categorization of morphological type was one of the following: predominant mass ± calcification; asymmetry ± calcification; architectural distortion; or calcification cluster alone (without mass, asymmetry or distortion).

In the second session, DBT findings were added to DM and recording of morphological type, location, and margins of the

This is an open access journal, and articles are distributed under the terms of the Creative Commons Attribution-NonCommercial-ShareAlike 4.0 License, which allows others to remix, tweak, and build upon the work non-commercially, as long as appropriate credit is given and the new creations are licensed under the identical terms.

**For reprints contact:** reprints@medknow.com

**How to cite this article:** Sonthineni C, Mohindra N, Agrawal V, Neyaz Z, Jain N, Mayilvagnan S, et al. Correlation of digital mammography and digital breast tomosynthesis features of self-detected breast cancers with human epidermal growth factor receptor type 2/neu status. South Asian J Cancer 2019;8:140-4.

### Access this article online

#### Quick Response Code:



Website: www.sajc.org

DOI: 10.4103/sajc.sajc\_300\_18

Departments of Endocrine and Breast Surgery, <sup>1</sup>Radio-Diagnosis and <sup>2</sup>Pathology, Sanjay Gandhi Postgraduate Institute of Medical Sciences, Lucknow, Uttar Pradesh, India

**Correspondence to:** Dr. Namita Mohindra, E-mail: mehrotranamita897@gmail.com

lesion was done. A mammographic view on either DM or DBT showing maximum lesion size was chosen for measurement of diameter. A time interval of >2 weeks was kept between the two reading sessions. In cases of the disparity between reviewers, a consensus opinion was obtained.

### Immunohistochemistry analysis

For each patient, paraffin sections (4–6-µm thick) of excision specimens were assessed for HER2/neu expression using rabbit anti-human c-erbB2 oncoprotein (SP3, Dako, Denmark) after heat-induced epitope retrieval. Polymer-based technique with DAB as chromogen was employed for detection of the bound antibody (Ultra Vision Quanto HRP and DAB, Thermo Fisher Scientific). The HER2/neu expression was scored according to the ASCO 2013 HER2 test guidelines for immunohistochemical expression as 0-3+ for breast cancers. A tumor was scored as 3+ if an intense complete circumferential membrane staining was observed in >10% cells. A score of 2+ was awarded for incomplete membrane and/or weak/moderate circumferential membrane expression in >10% of invasive tumor cells or intense complete circumferential membrane staining in ≤10% of cells. A tumor was scored as 1+ when faint/barely perceptible incomplete membrane staining was noted in >10% of the invasive tumor cells. A tumor was scored as “0” when no staining was observed or it showed faint/barely perceptible incomplete membrane staining noted in ≤10% of the invasive tumor cells.

### Data analysis

Relationship of DM and DBT findings with HER2/neu status was assessed using the Pearson's Chi-squared test; if one or more cells in the contingency tables had values less or equal to five, Fisher's exact test was used. Analyses were performed using Statistical Package for Social Sciences

software, version 22 (SPSS-22, IBM, Chicago, IL, USA). Values of  $P < 0.05$  were considered as statistically significant.

The study was approved by our Institutional ethics committee, and all the patients provided informed consent.

### Results

Of the 100 women originally enrolled, 37 were excluded because they had a benign disease ( $n = 20$ ), had undergone a prior lumpectomy ( $n = 10$ ) or incision/excision biopsy ( $n = 5$ ), or did not undergo IHC ( $n = 2$ ). The mean age of the remaining 63 patients, whose data were analyzed, was  $49.4 \pm 10.6$  years. There was no relation of age with HER2/neu status ( $P = 0.623$ ).

Of the 63 cases analyzed, 18 had HER2/neu 0 status, 13 cases were HER2/neu 1+, and 11 were HER2/neu 2+ and 21 had HER2/neu 3+ status. There were 11 triple negative breast cancers (TNBC) with HER2-0 score.

On DM alone, predominant finding was seen as asymmetry in 12 of the 63 patients, and adjunct DBT was able to reveal underlying masses in 9, thus significantly improving the lesion visibility [Figure 1].

Sixteen of the 18 HER2/neu 0 cases were seen as mass without calcification, whereas only 2 appeared as mass with calcification on both DM and adjunct DBT [Figure 2 and Table 1].

7/13 HER2/neu 1+ cases were seen as mass, 3 as asymmetry, 3 as mass with calcification on DM alone. On adjunct DBT underlying masses were revealed in all 3 cases seen as asymmetry and faint amorphous calcification was noted in one of them. Hence 9/13 cases were seen as mass and 4 as mass with calcification [Figure 3 and Table 1].

5/11 HER2/neu 2+ cases were seen as mass, 3 as asymmetry, 3 as mass with calcification on DM alone. On adjunct DBT underlying

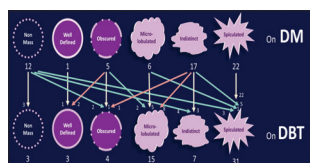**Table 1: Lesion morphology and human epidermal growth factor receptor type 2 status on digital mammography and digital breast tomosynthesis**

	HER2/neu status				P
	0 ( $n=18$ ), $n$ (%)	1+ ( $n=13$ ), $n$ (%)	2+ ( $n=11$ ), $n$ (%)	3+ ( $n=21$ ), $n$ (%)	
DM					
Mass	16 (89)	7 (54)	5 (45)	6 (29)	0.04
Asymmetry	0	3 (23)	3 (27)	2 (10)	
Mass with calcification	2 (11)	3 (23)	3 (27)	9 (43)	
Asymmetry with calcification	0	0	0	4 (19)	
DBT					
Mass	16 (89)	9 (69)	6 (55)	7 (33)	0.015
Asymmetry	0	0	1 (9)	1 (5)	
Mass with calcification	2 (11)	4 (31)	4 (36)	12 (57)	
Asymmetry with calcification	0	0	0	1 (5)	
Overall lesions with calcification	2 (11)	4 (31)	4 (36)	13 (62)	0.011
Overall lesions without calcification	16 (89)	9 (69)	7 (64)	8 (38)	
Lesion margins on DBT*				*	0.140
Well-defined	3 (17)	0	0	0	
Obscured	1 (6)	1 (8)	2 (18)	0	
Microlobulated	5 (28)	5 (39)	3 (27)	2 (10)	
Indistinct	2 (11)	2 (15)	0	3 (14)	
Spiculated	7 (39)	5 (39)	5 (45)	14 (67)	
BI-RADS score on DBT					0.004
4b	7 (39)	0	1 (9)	0	
4c	3 (17)	4 (31)	2 (18)	2 (10)	
5	8 (44)	9 (69)	8 (73)	19 (90)	

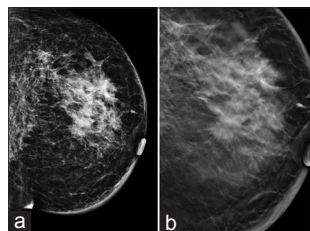
\*Only 19 of 21 HER2/neu 3+ lesions evaluated for margins excluding asymmetries. DM=Digital mammography, DBT=Digital breast tomosynthesis, HER2/neu=Human epidermal growth factor receptor type 2, BI-RADS=Breast Imaging Reporting and Data System

masses were revealed in 2 of 3 cases seen as asymmetry [Figures 4 and 5] and faint amorphous calcification was noted in one of them. 6/21 HER2/neu 3+ cases were seen as mass, 2 as asymmetry, 9 as mass with calcification and 4 as asymmetry with calcifications on DM alone. On adjunct DBT underlying masses were revealed in 1 of the 2 cases of asymmetry and 3 of 4 cases of asymmetry with calcifications [Figures 6-8].

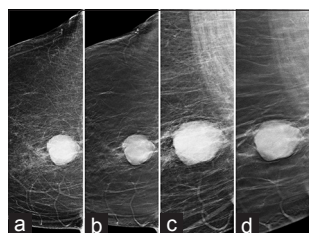
Lesion morphology varied with HER2/neu status significantly on both DM and DBT ( $P = 0.04$  vs.  $0.015$ , respectively). On DBT, HER2/neu 0 tumors mostly presented as a mass without microcalcifications (88.8%) whereas 61.9% HER2/neu 3+ tumors were masses or asymmetry with microcalcifications. All 11 TNBC with HER2-0 score, presented as masses without microcalcifications (lesion morphology –  $P = 0.014$ ). In our study, no case was seen as suspicious calcification alone as our study population consisted of patients presenting with self-detected masses. 13/21 (61.9%) HER2/neu 3+ cases were associated with microcalcifications, all of them being fine pleomorphic or fine linear branching type. 4/13 (30.7%) HER2/neu 1+ and 4/11 (36.4%) HER2/neu 2+ cases were associated with calcifications. These were mostly seen as few faint amorphous or punctate calcifications (in 6 of the 8 cases). The presence or absence of microcalcifications varied significantly with HER2/neu status [Table 1].



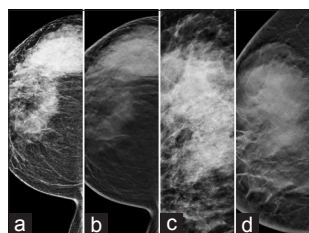
**Figure 1:** Effect of adjunct digital breast tomosynthesis on assessment of lesion morphology and margins



**Figure 5:** (Human epidermal growth factor receptor type 2/neu 2+). LMLO digital mammography (a) and digital breast tomosynthesis (b) images show global asymmetry with diffuse breast oedema on digital mammography. Digital breast tomosynthesis shows underlying spiculated mass with few punctate calcifications (Breast imaging-reporting and data system 5)



**Figure 2:** (Human epidermal growth factor receptor type 2/neu 0, triple negative breast cancers). Right cranio-caudal and right medio-lateral oblique (RCC and RMLO) views digital mammography (a and c) and digital breast tomosynthesis (b and d) images show a well-defined (~38 mm x 36 mm size) dense mass in retro-mammary area. No evidence of calcification (Breast imaging-reporting and data system 4 A)



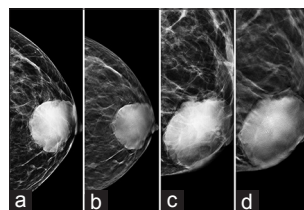
**Figure 6:** (Human epidermal growth factor receptor type 2/neu 3+). RCC and RMLO, digital mammography (a and c) and digital breast tomosynthesis (b and d) images show a large irregular dense mass with indistinct margins 74 mm x 62 mm size in upper outer breast with extensive fine pleomorphic and amorphous calcifications (breast imaging-reporting and data system 5)

Margins of mass did not vary significantly with HER2/neu scores on DM or DBT ( $P = 0.052$  vs.  $0.140$  respectively), the frequency of spiculated margins increased with increasing intensity of HER2/neu positivity [Table 1].

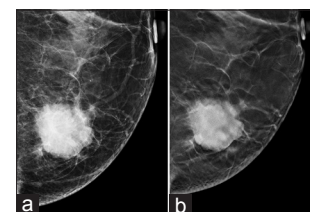
BI-RADS scores varied significantly on DBT ( $P = 0.004$ ), as more intense HER2/neu immunostaining was frequently assigned BI-RADS 5 score. 8/18 (44.5%) of HER2/neu 0 cases were scored as BI-RADS 5, whereas 19/21 (90.5%) HER2/neu 3+ cases were assigned BI-RADS 5 score. 7/18 (38.9%) HER2/neu 0 cases were assigned BI-RADS 4b score while none of HER2/neu 3+ cases were assigned a BI-RADS 4 b and only 2 (9.5%) were scored as 4c [Table 1].

## Discussion

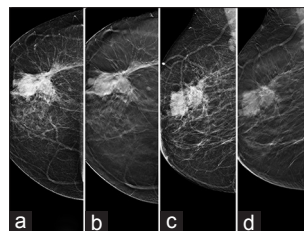
The advent of DBT has led to a significant improvement in the visibility of mammographic abnormalities due to the reduction of obscuring effects of overlapping tissue. The individual tomosynthesis slices are likely to reveal features of lesions closer to histomorphological correlates. In an effort to explore this potential, we undertook the study to analyze whether mammographic features differ with varying degrees of HER2/neu over-expression. The study showed that some mammographic features correlate with the intensity of HER2/neu immunostaining on IHC.



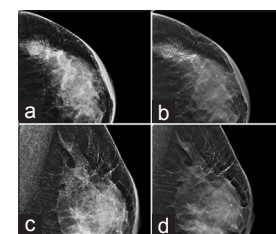
**Figure 3:** (Human epidermal growth factor receptor type 2/neu 1+). Left cranio-caudal and Left medio-lateral oblique (LCC and LMLO) views digital mammography (a and c) and digital breast tomosynthesis (b and d) images show a dense retroareolar microlobulated mass of 54 mm x 44 mm size with few specks of amorphous calcifications in it; better seen on digital breast tomosynthesis images (b and d) and focal thickening of overlying skin (Breast imaging-reporting and data system 4C)



**Figure 4:** (Human epidermal growth factor receptor type 2/neu 2+). LCC digital mammography (a) and digital breast tomosynthesis (b) images show a dense microlobulated mass of 33 mm x 32 mm size in lower inner quadrant with few punctate calcifications, better seen on digital breast tomosynthesis (b). (Breast imaging-reporting and data system 4B)



**Figure 7:** (Human epidermal growth factor receptor type 2/neu 3+). RCC and RMLO views, digital mammography (a and c) and digital breast tomosynthesis (b and d) images show an irregular dense mass with spiculations and fine linear calcifications. Associated smaller nodular components in surrounding parenchyma better seen on DBT. (breast imaging reporting and data system 5)



**Figure 8:** (Human epidermal growth factor receptor type 2/neu 3+) LCC and LMLO views, digital mammography (a and c) and digital breast tomosynthesis (b and d) images shows an irregular spiculated mass in upper outer quadrant with extensive fine linear and branching calcifications (breast imaging reporting and data system 5)



Adjunct DBT revealed underlying masses in a significant number of cases seen as asymmetries on DM alone, due to the reduction of the effect of superimposed soft tissue. Recent studies have observed that adjunct DBT improved characterization of malignant lesions by highlighting suspicious features.<sup>[9]</sup>

Various studies have shown that DBT is superior to diagnostic mammography, especially in case of masses and also demonstrated higher sensitivity of DM plus DBT over DM alone (92% vs. 89%) where mass was the predominant finding.<sup>[10,11]</sup>

In this study, lesion morphology varied with HER2/neu status significantly on both DM and DBT. On DBT, HER2/neu 0 tumors mostly presented as noncalcified masses; whereas HER2/neu 3+ tumors were masses or asymmetries with microcalcifications. All TNBC with HER2-0 score presented as masses without microcalcifications. Previously, published studies also show that TNBC are more likely to present as noncalcified masses.<sup>[12,13]</sup>

Margins of mass did not vary significantly with HER2/neu scores on DM or DBT. Farrokh *et al.*<sup>[14]</sup> also showed no significant correlation between margins of masses and HER2/neu status. However, on DBT, spiculated margins were more frequently seen with increasing intensity of HER2/neu positivity in our study, demonstrating its superiority over DM. A study done by Wang *et al.*,<sup>[15]</sup> demonstrated that in masses with microcalcifications, spiculated margins were seen in significantly more tumors having HER2/neu overexpression.

In addition, the presence or absence of microcalcifications varied significantly with HER2/neu status. HER2/neu 3+ cases were associated with microcalcifications, all of them being fine pleomorphic or fine linear branching type. In a study by Sun *et al.* in 2014, the ratio of malignant calcifications was significantly high in HER2/neu positive cases.<sup>[16]</sup> Similar findings were reported by Wang *et al.* in 2008.<sup>[15]</sup> In a systematic review and meta-analysis by Elias *et al.* in 2014, it was found that the presence of microcalcifications increased the chance of HER2/neu overexpression, which was not dependant on the presence or absence of associated mass.<sup>[5,14]</sup> Some studies showed a correlation specific to fine linear/branching microcalcifications.<sup>[5]</sup>

The study showed that BI-RADS scores varied significantly on DBT as more intense HER2/neu immunostaining was frequently associated with BI-RADS 5 score. Previous studies have reported that the chance of a patient having HER2 overexpression was higher in cases where mammographic findings were highly suspicious for malignancy.<sup>[5]</sup> Similar results had been reported in a study by Bae *et al.* for Ductal carcinoma *in-situ*, where there was a positive correlation of BI-RADS score and Her2/neu over-expression.<sup>[17]</sup>

There are some limitations in our study including a small study sample and a lack of correlation of FISH test to verify the HER2/NEU status as obtained by IHC. Morphology of the lesions may have been affected by the fact that lesions were already palpable when diagnosed. However, this may have been beneficial as well, because it is more likely to reflect the completely evolved tumor characteristics since no early intervention was done.

## Conclusion

- In patients with self-detected lumps, mammographic findings may predict HER2/neu expression, which can be useful in better prognostication and management
- Higher BI-RADS scores, fine pleomorphic and fine linear branching calcifications and spiculated margins of tumors are frequently associated with HER2/neu 3+ lesions
- HER2/neu 1+ and HER2/neu 2+ lesions are variably associated with microcalcifications which are more often of amorphous or punctate type and rarely extensive. Thus HER2/neu 1+ and HER2/neu 2+ lesions may have distinct mammographic features, particularly related to calcification morphology and its extent. This observation needs to be investigated in larger studies.

## Acknowledgments

We would like to thank our patients and the staff of Departments of Radiodiagnosis, Endocrine and Breast Surgery, and Pathology for their support in completing this study.

## Financial support and sponsorship

Nil.

## Conflicts of interest

There are no conflicts of interest.

## References

1. Leong SP, Shen ZZ, Liu TJ, Agarwal G, Tajima T, Paik NS, *et al.* Is breast cancer the same disease in Asian and Western countries? World J Surg. 2010 Oct;34(10):2308-24. doi: 10.1007/s00268-010-0683-1. PubMed PMID: 20607258; PubMed Central PMCID: PMC2936680.
2. Ferretti G, Felici A, Papaldo P, Fabi A, Cognetti F. HER2/neu role in breast cancer: From a prognostic foe to a predictive friend. Curr Opin Obstet Gynecol 2007;19:56-62.
3. Kumar V, Tewari M, Singh U, Shukla HS. Significance of Her-2/neu protein over expression in Indian breast cancer patients. Indian J Surg 2007;69:122-8.
4. Zhou BP, Hung MC. Dysregulation of cellular signaling by HER2/neu in breast cancer. Semin Oncol 2003;30:38-48.
5. Elias SG, Adams A, Wisner DJ, Esserman LJ, Van't Veer LJ, Mali WP, *et al.* Imaging features of HER2 overexpression in breast cancer: A systematic review and meta-analysis. Cancer Epidemiol Biomarkers Prev 2014;23:1464-83.
6. Roth RG, Maidment AD, Weinstein SP, Roth SO, Conant EF. Digital breast tomosynthesis: Lessons learned from early clinical implementation. Radiographics 2014;34:E89-102.
7. Houssami N, Skaane P. Overview of the evidence on digital breast tomosynthesis in breast cancer detection. Breast 2013;22:101-8.
8. Sickles EA, D'Orsi CJ, Bassett LW, Appleton CM, Berg WA, Burnside ES, *et al.* ACR BIRADS® mammography. In: ACR BIRADS® Atlas, Breast Imaging Reporting and Data System. Reston, VA: American College of Radiology; 2013.
9. Lång K, Andersson I, Zackrisson S. Breast cancer detection in digital breast tomosynthesis and digital mammography-a side-by-side review of discrepant cases. Br J Radiol 2014;87:20140080.
10. Poplack SP, Tosteson TD, Kogel CA, Nagy HM. Digital breast tomosynthesis: Initial experience in 98 women with abnormal digital screening mammography. AJR Am J Roentgenol 2007;189:616-23.
11. Gilbert FJ, Tucker L, Gillan MG, Willsher P, Cooke J, Duncan KA, *et al.* The TOMMY trial: A comparison of TOMosynthesis with digital Mammography in the UK NHS breast screening programme - A multicentre retrospective reading study comparing the diagnostic performance of digital breast tomosynthesis and digital mammography with digital mammography alone. Health Technol Assess 2015;19:i-xxv, 1-136.
12. Gao B, Zhang H, Zhang SD, Cheng XY, Zheng SM, Sun YH, *et al.* Mammographic and clinicopathological features of triple-negative breast cancer. Br J Radiol 2014;87:20130496.
13. Krizmanich-Conniff KM, Paramagul C, Patterson SK, Helvie MA, Roubidoux MA, Myles JD, *et al.* Triple receptor-negative breast cancer: Imaging and clinical characteristics. AJR Am J Roentgenol 2012;199:458-64.

14. Farrokh D, Boloursaz S, Homai F. Relationship among mammographic findings with histopathologic type of breast cancer and human epidermal growth factor receptor 2 (HER2) in young women. *Electron Physician* 2017;25;9:4300-5.
15. Wang X, Chao L, Chen L, Tian B, Zang Y, Hua M, *et al.* Correlation of mammographic calcifications with HER2/NEU over expression in primary breast carcinomas. *J Digit Imaging* 2008;21;170-6.
16. Sun SS, Zhang B, Zhao HM, Cao XC. Association between mammographic features and clinicopathological characteristics in invasive ductal carcinoma of breast cancer. *Mol Clin Oncol* 2014;2:623-9.
17. Bae MS, Moon WK, Chang JM, Cho N, Park SY, Won JK, *et al.* Mammographic features of calcifications in DCIS: Correlation with oestrogen receptor and human epidermal growth factor receptor 2 status. *Eur Radiol* 2013;23:2072-8.