

Letter to the Editor

Primary signet-ring adenocarcinoma of the lung: A rare lung tumor

DOI: 10.4103/sajc.sajc_153_17

Dear Editor,

Signet-ring cell adenocarcinomas (SRCC) are rare tumors which most commonly originate from the gastrointestinal (GI) tract. Lung as a site of primary signet-ring variant of adenocarcinoma is extremely uncommon with very few reports available on literature review.^[1-4] It is a highly aggressive tumor when found in lung, but few case reports show good response in patients who were found positive for anaplastic lymphoma kinase (ALK) mutation.^[5-7] Immunohistochemistry (IHC) plays a very important role in assessing the organ of origin of this tumor. We here describe a rare case of primary lung SRCC and the role of IHC in its diagnosis and management.

A 44-year-old female, nonsmoker with no comorbidities, presented with complaints of fever, progressive breathlessness, dry cough, and weight loss for the past 1 month. The patient was evaluated outside for these symptoms and found to have right-sided pleural effusion [Figure 1a]. Contrast-enhanced computed tomography (CT) of the chest revealed right-sided pleural effusion, mild pericardial effusion, and multiple mediastinal lymph nodes (largest being 21 mm) with some showing caseation [Figure 1b and c]. The patient was started on antitubercular treatment, but her condition worsened over the next 3 weeks. Repeat X-ray of the chest showed an increase in pleural effusion [Figure 1d] requiring therapeutic drainage of 1.5 L fluid, after which she was referred to our center. Physical examination showed tachypnea (45/min), tachycardia (120/min) with blood pressure 100/70 mmHg, and oxygen saturation of 90% with 4 L oxygen by the nasal prong. X-ray showed right-sided pleural effusion, and echocardiography revealed moderate-to-severe pericardial

(Continue on page 259...)

(Letter to the editor continue from page 257...)

effusion with impending tamponade. Pericardiocentesis was done, and 400 ml of hemorrhagic pericardial fluid was drained. Nature of fluid was lymphocytic exudative with low adenosine deaminase (ADA) (11 U/L) and was positive for malignant cells. Repeat diagnostic pleural tap revealed neutrophilic exudative effusion with ADA 8.3 U/L, and fluid was positive for atypical cells. To look for the primary site and extension of disease, positron-emission tomography (PET)-CT was done, which showed fluorodeoxyglucose (FDG)-avid right supraclavicular lymph node (largest 26 mm × 16 mm), mediastinal lymph nodes, and moderate-to-large right-sided pleural effusion with FDG-avid mass lesion in the right lower lobe (standardized uptake value: 2.7 body surface area). Right-sided cervical lymph node dissection was done for confirmation of diagnosis.

Histopathology of the nodal specimen showed effacement of lymph node architecture, distention of subcapsular and medullary sinus by signet ring-like cells, nests of cells with signet-ring morphology, eosinophilic cytoplasm, and prominent nucleoli [Figure 1a]. Possibility of metastatic carcinoma/signet-ring cell lymphoma and signet-ring sinus histiocytosis was kept, and the biopsy was subjected to IHC which was negative for leukocyte common antigen (LCA), CD68, vimentin, cytokeratin (CK) 20, CDX2, and synaptophysin, ruling out the possibility of lymphoma and histiocytosis [Figure 1b]. IHC markers in pericardial fluid cell block were positive for CK, epithelial membrane antigen (EMA), thyroid transcription factor (TTF)-1, and CK7 [Figure 1c-f] and negative for CDX2, estrogen receptor (ER), progesterone receptor (PR), and LCA. IHC markers for right cervical lymph node were also positive

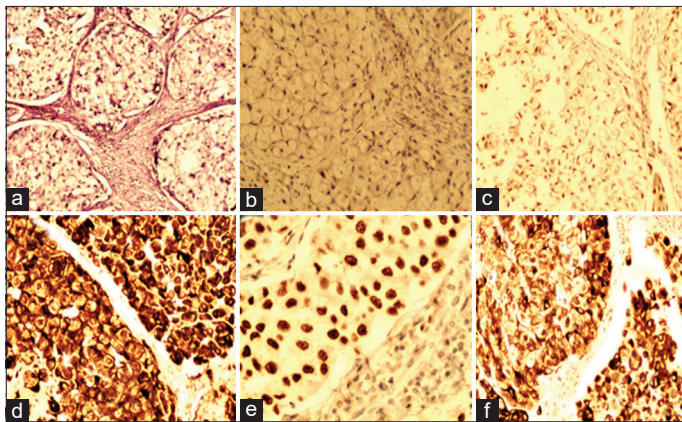


Figure 1: (a) Histopathology of node showing effacement of lymph node architecture, nests of cells with signet-ring morphology, eosinophilic cytoplasm, and prominent nucleoli. Immunohistochemistry slides showing stains (b) CDX2 negative (c) cytokeratin positive (d) epithelial membrane antigen positive (e) thyroid transcription factor-1 positive, and (f) cytokeratin 7 positive

for CEA and TTF-1; strongly positive for CK7, EMA, and CK; and focally positive for P53 and Ki-67, with 50% confirming the diagnosis of SRCC with metastasis to right cervical lymph node. Epidermal growth factor receptor (EGFR), ros oncogene 1 (ROS1), and ALK mutation was done and found to be negative. In view of recurrent pleural effusion, right-sided Intercostal drainage (ICD) insertion and talc pleurodesis were done as palliative measures, and the patient was started on platinum-based chemotherapy. However, the patient did not improve on chemotherapy and died after 2 months.

SRCC is a variety of mucin-producing adenocarcinoma, which most commonly arises from the stomach, colon, urinary bladder, prostate, and breast. SRCC of the lung as primary is extremely rare and highly aggressive variant of adenocarcinoma with characteristic clinic-pathological features.^[2,3,8] It is most common in nonsmokers and younger age with no sex predilection and follows a more aggressive clinical course. A large series of 2640 patients of lung cancer showed that SRCC lung as primary is seen only in 1.5% ($n = 39$) of all lung malignancies.^[4] The mean age of presentation of SRCC in this study was 54.6 years (range: 32–76 years), with a male-to-female ratio of 1.16:1 and 5-year survival of 28%.^[4] Due to rarity as primary lung tumor, metastasis from other organs is always kept as the first possibility and must be evaluated thoroughly.

Histopathologically, it is characterized by tumor cells which are filled with intracytoplasmic mucin and an eccentrically displaced nucleus, giving an appearance of a signet ring. Adenocarcinomas showing more than 50% signet-ring cell morphology are considered as SRCC. SRCC component is also considered to be a potential prognostic factor in primary lung tumor with a higher proportion of signet-ring cell associated with worse outcomes.^[4] Diagnosis of SRCC of the lung as the primary site of the tumor is always on the basis of radiology and IHC. Primary pulmonary SRCC stains positive with TTF-1 and CK7 but are usually negative for CK20 and CDX2. CK20 and CDX2 positivity is seen in SRCC of the GI and bladder origin. In our patient ER, PR are negative (which is positive in breast cancer) and vimentin and synaptophysin was also negative ruling out the possibility of mesenchymal and neuroendocrine origin.^[5,6] In our case, there was no PET avidity anywhere else in the body ruling out the possibility of extrapulmonary SRCC along with supportive IHC markers.

About 3%–7% of SRCC pulmonary adenocarcinomas are found to be positive for ALK gene rearrangement which

is associated with better response to crizotinib therapy.^[5-7] Recently, other chromosomal rearrangements involving ROS1 receptor tyrosine kinase gene mutation have also been shown to be more responsive to crizotinib,^[5,6] but their incidence in the SRCC lung tumor population is not well known. Our patient was negative for EGFR, ALK, and ROS1 mutation and was managed with platinum-based doublet therapy.

SRCC is a rare tumor of the lung which has more aggressive natural course of the disease and poor outcome as compared to other tumors of the lung. Diagnosis needs a thorough search for ruling out other sites of origin and metastasis to lung. IHC plays a major role in confirming the diagnosis. Treatment options are limited, with oral therapy available for patients who have ALK and ROS1 mutation. Such patients have been shown to have better outcome when compared to conventional platinum-based therapy although more data are required to assess the efficacy and survival benefits of this treatment.

Declaration of patient consent

The authors certify that they have obtained all appropriate patient consent forms. In the form the patient(s) has/have given his/her/their consent for his/her/their images and other clinical information to be reported in the journal. The patients understand that their names and initials will not be published and due efforts will be made to conceal their identity, but anonymity cannot be guaranteed.

Financial support and sponsorship

Nil.

Conflicts of interest

There are no conflicts of interest.

Varun Rajpal, Rahul Kumar Sharma, Charul Dabral, Deepak Talwar

Metro Centre for Respiratory Diseases, Metro Multispecialty Hospital, Noida, Uttar Pradesh, India

Correspondence to: Dr. Rahul Kumar Sharma, E-mail: dr.rahulksharma@gmail.com

References

- Hayashi H, Kitamura H, Nakatani Y, Inayama Y, Ito T, Kitamura H. Primary signet-ring cell carcinoma of the lung: Histochemical and immunohistochemical characterization. *Hum Pathol* 1999;30:378-83.
- Merchant SH, Amin MB, Tamboli P, Ro J, Ordóñez NG, Ayala AG, et al. Primary signet-ring cell carcinoma of lung: Immunohistochemical study and comparison with non-pulmonary signet-ring cell carcinomas. *Am J Surg Pathol* 2001;25:1515-9.
- Castro CY, Moran CA, Flieder DG, Suster S. Primary signet ring cell adenocarcinomas of the lung: A clinicopathological study of 15 cases. *Histopathology* 2001;39:397-401.
- Tsuta K, Ishii G, Yoh K, Nitadori J, Hasebe T, Nishiwaki Y, et al. Primary lung carcinoma with signet-ring cell carcinoma components: Clinicopathological analysis of 39 cases. *Am J Surg Pathol* 2004;28:868-74.
- Nishino M, Klepeis VE, Yeap BY, Bergethon K, Morales-Oyarvide V, Dias-Santagata D, et al. Histologic and cytomorphologic features of ALK-rearranged lung adenocarcinomas. *Mod Pathol* 2012;25:1462-72.
- Ha SY, Ahn J, Roh MS, Han J, Lee JJ, Lee B, et al. Cytologic features of ALK-positive pulmonary adenocarcinoma. *Korean J Pathol* 2013;47:252-7.
- Lee HY, Ahn HK, Jeong JY, Kwon MJ, Han JH, Sun JM, et al. Favorable clinical outcomes of pemetrexed treatment in anaplastic lymphoma kinase positive non-small-cell lung cancer. *Lung Cancer* 2013;79:40-5.
- Travis WD, Brambilla E, Riely GJ. New pathologic classification of lung cancer: Relevance for clinical practice and clinical trials. *J Clin Oncol* 2013;31:992-1001.

This is an open access journal, and articles are distributed under the terms of the Creative Commons Attribution-NonCommercial-ShareAlike 4.0 License, which allows others to remix, tweak, and build upon the work non-commercially, as long as appropriate credit is given and the new creations are licensed under the identical terms.

How to cite this article: Rajpal V, Sharma RK, Dabral C, Talwar D. Primary signet-ring adenocarcinoma of the lung: A rare lung tumor. *South Asian J Cancer* 2019;8:257-60.

© 2019 The South Asian Journal of Cancer | Published by Wolters Kluwer - Medknow