

Original Article

Isolated Terminal Ileal Mucosal Changes: When is the Bite Indicated?

Mayank Jain, M. Srinivas, R. Ravi, B. Mahadevan, Tom Michael, Jayanthi Venkataraman

Department of
Gastroenterology, Gleneagles
Global Health City, Chennai,
Tamil Nadu, India

ABSTRACT

Aim: This study aims to determine the clinical presentation, and ileal mucosal changes during colonoscopy for which terminal ileal (TI) biopsies were taken at our center and to determine the specific histopathology which had the best yield for specific colonoscopy findings. **Materials and Methods:** Retrospective audit of all patients who underwent colonoscopy with ileoscopy between 2012 and 2016. All patients with TI mucosal changes and normal colonic mucosa, who underwent ileal biopsy, were included in this study. Patient data regarding age, gender, indication for ileocolonoscopy (screening for colorectal cancers, inflammatory bowel disease [IBD], or irritable bowel syndrome [IBS]) and histopathology changes were collected. Appropriate statistical tests were used and $P < 0.05$ was considered statistically significant. **Results:** One hundred and nine patients had isolated ileal lesions. The median age was 44.1 years (range 8–80 years). Men outnumbered women in a ratio of 82:27. The major clinical indications for ileocolonoscopy were IBS (64.2%), followed by IBD (22%). Ulcers (aphthoid) were the most frequent finding followed by mucosal nodularity and nonspecific findings. Ulcers in ileum were most often reported as chronic ileitis (46.2%), followed by nonspecific changes (35.2%) Biopsy from nodular ileal lesions, were predominantly nonspecific (74.4%), followed by acute (15.4%) and chronic ileitis (10.2%). About 50% of specimens with nonspecific ileal changes had nonspecific histological changes. Ileal ulcers had the highest sensitivity, PPV, and NPV for significant histological findings. **Conclusion:** Ileal ulcers are the significant colonoscopy findings where tissue biopsy is likely to yield a definitive diagnosis and justify specific management. Biopsies from nonspecific ileal changes and nodularity should be discouraged as it is unlikely to pick up any major abnormality.

KEYWORDS: Biopsy, ileum, intestine

INTRODUCTION

With advances in technicality skills and preference of sedation by patients, terminal ileal (TI) intubation during colonoscopy has improved from 60%–75% to 95%–98% in recent times.^[1-4] In clinical practice, TI abnormalities such as nodularity, ulcers, and erythema are often noted during colonoscopy evaluation for a variety of indications. The decision to take a biopsy is usually based on the endoscopist's discretion. We also encounter at times situations where the clinical symptoms and TI findings are conflicting or inconclusive. Biopsy for histopathological diagnosis, most often, adds to the conundrum. Thus, the present

study was planned as an audit of TI biopsies at our center in the past 5 years. The primary aim of the study was to retrospectively determine the clinical presentation and ileal mucosal changes during colonoscopy for which TI biopsies were taken. The secondary endpoint of the study was to determine the specific histopathology which had the best yield for specific colonoscopy findings.

Address for correspondence: Dr. Mayank Jain,
Department of Gastroenterology, Gleneagles Global Health
City, Chennai - 600 100, Chennai, Tamil Nadu, India.
E-mail: mayank4670@rediffmail.com

This is an open access journal, and articles are distributed under the terms of the Creative Commons Attribution-NonCommercial-ShareAlike 4.0 License, which allows others to remix, tweak, and build upon the work non-commercially, as long as appropriate credit is given and the new creations are licensed under the identical terms.

For reprints contact: reprints@medknow.com

How to cite this article: Jain M, Srinivas M, Ravi R, Mahadevan B, Michael T, Venkataraman J. Isolated terminal ileal mucosal changes: When is the bite indicated?. *J Dig Endosc* 2018;9:66-70.

Access this article online

Quick Response Code:



Website: www.jdeonline.in

DOI: 10.4103/jde.JDE_68_17

MATERIALS AND METHODS

The study was done at the Institute of Gastrointestinal Sciences, Gleneagles Global Health City, Chennai. All patients who underwent ileocolonoscopy between 2012 and 2016 were included. Patient data included age, gender, and indication for the procedure. The ileal mucosal changes were documented from patient records and static images.

Indications for colonoscopy were classified into the following distinct prototype groups. These were the working diagnosis made by the consultants at the consultation clinic following standard guidelines for diagnosis and documented in the patient records.

- Irritable bowel syndrome (IBS) – As per Rome III criteria
- Suspected Colorectal cancers (CRC) – This included patients presenting as unexplained anemia, bleeding per rectum, cancer surveillance in patients with family history of gastrointestinal cancer
- Inflammatory bowel disease (IBD) – Naïve patients presenting as chronic diarrhea, bloody or blood admixed with mucus diarrhea, CECT imaging showing long segment TI thickening
- Chronic colonic infection, for example, tuberculosis: In suspected ileocecal tuberculosis with systemic symptoms, symptoms of partial small bowel obstruction, ileocecal mass
- Others such as diverticulosis/itis, nonspecific lower quadrant abdominal pain, postradiation enteritis, postorgan transplant patients with pain abdomen/diarrhea.

Ileal mucosal changes were classified as [Figure 1].

- Ileal ulcers – Aphthous or large ulcers
- Ileal mucosal nodularity with or without surface ulceration
- Nonspecific – Effaced mucosa, loss of villi, patchy erythema.

Histopathology changes were classified based on the standard protocol of reporting^[5] as:

Acute ileitis

The presence of mucosal aphthous ulcers with scattered eosinophils, neutrophil infiltration, and alternate bands of fibrosis in the lamina propria extending up to the mucosal surface.

Chronic ileitis

Characterized by distortion of the mucosal crypt architecture, the predominance of lymphomononuclear cells, plasma cells, eosinophils, pyloric metaplasia, goblet cell rich crypts (hypercrinia), mucosal basal plasmacytosis, and broadening of the ileal villous tips. Among these, however, topographical changes such as

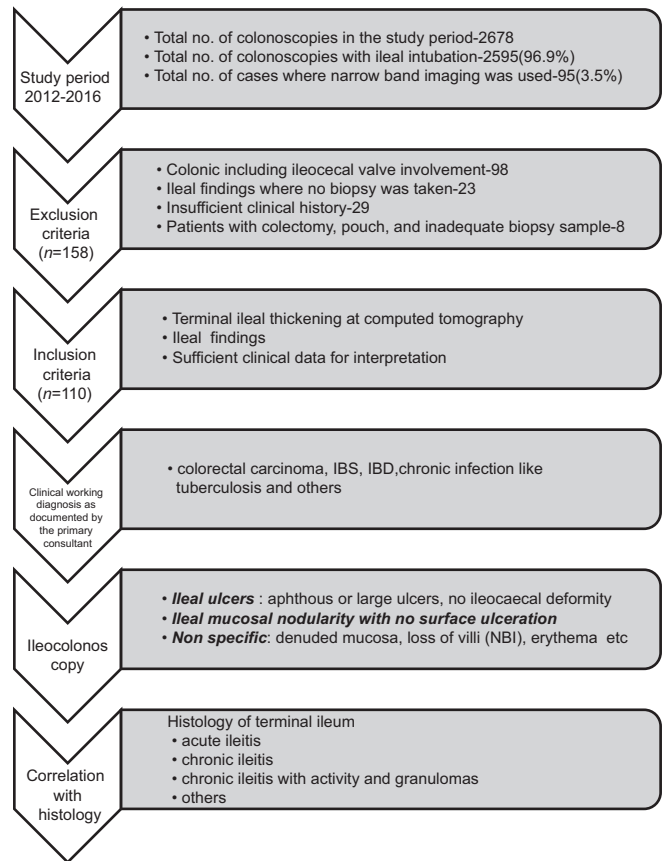


Figure 1: Flowchart for the study

crypt branching, crypt shortening, and the crypt loss were considered as hallmarks of chronicity.

Chronic ileitis with activity and granulomas

Crohn's disease is typified by mucosal pericryptal microgranuloma, rail track/deep burrowing ulcers, basal plasmacytosis, dense lymphocytic infiltrations, and epithelioid granulomas in mucosa and submucosa, necrosis as definitive of tuberculosis.

Others

Lymphoid aggregation, patchy inflammatory infiltrate with no crypt distortion.

Rarely specific features

Eosinophilic ileitis, ischemic ileitis, radiation enteritis, graft versus host disease, and tumors such as lymphoma.

The methodology of the study is seen in the consort chart [Figure 1].

Ileocolonoscopy was performed under sedation by senior consultants until 2014. Later, senior registrars were involved who worked under supervision and guidance of senior consultants. Being a corporate hospital, biopsies were taken only after consensus of the treating consultant. All reports were seen and approved by the incharge consultant, as per the hospital policy.

Since this is a retrospective audit, no fixed number of biopsies was set for inclusion. The protocol followed is four biopsies from the suspicious areas in ileum. All samples were fixed in 10% formalin. Standard processing techniques were followed and sections 4–6 microns were stained routinely with hematoxylin and eosin and special stains were used when indicated. The inadequate sample reported as no mucosal glands and predominantly fibrocollagenous tissue were excluded from analysis.

Statistical analysis

The results were interpreted using rows and columns contingency tables for determining statistical significance using Chi-square test. *P* < 0.05 was considered statistically significant. Sensitivity, specificity, positive, and negative predictive values were calculated.

The retrospective study was approved by the Ethics Committee of the Institution.

RESULTS

The indications for ileocolonoscopy and the corresponding ileal findings are shown in Table 1. One hundred and nine patients had isolated ileal lesions. The median age was 44.1 years (range 8–80 years). Men outnumbered women in a ratio of 82:27.

The major clinical indications for ileocolonoscopy were IBS (64.2%), followed by IBD (22%).

Ileal mucosal changes in specific clinical situations

As shown in Table 1, ulcers (aphthoid) were the most frequent finding in suspected IBD cases, during CRC

screening and those with an IBS. Mucosal nodularity was frequent in IBS and commonly noted in cases with suspected CRC. Nonspecific findings ranged from 8.5% to 16.7% [Figure 2].

Histological correlation with ileal mucosal changes

Ulcers in ileum [Table 2] was most often reported as chronic ileitis (46.2%), followed by nonspecific changes (35.2%) that included patchy inflammation and/or lymphoid aggregates. One specimen each had specific findings of cytomegalovirus infection and eosinophilic enteritis. Biopsies from strictures revealed nonspecific findings in 50% of cases and acute or chronic ileitis in one case each. Biopsy from nodular ileal lesions, were predominantly nonspecific (74.4%), followed by acute (15.4%) and chronic ileitis (10.2%). About 50% of specimens with nonspecific ileal changes had nonspecific histological changes as well. Thus, significant histological findings of chronic ileitis with activity/granuloma and acute ileitis were more common in cases with ileal ulcers (*P* = 0.002) rather than other findings. Ileal ulcers had the highest sensitivity, PPV, and NPV for significant histological findings of acute or chronic ileitis [Table 3]. Ileal nodularity and nonspecific mucosal changes had the least sensitivity, PPV, and NPV. Nonspecific mucosal changes such as patchy inflammation, effaced mucosa, and loss of villi (on NBI) had very low sensitivity but high specificity (89.3%), suggesting that these findings were unlikely to predict any significant histopathological changes.

Table 1: Clinical indications and ileal mucosal changes

Indication	Ulcers (large/small) (%)	Stricture (%)	Mucosal nodularity (%)	Nonspecific (erythema, denuded/effaced mucosa, loss of villi) (%)	<i>P</i>
CRC (12)	6 (50)	0	4 (33.3)	2 (16.7)	0.06
IBD (24)	14 (58.3)	3 (12.5)	3 (12.5)	4 (16.7)	
IBS (70)	32 (45.7)	1 (1.5)	31 (44.3)	6 (8.5)	
Others (3)	2 (66.6)	-	1 (33.4)	-	
Total (109)	54 (49.5)	4 (3.7)	39 (35.8)	12 (11)	

CRC=Colorectal cancer, IBD=Inflammatory bowel disease, IBS=Irritable bowel syndrome

Table 2: Endoscopic and histological correlation

Ileal mucosal changes	Histology					<i>P</i>
	Rare causes (CMV, eosinophilic) (%)	Others (patchy inflammation, lymphoid aggregates) (%)	Acute ileitis (%)	Chronic ileitis		
				With activity (%)	With granulomas (%)	
Ulcers (54)	2 (3.7)	19 (35.2)	8 (14.8)	24 (44.4)	1 (1.8)	0.002
Stricture (4)	-	2 (50)	1 (25)	1 (25)	-	
Nodularity (39)	-	29 (74.4)	6 (15.4)	4 (10.2)	-	
Nonspecific changes (12)	-	6 (50)	3 (25)	3 (25)		
Total (109)	2 (1.8)	56 (51.4)	18 (16.5)	32 (29.4)	1 (0.9)	

CMV=Cytomegalovirus

Table 3: Predicting outcome of isolated ileal findings at histology

	Percentage (95% CI)			
	Sensitivity	Specificity	PPV	NPV
Ulcers	64.7 (50-77.6)	66.1 (52.2-78.2)	63.5 (53.4-72.5)	67.3 (57.6-75.7)
Nodularity	19.6 (9.8-33.1)	48.2 (34.7-62)	25.6 (15.8-38.8)	39.7 (32.7-47.1)
Nonspecific changes	11.8 (4.5-23.8)	89.3 (78.1-95.9)	50 (25.6-74.4)	52.6 (49.3-56)

CI=Confidence interval, PPV=Positive predictive value, NPV=Negative predictive value

DISCUSSION

TI biopsies for varied mucosal changes are frequently recommended for histopathological correlation. At present, there are no specific guidelines to suggest the role of such biopsies.

There have been a few studies on TI biopsies and its impact on clinical decision-making. In 1985, Borsch and Schmidt prospectively evaluated 400 consecutive patients successfully undergoing TI endoscopy with biopsy.^[6] Although pathological abnormalities were identified in only 5% of these biopsies, diagnostic information was obtained in 30% after excluding suspicious abnormalities. Zwas *et al.*^[3] evaluated 144 patients undergoing colonoscopy. Biopsy of the TI was successful in 130 patients. About 12.5% of symptomatic patients and 2.7% of asymptomatic patients had histological abnormalities. Geboes *et al.*^[7] observed ileal mucosal abnormality in 48% and histological changes in 49% of patients undergoing colonoscopy for enterocolitis. The authors concluded that ileoscopy was beneficial in carefully selected patients with IBD-related symptoms.

A recent study from a center in north India^[8] on 1632 colonoscopy reported ulcers in the ileocaecal region (ileum: 40%; cecum: 33%; and ileocecum in remaining) in 104 patients. The predominant presentation in this series was lower gastrointestinal bleed.

Common indications for ileocolonoscopy in our series were suspected IBS, IBD, and CRC in that order. As is recommended in the guidelines, colonoscopy was considered complete only when terminal ileum was seen. Most frequent indications for ileal mucosal biopsy were ileal ulcers in 54 patients (49.5%), nodularity in 39 patients (35.8%), and nonspecific findings in 12 (11%). Three patients had postsolid organ transplant status and underwent ileocolonoscopy for pain abdomen and/or diarrhea. Of the 109 biopsies sent, nonspecific findings of patchy inflammation

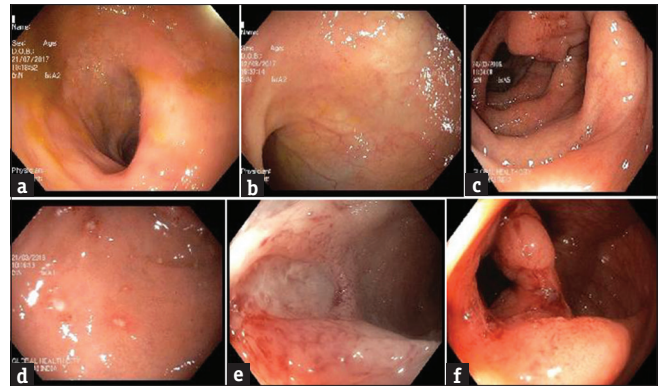


Figure 2: Representative ileal mucosal changes (clockwise) - (a) Normal ileum, (b) ileal erythema, (c) mass lesion and ulcers in ileum, (d) aphthous ulcers, (e) Large ulcer with slough, (f) Nodularity and ulcerations at IC region

with/without lymphoid aggregates was the most common finding (51.4%), followed by chronic ileitis (30.3%) and acute ileitis (16.5%). The yield of detecting significant histological abnormality (acute and chronic ileitis, specific etiology) was highest for ileal ulcers (35/54, 64.8%) followed by isolated ileal stricture and nonspecific mucosal changes (50% each). Isolated ileal nodularity was associated with a significant histological abnormality in only a quarter of cases. The positive likelihood ratio of detecting histological abnormality for various ileal mucosal changes indicated that TI biopsy had the best yield for ileal ulcers. Based on our observational retrospective study, we reiterate that nonspecific ileal mucosal changes and nodularity do not require a tissue biopsy. This observation is similar to McHugh *et al.* who reported that diagnostic yield of TI biopsy varied with indication and endoscopic findings. Biopsy was of greatest value in patients undergoing endoscopy for known or strongly suspected Crohn's disease, or with an abnormal imaging study of the TI. Biopsy of endoscopically normal mucosa was unlikely to yield a diagnostic useful information.^[9]

CONCLUSION

Ileal ulcers are the significant colonoscopy findings where tissue biopsy is likely to yield a definitive diagnosis and justify specific management. Biopsies from nonspecific ileal changes and nodularity should be discouraged as it is unlikely to pick up any major abnormality. Thus, "take a bite only when you see an ileal ulcer!"

Financial support and sponsorship

Nil.

Conflicts of interest

There are no conflicts of interest.

REFERENCES

1. Belaiche J, Van Kemseke C, Louis E. Use of the enteroscope for colo-ileoscopy: Low yield in unexplained lower gastrointestinal bleeding. *Endoscopy* 1999;31:298-301.
2. Kundrotas LW, Clement DJ, Kubik CM, Robinson AB, Wolfe PA. A prospective evaluation of successful terminal ileum intubation during routine colonoscopy. *Gastrointest Endosc* 1994;40:544-6.
3. Zwas FR, Bonheim NA, Berken CA, Gray S. Diagnostic yield of routine ileoscopy. *Am J Gastroenterol* 1995;90:1441-3.
4. Morini S, Lorenzetti R, Stella F, Martini MT, Hassan C, Zullo A, *et al.* Retrograde ileoscopy in chronic nonbloody diarrhea: A prospective, case-control study. *Am J Gastroenterol* 2003;98:1512-5.
5. Das P, Gahlot GP, Mehta R, Gupta SD. Interpretation of ileal biopsies. *Indian J Pathol Microbiol* 2015;58:146-53.
6. Börsch G, Schmidt G. Endoscopy of the terminal ileum. Diagnostic yield in 400 consecutive examinations. *Dis Colon Rectum* 1985;28:499-501.
7. Geboes K, Ectors N, D'Haens G, Rutgeerts P. Is ileoscopy with biopsy worthwhile in patients presenting with symptoms of inflammatory bowel disease? *Am J Gastroenterol* 1998;93:201-6.
8. Toshniwal J, Chawlani R, Thawrani A, Sharma R, Arora A, Kotecha HL, *et al.* All ileo-cecal ulcers are not Crohn's: Changing perspectives of symptomatic ileocecal ulcers. *World J Gastrointest Endosc* 2017;9:327-33.
9. McHugh JB, Appelman HD, McKenna BJ. The diagnostic value of endoscopic terminal ileum biopsies. *Am J Gastroenterol* 2007;102:1084-9.