

Original Article

Rigid Sigmoidoscopic Examination, an Investigation Down but Not Out: A 5-Year Single-Center Experience on 9418 Patients

Sandeep V. Nair; Thazhath Mavali Ramachandran, Prajob Prasad Geevarghese, N. Sunil Kumar; Shine J Pakalomattom

Department of
Gastroenterology,
Government Medical College,
Kozhikode, Kerala, India

ABSTRACT **Background:** Rigid sigmoidoscopy (RS) in the present era of flexible sigmoidoscopies is falling out of favor although it continues to be used in some centers as an outpatient (OP) department procedure. **Aims:** This study aims to determine the utility of RS for diagnosis of rectosigmoidal pathologies in the OP setting with emphasis on neoplastic lesions. **Methods:** We retrospectively studied the RS records and histopathology reports (HPRs) of 5 years (July 2013–June 2018) done in the Department of Gastroenterology at Medical College Calicut. **Results:** During the study period, 9418 RS examinations were done, and a total of 6921 abnormalities were picked up, giving a diagnostic yield of 73.5%. Most common indication was bleeding per rectum (PR) (51%), followed by constipation (29%). The most common lesion found was hemorrhoids 39.8% followed by proctitis 13.7%, neoplasms 9.7%, and others 10.3% while 26.5% studies were normal. HPRs showed 7.7% to be malignant, 5.8% were adenoma, 12.2% were inflammatory bowel disease ulcerative colitis (IBD UC), 2.2% were solitary rectal ulcer syndrome, 1.2% nonspecific colitis, 1.7% nonneoplastic polyps, 2.7% were normal, and 1.4% were inconclusive. Of the 4812 patients with complaints of bleeding PR, 4739 (98.5%) had a diagnosis after RS, of which hemorrhoids (72.7%) was the most common cause followed by proctitis (14.2%), neoplasm (9%), and others (4.1%). The sensitivity, specificity, positive predictive value, and negative predictive value of RS in detecting neoplasia was 98.2%, 96.8%, 66.1%, and 99.9%, respectively, when HPR was gold standard. RS was found to be effective for assessing activity in IBD UC. **Conclusion:** RS is a simple, cheap, and effective tool for diagnosing various rectosigmoid pathologies. RS can be used as an effective screening test for rectosigmoid pathologies, especially neoplasia and IBD UC.

KEYWORDS: Rectosigmoid cancers, rigid sigmoidoscopy, screening

INTRODUCTION

Symptoms localized to the rectum and sigmoid can range from per rectal bleeding to alteration in bowel habits which may be caused by seemingly innocuous benign anal conditions to neoplastic lesions comprising colorectal adenomas and carcinomas. The symptoms of colorectal disease are relatively nonspecific, and this is particularly true for colorectal neoplasia. The incidence of rectal cancer in India is lower than that in the western countries, and it is the tenth leading cancer in India but the mean age of rectal cancer is around 40–45 years.^[1]

Sigmoidoscopy is the first-line investigation in endoscopic evaluation of symptomatic patients presenting to colorectal clinics. Whether sigmoidoscopy is useful as a screening procedure for colorectal carcinoma is still

Address for correspondence: Dr. Thazhath Mavali Ramachandran,
Department of Gastroenterology, Government Medical College,
Kozhikode - 673 008, Kerala, India.
E-mail: drtmram@yahoo.com

This is an open access journal, and articles are distributed under the terms of the Creative Commons Attribution-NonCommercial-ShareAlike 4.0 License, which allows others to remix, tweak, and build upon the work non-commercially, as long as appropriate credit is given and the new creations are licensed under the identical terms.

For reprints contact: reprints@medknow.com

How to cite this article: Nair SV, Ramachandran TM, Geevarghese PP, Kumar NS, Pakalomattom SJ. Rigid sigmoidoscopic examination, an investigation down but not out: A 5-year single-center experience on 9418 patients. *J Dig Endosc* 2019;10:XX-XX.

Access this article online

Quick Response Code:



Website: www.jdeonline.in

DOI: 10.4103/jde.JDE_55_18

under considerable debate.^[2] Sigmoidoscopy could aid in the control of large bowel cancer by early detection of the 55% of colorectal cancers that develop in the rectosigmoid and by the identification and eradication of significant rectosigmoid adenomas. The value of sigmoidoscopy is not only related to possible improved survival resulting from the detection of localized cancer but also to adenoma detection. The prevalence of polyps detected by sigmoidoscopy has varied from 2% to 13%.^[3-5]

Rigid sigmoidoscopy (RS) is a simple outpatient (OP) procedure that helps the clinician in visualizing the mucosa lining the lower most end of the gastrointestinal (GI) tract specifically anus, rectum, and sigmoid colon. It is useful for quick and reliable diagnosis of a variety of disorders such as hemorrhoids, neoplastic lesions, and inflammatory conditions of the anus, rectum, and sigmoid colon.^[6] Of the two modalities, RS is usually done in OP clinics on unprepared bowel while flexible sigmoidoscopy (FS) is done in endoscopy suites, requires bowel preparation, needs more time, and sometimes sedation although it has the advantage of image acquisition.

Our center is well equipped with the latest flexible endoscopes; however, due to sizeable patient influx, we routinely do RS in the OP department (OPD) as it is a simple and quick method to assess the rectosigmoidal pathologies. As it is a simple, quick, and low cost procedure, it has a significant role as an investigative tool for evaluation of lower GI symptoms. Not many studies have been done to analyze the diagnostic yield of RS and look into its suitability for our population. This study aims at assessing the utility of RS in picking up various rectosigmoid pathologies. In spite of obvious shortcomings, RS is still in vogue in our institution, and to assess the efficacy of this modality in picking up anorectal and rectosigmoid lesions, we did a retrospective study of RS of all patients referred for evaluation of lower GI symptoms.

METHODS

This was a retrospective study done in the Department of Gastroenterology at Medical College Calicut. RS reports and histopathology reports (HPRs) of 5 years (July 2013–June 2018) was studied and data were acquired. Patients with lower GI symptoms who underwent RS in the OP clinic of Department of Gastroenterology, Medical College, Calicut, were the study participants. Pregnant women, poor visualization, and patients who did not cooperate were excluded. The research protocol was approved by the Institutional research and ethics committee. All participants had given written informed consent for undergoing RS.

RS is performed at the OP clinic on 2 days of the week in the sigmoidoscopy room of Gastroenterology OP in Super-speciality block of Government Medical College Calicut which is a tertiary care hospital. RS is performed with a nondisposable 30-cm long metallic rigid sigmoidoscope, illuminated with a separate light source. No preparation is usually given before the procedure. Brief history is taken, and the procedure is done without sedation, mostly in the knee-elbow position or left lateral position in old and debilitated patients. Details of per rectum (PR) findings and any positive findings are recorded, along with the depth of insertion, indication, adequacy of bowel preparation, and reasons for any termination. A typical RS study takes <10 min. Only if a study is completed, it is entered into the sigmoidoscopy record book of the department. Biopsies are taken with the biopsy forceps when indicated, and the reports are entered in the HPR book. If RS examination was incomplete or symptoms had not been explained satisfactorily by RS, colonoscopy was arranged subsequently. SPSS software (SPSS Inc. Released 2009, PASW Statistics for Windows, Version 18.0, Chicago, USA) was used for statistical analysis. Qualitative variables were expressed as frequencies and percentages while quantitative variables were expressed as mean and standard deviation (SD).

RESULTS

During the study period (July 2013–June 2018), 9418 examinations were done, and a total of 6921 abnormalities were picked up, giving a diagnostic yield of 73.5%. In our study, the mean age of patients was 48.7 ± 16.3 years. The male-to-female ratio was approximately 1.6:1. Most common indication for RS was bleeding PR (51%), followed by constipation (29%) and inflammatory bowel disease ulcerative colitis (IBD UC) to assess endoscopic activity (9%). Major disease (neoplasm, adenomatous polyp, and inflammatory bowel disease) was identified in 2834 (30%) patients and minor disease (hemorrhoids, solitary rectal ulcer syndrome [SRUS], nonadenomatous polyp, pin worm, and perianal disease) in 4087 (43.4%) of patients [Table 1].

The most common lesion found was hemorrhoids in 3748 patients (39.8%). Other diagnosis included proctitis in 1290 patients (13.7%), neoplasms in 914 patients (9.7%), polyps in 630 patients (6.7%), and solitary rectal ulcers in 226 patients (2.4%). Other findings such as rectal prolapse, pin worm infection, anal fissures, and fistula in ano accounted for 113 of patients (1.2%) while 2497 (26.5%) studies were normal. A total of 3298 (35%) patients underwent biopsies, of

which 727 (7.7%) were biopsy proven for carcinoma, 548 (5.8%) turned out to be adenoma, 12.2% were IBD UC, 2.2% turned out be SRUS, 1.2% nonspecific colitis, 1.7% nonneoplastic polyps, 8 patients were lymphoma, and 253 (2.7%) were normal while 126 (1.4%) were inconclusive [Figure 1]. Many times, biopsies were taken with RS when larger tissue bits were required or it was technically difficult as in near anal verge lesions or when FS biopsies from rectosigmoid lesions were inconclusive.

Thousand seven hundred and thirty-nine (98.5%) of the 4812 patients with complaints of bleeding PR had a diagnosis after RS, of which hemorrhoids (72.7%) was the most common cause followed by proctitis (14.2%), neoplasm (9%), and others (4.1%). The sensitivity,

specificity, positive predictive value, and negative predictive value of RS in detecting neoplasia was 98.2%, 96.8%, 66.1%, and 99.9%, respectively. The HPR was taken as the gold standard for calculating this. When RS was used for assessing activity in IBD UC, 94% patients had various grades of UC while 6% had normal study.

On studying the year-wise trends for 5 years, it was observed that hemorrhoids, IBD, and neoplasia showed a significant ($P < 0.05$) upward trend whereas other pathologies maintained almost a uniform distribution throughout 5 years [Figure 2]. The prevalence of neoplasia was highest in the 60–69 years age group although neoplasia was reported in ages as low as <30 years [Figure 3]. Of the 727 patients of neoplasia, 74 patients (10.2%) were detected in <40 years. There were no major complications like perforation or intractable bleeding in the study group. However, 35 patients (0.37%) had mild lower abdominal discomfort and 12 patients (0.12%) had minor ooze after biopsy which was self-limiting.

Table 1: Findings in the 9418 patients undergoing rigid sigmoidoscopy

Clinical characteristics	Frequency
Age	Mean 48.7±16.3 range 7-89
Sex	Male: Female=1.6:1
Depth of insertion (cm)	Mean 24±5 range 3-30
Indication for RS (%)	
Bleeding PR	4812 (51.1)
Constipation	2739 (29)
UC to assess activity	828 (8.8)
Abdominal pain	442 (4.7)
Mucus PR	329 (3.5)
Loose stools	207 (2.2)
Mass PR	57 (0.6)
Perianal itching	10 (0.1)
RS findings (%)	
Major disease	
Neoplasm	914 (9.7)
IBD UC	1290 (13.7)
Polyps	630 (6.7)
Minor disease	
Hemorrhoids	3748 (39.8)
SRUS	226 (2.4)
Others	113 (1.2)
Normal (%)	2497 (26.5)
Biopsy findings (%)	3298 (35)
Carcinoma	727 (7.7)
Adenoma	548 (5.8)
IBD UC	1151 (12.2)
SRUS	208 (2.2)
Nonspecific colitis	118 (1.2)
Nonneoplastic polyp	159 (1.7)
Lymphoma	8 (0.3)
Inconclusive	126 (1.4)
Normal	253 (2.7)
Biopsy not done	6120 (65)

SRUS=Solitary rectal ulcer syndrome, IBD=Inflammatory bowel disease, UC=Ulcerative colitis, PR=Per rectum, RS=Rigid sigmoidoscopy

DISCUSSION

RS can detect many lesions in the anorectal region, for example, hemorrhoids, polyps, cancer, and proctitis. As the volume of patients with anorectal symptoms attending our OPD is very high, we do this procedure quite often, as can be gauged by the number of procedures in the last 5 years (9418 RS procedures). Not many studies have been published from India on the sigmoidoscopic findings in the patients attending colorectal clinics. Studies on RS are still rarer given the fact that FS has become the norm everywhere.

Our study reported a diagnostic yield of 73.5% better than that reported by a previous study from India which was 67%.^[7] We found a diagnostic yield of 30% for major disease and 43.4% for minor disease which is almost similar to a study from UK with FS that reported yield of 22% for major disease and 53% for minor disease.^[8] The high diagnostic yield was due to the fact that patients presenting with lower GI

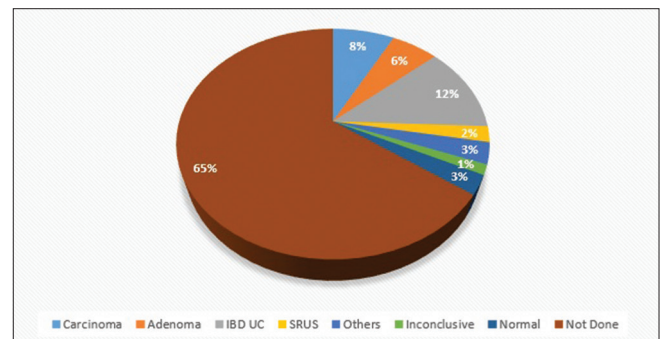


Figure 1: Distribution of rigid sigmoidoscopy biopsy findings over 5 years

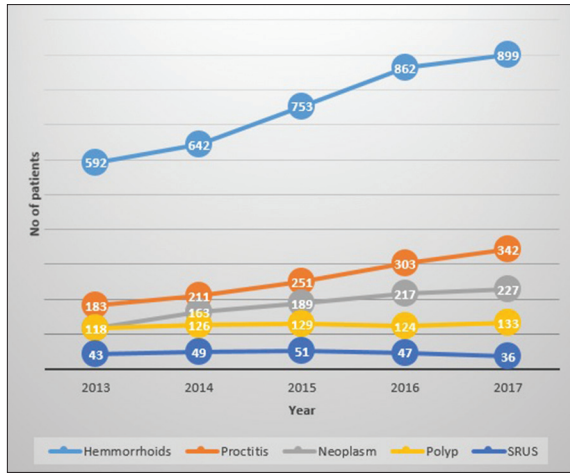


Figure 2: Trend of rigid sigmoidoscopy findings over 5 years

complaints were subjected to RS as the first step in the OPD itself.

The mean depth of insertion achieved was 24 ± 5 cm and range 3–30 cm, which is comparable to that quoted in earlier studies with FS where a distance of $27-4 \pm 9.9$ cm (mean \pm SD) from the anal verge (range 10–50 cm) was achieved.^[9] In our study, scope was passed up to 10 cm in 10%, up to or beyond 15 cm in 90%, beyond 20 cm in 74.5%, >25 cm in 37.5% which is comparable to a study by Winnan^[10] where the scope was passed up to or beyond 15 in 94%, 20 cm in 56%, and 25 cm in 43%. Thus most of the pathologies of the anal canal, rectum, and also part of sigmoid colon can be visualized with this procedure.

The most common indication for RS in our study was bleeding PR (51%), and the most common lesion found was hemorrhoids (39.8%). Most of such patients are referred after proctoscopy from department of surgery before embarking on surgical treatment for hemorrhoids, so as to rule out mass lesion in the rectosigmoid. Of the 4812 patients with complaints of bleeding PR, 4739 (98.5%) had a diagnosis after RS, of which hemorrhoids (72.7%) was the most common cause followed by proctitis (14.2%), neoplasm (9%), and others (4.1%).

The reported yield of RS for cancers has been varying between 4% and 12% in various studies.^[11,12] Bolt reported a yield of 2%–7% for benign polyps and 0.1%–2% of cancer in a study.^[4] Our study found adenoma in 5.8% and carcinoma in 7.7%, of which the most common was adenocarcinoma. The sensitivity, specificity, positive predictive value, and negative predictive value of RS in detecting neoplasia in patients with bleeding PR was 98.2%, 96.8%, 66.1%, and 99.9%, respectively. Thus, RS can be a valuable

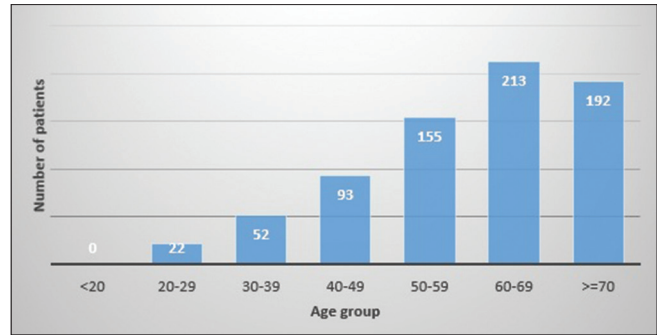


Figure 3: Prevalence of biopsy-proven malignancy by age

screening test to detect rectosigmoid malignancies in patients presenting with bleeding PR.

An alarming trend of neoplastic lesions of the rectosigmoid was found. The prevalence of neoplasia was highest in the 60–69 years age group although neoplasia was reported in patients <30 years of age also. Of the 727 patients of neoplasia, 74 patients (10.2%) were in <40 age group. Thus, our study refutes the study by Mathew *et al.*^[13] who described that people <45 years should not be subjected to endoscopic evaluations as the risk of developing cancer is very less in them. As per our study, no age group is spared from the neoplastic process and all patients with lower GI symptoms should be evaluated.

Malignant lesions picked up by RS were from the distal colon. Studies have shown that in such cases, there was a possibility of synchronous lesions higher up the bowel,^[14] hence all these patients were subjected to full length colonoscopy. In about 50% of the cases, the scope could not be progressed further due to luminal narrowing by the lesion.

RS is a valuable tool for assessing activity in IBD UC. Endoscopic assessment of the lesion in UC is important to guide therapy and also helps us to take biopsy to rule out clostridium difficile infections or cytomegalovirus infection when patients with UC come with recurrence of symptoms. Due to the ease of obtaining tissue for histopathology using RS in the OPD, the treatment process can begin without much delay. RS being performed as an OP test also helps us to expedite the process of evaluation of such a patient, while otherwise, he would have to wait a minimum of 3 days to get a date for FS.

On studying the year-wise trends for 5 years, it was observed that hemorrhoids, IBD UC, and neoplasia showed a significant ($P < 0.05$) upward trend whereas other pathologies maintained almost a uniform distribution throughout 5 years [Figure 2]. Explanations for this increasing trend in lower GI lesions are changes

in lifestyle and dietary habits. There is increased awareness in the public through social media about colorectal malignancies, and it may also have a role for early presentation to the colorectal clinics.

As per our study RS examination has a high diagnostic yield, hence we propose it as a first line investigation for patients at high risk of colorectal cancer and in asymptomatic patients found to have positive fecal occult blood tests. Although the gold standard investigation for colon cancer is colonoscopy, using it as an initial test, in every patient in our setting, is not feasible given the large number of patients coming for evaluation of lower GI symptoms. The equipment and its maintenance are costly, and it requires trained technicians. Perforation and bleeding sometimes accompany a colonoscopy, mandating additional hospital stays and at times, even surgery.^[15]

There are few limitations of our study. Being a retrospective study, we could not follow up the patients to assess whether the results of the RS were reconfirmed or refuted by further flexible endoscopic studies. The 5-year trend we found may not be representing the true scenario due to referral bias. Head-to-head comparison study with FS would be needed to establish the utility of RS in the OP setting.

CONCLUSION

We seek to emphasize the notion that RS is here to stay. It is too early to write off this easy but valuable OP procedure even though it is being labeled as an outdated procedure. In our study, we have detected that there is increase in the prevalence of neoplasia, IBD UC, and hemorrhoids over 5 years in this population of North Kerala. Arguments may be held that the patients who undergo RS are underinvestigated, but there are certain facts which should be noted:

1. RS is a simple procedure which can be easily learnt and can be done using instruments which are much less expensive than colonoscopy or FS
2. The diagnostic yield of RS at our center is good (73.5%), and the sensitivity and specificity of RS to detect rectosigmoid cancer is 98.2% and 96.8%; thus, it can be utilized as an effective diagnostic tool for screening of rectosigmoid cancers and other pathologies. RS is better than FS in taking biopsies owing to large biopsy bits obtained and also due to ease of use
3. This procedure was well tolerated by our patients with no reports of any major complications; hence, it can be positioned as a safe and simple OP procedure, requiring no sedation, which can be done even at

peripheral centers after adequate training of primary care physicians.

The extensive advantages of RS demonstrated in this study warrant consideration for its wider clinical application as a valuable investigative tool for the diseases of distal colon and rectum.

Financial support and sponsorship

Nil.

Conflicts of interest

There are no conflicts of interest.

REFERENCES

1. India against Cancer. Colorectal Cancer Risk Factors, Prevention, Pap Smear, Diagnosis, Treatment. India against Cancer; 2018. Available from: <http://cancerindia.org.in/colorectal-cancer/>. [Last accessed on 2017 Aug 24].
2. Levin B. Screening sigmoidoscopy for colorectal cancer. *N Engl J Med* 1992;326:700-2.
3. Goldsmith O, Frankl H, Gerety D, Masse C, Colbert P, Sanders P. Fiberoptic sigmoidoscopy in an asymptomatic population (Abstract). *Gastrointest Endosc* 1977;23:228.
4. Bolt RJ. Sigmoidoscopy in detection and diagnosis in the asymptomatic individual. *Cancer* 1971;28:121-2.
5. Gilbertsen VA. Proctosigmoidoscopy and polypectomy in reducing the incidence of rectal cancer. *Cancer* 1974;34:936-9.
6. Winawer SJ, Leidner SD, Boyle C, Kurtz RC. Comparison of flexible sigmoidoscopy with other diagnostic techniques in the diagnosis of rectocolon neoplasia. *Dig Dis Sci* 1979;24:277-81.
7. Khan T, Hafiz A, Nazir B, Shaheen N, Yasir M, Khan H. A retrospective study of sigmoidoscopic examination with rigid sigmoidoscope in a medical school sigmoidoscopy center. *J Islam Med Assoc North Am* 2008;40:76-81.
8. Vipond MN, Moshakis V. Four-year evaluation of a direct-access fibreoptic sigmoidoscopy service: Authors' reply. *Ann R Coll Surg Engl* 1996;78:397-98.
9. Vellacott KD, Harcastle JD. An evaluation of flexible fibreoptic sigmoidoscopy. *Br Med J (Clin Res Ed)* 1981;283:1583-6.
10. Winnan G, Berci G, Panish J, Talbot TM, Overholt BF, McCallum RW, et al. Superiority of the flexible to the rigid sigmoidoscope in routine proctosigmoidoscopy. *N Engl J Med* 1980;302:1011-2.
11. Vellacott KD, Roe AM, Mortensen NJ. An evaluation of a direct access flexible fibreoptic sigmoidoscopy service. *Ann R Coll Surg Engl* 1987;69:149-52.
12. Kalra L, Price WR, Jones BJ, Hamlyn AN. Open access fibresigmoidoscopy: A comparative audit of efficacy. *Br Med J (Clin Res Ed)* 1988;296:1095-6.
13. Mathew J, Shankar P, Aldean IM. Audit on flexible sigmoidoscopy for rectal bleeding in a district general hospital: Are we over-loading the resources? *Postgrad Med J* 2004;80:38-40.
14. Read TE, Read JD, Butterly LF. Importance of adenomas 5 mm or less in diameter that are detected by sigmoidoscopy. *N Engl J Med* 1997;336:8-12.
15. Detsky AS. Screening for colon cancer – Can we afford colonoscopy?. *N Engl J Med* 2001;345:607-8.