Article published online: 2021-07-27

Utility of diffusion weighted imaging in diagnosing subdiaphragmatic endometriosis presenting as shoulder pain

Anuradha Singh, Chandan J Das, Bimal K Das[1], A K Gupta
Departments of Radiology, [1]Microbiology, AIIMS, New Delhi, India

Correspondence: Dr. Chandan J Das, Department of Radiology, AIIMS, New Delhi - 110 029, India. E-mail: dascj@yahoo.com

Abstract

Extrapelvic endometriosis (EPE) is a rare entity which may potentially occur at any site. Symptomatic EPE is now increasingly being managed laparoscopically. Imaging is imperative in diagnosis as well as extent delineation prior to surgery. In addition to increasing the success rate of diagnostic laparoscopy, prior knowledge of EPE at certain sites may modify the standard surgical technique. We present here an unusual case of chronic pain in the right shoulder in a 26-year-old female caused by subdiaphragmatic endometriosis (SDE). It was noticed on conventional magnetic resonance imaging (MRI) sequences; however, due to the lack of the characteristic signal intensity, imaging findings were noncontributory. Diffusion-weighted imaging (DWI) facilitated its characterization and precisely mapped the extent of involvement. SDE should be suspected in young females presenting with cyclical shoulder pain. Due to nonspecific clinical features, it may remain undiagnosed. MRI is the imaging modality of choice in evaluation of EPE. Including DWI sequence in the MR protocol increases the diagnostic precision besides delineating the extent of involvement noninvasively.

Key words: Extrapelvic; laparoscopy; magnetic resonance imaging

Introduction

Endometriosis refers to the presence of functioning endometrial glands and stroma outside the uterine cavity. An estrogen responsive condition, its incidence is approximately 8–15% in the females of reproductive age group.[1] Endometriosis implants are usually present in the pelvis, commonly involved sites being the ovaries, uterosacral and broad ligaments of uterus, bladder and pelvic bowel loops. Rarely, there may be involvement of extrapelvic sites such as bowel surface, umbilicus or skin. Even rarer, there may be involvement of the diaphragm.[1]

Endometriosis is suspected by the characteristic history of cyclical pain coinciding with the menses; however, at extrapelvic sites dilemma may occur as the classical history may be overlooked due to other nonspecific manifestations pertaining to the site of implantation. We present here an interesting case of chronic dull aching pain in a young female caused by subdiaphragmatic endometriosis (SDE). It was clinically presumed to be of musculoskeletal origin

Access this article online	
Quick Response Code:	Website: www.ijri.org
	DOI: 10.4103/ijri.IJRI_86_16

Cite this article as: Singh A, Das CJ, Das BK, Gupta AK. Utility of diffusion weighted imaging in diagnosing subdiaphragmatic endometriosis presenting as shoulder pain. Indian J Radiol Imaging 2017;27:314-7.

and remained undiagnosed for a long time. The condition was detected incidentally while performing magnetic resonance imaging (MRI) of the shoulder joint. Including diffusion-weighted imaging (DWI) in the imaging protocol aids in better visualization and characterization of endometriotic lesions.

Case Report

A 26-year-old nulliparous female presented to the orthopaedics outpatient clinic with chronic dull aching pain in the right shoulder which was unrelated to movements or weight bearing. There was no history of antecedent trauma, surgery or significant weight bearing. X-ray of the shoulder joint and cervical spine was normal. The patient had received conservative treatment for 4 years.

In view of the persistent symptoms, MRI of the shoulder joint was done which was normal. However, there was a circumscribed plaque-like crescentric subphrenic lesion (maximum thickness approximately 5 mm) along the posterosuperior surface of the right lobe of the liver. It was hypointense on T1-weighted imaging (WI) [Figure 1A] and mildly hyperintense on T2WI [Figure 1B and C]. For its further characterization, DWI (b = 0, 400, 800) was done [Figure 2], on which it was hyperintense along with the patchy hypointensity on the corresponding apparent diffusion coefficient (ADC) map. There was no trans-diaphragmatic extension of the lesion in the pleural cavity. Signal characteristics of the subdiaphragmatic lesion were nonspecific on conventional MRI. However, due to the T2 hyperintensity and patchy diffusion restriction, hemorrhagic content was suspected raising the possibility of the SDE. Further abdominopelvic evaluation revealed extensive deep pelvic endometriosis [Figure 1D]. No significant lymphadenopathy, ascites or pleural effusion was present. The patient later confirmed the cyclical nature of her shoulder pain along with the history of severe dysmenorrhea, further supporting the diagnosis of SDE.

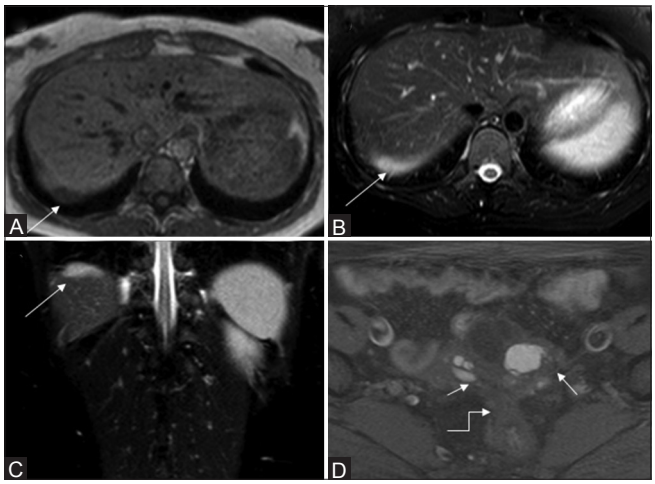

Figure 1 (A-D): (A) Axial T1 images of upper abdomen showing a circumscribed lesion (arrow) in the right subphrenic region along the posterior surface of the right lobe of liver. On T2W fat saturated images (B and C), it is hyperintense. (D) Axial T1 fat suppressed image of the pelvis showing extensive bilateral pelvic endometriosis with bilateral endometriomas (arrow). Additionally, hypointense endometriosis implant in the rectouterine pouch can be seen (curved arrow)

Despite laparotomy being the preferred treatment in endometriosis, laparoscopy was done as the patient was nulliparous. With the preoperative diagnosis of SDE, there was change in the standard laparoscopic technique from the standard two to three port incision. Plaque-like endometriotic implant was present under the right hemidiaphragm. It was involving its partial thickness, which was then electrocoagulated. There was no pneumothorax. Postoperative period was uneventful and the patient was discharged after 5 days. After discharge, medical management was continued with combined oral contraceptive pills and GnRH agonists. On follow-up, patient was relieved of the shoulder pain; however, there was persistence of the dysmenorrhea.

Discussion

Endometriosis is a common cause of dysmenorrhea, infertility and dyspareunia in the females of reproductive age group. Usually, endometriosis implants are present in the pelvis and most commonly involve the ovaries (also referred as endometriomas); however, it can occur at other extrapelvic sites.[1-4] Endometriosis is postulated to be the result of retrograde menstruation leading to the tracking of the menstrual blood along the usual pathways of circulation of the peritoneal fluid, which explains the pelvic preponderance of these implants.[5]

SDE is an extremely rare entity and is usually seen concomitantly with deep pelvic endometriosis.[2,4,5] It may remain asymptomatic or can lead to cyclical pain in the

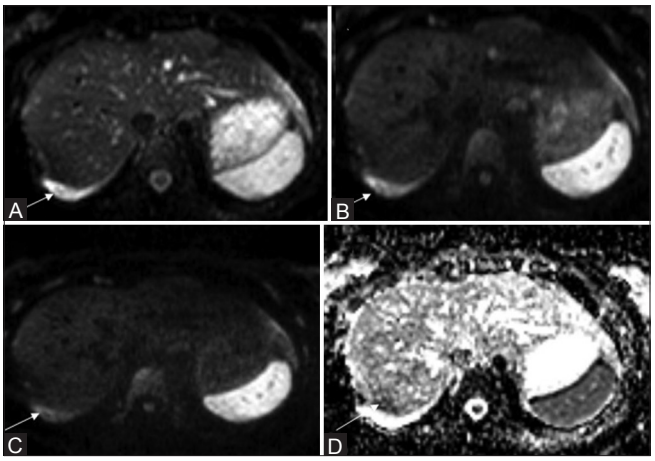

Figure 2 (A-D): (A-C) Diffsion weighted imaging at b = 0, 400, and 800 shows lesion to be hyperintese (arrow) with patchy hypointensity on ADC images (D) suggestive of restricted diffusion

epigastrium, chest, or occasionally manifests as referred pain to the shoulder.[4,5]

SDE, similar to other extrapelvic sites, may remain elusive on imaging. Its diagnosis is usually established on the surgery performed either based on clinical suspicion or incidentally during the exploration performed for the endometriosis implants elsewhere. SDE implants may be either superficially adherent to the under surface of the diaphragm or there can be transmural involvement, leading to the catamenial pneumo or hemothorax. Such potential life threatening complications makes this condition a definite indication for surgery, unlike at other sites, which are initially managed conservatively. Laparotomy is the mainstay of treatment in endometriosis. However, minimally invasive laparoscopic techniques are preferred wherever feasible, especially in indeterminate cases due to less morbidity. However, SDE is one of the extrapelvic sites where laparotomy is favored over laparoscopy. This is explained by the optimal visualization of the posterior part of the diaphragm due to the adequate mobilization of the liver during laparotomy, which otherwise may remain hidden on the laparoscopy performed through standard conventional umbilical port.

Despite SDE being a definite surgical indication, pre-operative diagnosis is beneficial as it ensures complete resection in addition to modifying the surgical technique. Ultrasonography has poor sensitivity in the diagnosis of SDE due to the reverberation artefacts from the air-filled lung parenchyma, especially if the implants are of smaller size. MRI is the imaging modality of choice in suspected endometriosis including EPE due to its superior contrast resolution and multiplanar capabilities.[6] In a classical case, endometriosis is usually hyperintense on T1WI due to subacute hemorrhage with hypointesity on T2WI. This hypointensity on T2WI, also referred as "T2 shading" occurs due to repeated hemorrhages with consequent differential settling of blood depending on its stage of evolution. Quite striking in endometriosis is the T2 hypointense rim, which occurs due to hemosiderin deposition. However, this classical finding is usually seen in endometriomas whereas deep pelvic or EPE may have variable signal intensity and are usually hypointense on both T1 and T2 due to intense desmoplastic reaction with fibromuscular proliferation. Enhancement pattern of endometriosis is nonspecific and is governed by the relative propensity of inflammation, glandular, and fibrotic component.[3,7]

Recent times have witnessed a tremendous surge in exploring the potentialities of DWI in gynecological neoplasms as elsewhere in the body. DWI is based on the random motion of molecules, which if altered [for e.g. if the lesion is hypercellular or viscous (hemorrhagic or proteincaeous products)] will result in hyperintense signal. Restricted diffusion in endometriosis is probably due to the intracystic blood clots; however, relatively low T2 signal intensity (T2 shading) also contributes to the ADC hypointesity. In pelvis, few benign (mature cystic teratoma, functional hemorrhagic ovarian cyst) and malignant adnexal neoplasms may also show restricted diffusion. Hence, DWI has a limited role in differentiating these lesions from endometrioma, although ADC calculation may help in certain situations. However, DWI is of utmost utility and may serve as a confirmatory investigation in establishing the diagnosis of extrapelvic endometriosis. Moreover, in cases with peritoneal dissemination, it enhances the visibility of smaller implants, especially in the backdrop of ascites or other fluid-containing structure; thus, making it a fairly specific investigation. Moreover, it may help in the identification of the hemorrhagic contents, especially if the signal intensity on the conventional MRI is not characteristic.[3,8-10]

Most of the cases of SDE reported in literature till date were diagnosed during surgical exploration with the pre-emptive suspicion based on the cyclical nature of symptoms. Most of these lesions were multifocal and in some cases involved the bilateral hemidiaphragm. In few cases, such noncontiguous involvement was initially missed during the surgery leading to the persistence or recurrence of the symptoms.[5] Conventional MRI sequences have been used preoperatively in certain cases;[5,10] however, to the best of our knowledge, this is the first reported case in literature highlighting the utility of DWI as a useful aid in diagnosing EPE.

We suggest that DWI should be included in the routine MRI protocol for the evaluation of endometriosis, especially for diagnosing and mapping the extent of extrapelvic disease. It may help in the better disease evaluation in substantiation with clues from the symptomatology as well as signal intensity on the conventional MRI. Furthermore, DWI is highly beneficial in diagnosing extrapelvic endometriosis, especially if implant is of small size. Furthermore, clinicians needs to be familiar with the unusual manifestations of the EPE which should be suspected in young females with cyclical symptoms.

Financial support and sponsorship

Nil.

Conflicts of interest

There are no conflicts of interest.

References

1. Wolthuis AM, Aelvoet C, Bosteels J, Vanrijkel JP. Diaphragmatic endometriosis: Diagnosis and surgical management-a case report. Acta Chir Belg 2003;103:519-20.
2. Redwine DB Diaphragmatic endometriosis: Diagnosis, surgical management, and long-term results of treatment. Fertil Steril 2002;77:288-96.

3. Coutinho A Jr, Bittencourt LK, Pires CE, Junqueira F, Lima CM, Coutinho E, *et al*. MR imaging in deep pelvic endometriosis: A pictorial essay. Radiographics 2011;31:549-67.
4. Ceccaroni M, Roviglione G, Rosenberg P, Pesci A, Clarizia R, Bruni F, *et al*. Pericardial, pleural and diaphragmatic endometriosis in association with pelvic peritoneal and bowel endometriosis: A case report and review of the literature. Wideochir Inne Tech Maloinwazyjne 2012;7:122-31.
5. Vercellini P, Abbiati A, Vigano P, Somigliana ED, Daguati R, Meroni F, *et al*. Asymmetry in distribution of diaphragmatic endometriotic lesions: Evidence in favour of menstrual reflux theory. Hum Reprod 2007;22:2359-67.
6. Chamié LP, Blasbalg R, Pereira RM, Warmbrand G, Serafini PC. Findings of pelvic endometriosis at transvaginal US, MR imaging, and laparoscopy. Radiographics 2011;31:E77-100.
7. Woodward PJ, Sohaey R, Mezzetti TP. Endometriosis: Radiologic–pathologic correlation. Radiographics 2001;21:193-216.
8. Fujii S, Kakite S, Nishihara K, Kanasaki Y, Harada T, Kigawa J, *et al*. Diagnostic accuracy of diffusion-weighted imaging in differentiating benign from malignant ovarian lesions. J Magn Reson Imaging 2008;28:1149-56.
9. Namimoto T, Awai K, Nakaura T, Yanaga Y, Hirai T, Yamashita Y. Role of diffusion-weighted imaging in the diagnosis of gynecological diseases. Eur Radiol 2009;19:745-60.
10. Siegelman ES, Oliver ER. MR imaging of endometriosis: Ten imaging pearls. Radiographics 2012;32:1675-91.