Article published online: 2021-07-27

Comment on: Percutaneous retrograde approach for mesenteric revascularization in chronic mesenteric ischemia

Sir,

We read with a great interest the manuscript titled "Percutaneous transluminal angioplasty and stenting in the management of chronic mesenteric angina: A single center experience" by Thomas *et al*.[1] in the October–December 2016 issue of the Indian Journal of Radiology and Imaging (Volume 26, Issue 4). The manuscript is intelligently written with a beautiful depiction of the technique of endovascular management of patients with chronic mesenteric angina along with self-explanatory images. We would like to make a pertinent contribution.

In their study cohort of 13 patients, the authors managed the stenotic mesenteric vessel using percutaneous transluminal angioplasty/stenting with good clinical outcomes. Chronic mesenteric ischemia (CMI) is usually caused by obstruction of two or all three mesenteric arteries; moreover, multiple vessel revascularizations improve clinical outcomes.[2] In many cases, as the authors mentioned, there is chronic total occlusion of at least one of the mesenteric vessel, which is difficult to cross endovascularly by the antegrade approach. However, to optimize the outcomes, even the completely occluded vessels may need to be revascularized, which may need alternative methods such as the retrograde transcollateral approach.[2,3] We wish to highlight the management of chronic total occlusion of mesenteric vessel using retrograde revascularization technique, providing an

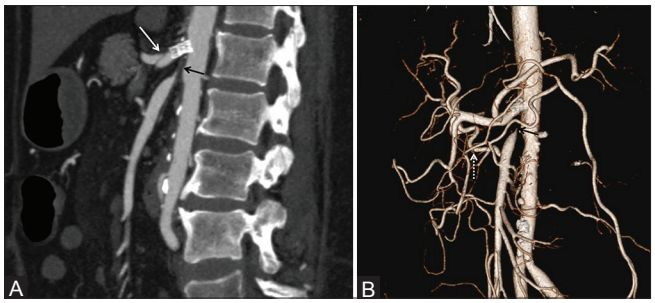

Figure 1 (A and B): Sagittal reconstructed (A) and oblique 3D volume rendered technique (B) images of CT abdominal angiogram showing mild in-stent restenosis of coeliac artery stent with dissection flap (solid white arrow) in coeliac artery distal to stent with short segment complete total occlusion of proximal superior mesenteric artery (black arrows) and hypertrophied collateral in pancreatic-duodenal arcade (dashed white arrow)

additional technique of endovascular management of chronic mesenteric angina.

Retrograde recanalization is based on the different histopathology of proximal and distal fibrous caps of chronic occlusions. The proximal cap has densely concentrated collagen-rich fibrous tissue whereas at the distal cap the tissue is loose. In addition, the distal cap has a convex shape in its proximal aspect increasing the chances of subintimal dissection when the wire is passed antegradely; however, have concave shape on its distal aspect facilitating penetration by wires from the retrograde direction.[2]

A 55-year-old female with symptoms of CMI was treated with coeliac artery percutaneous transluminal angioplasty/stenting elsewhere 6 months previously and presented with weight loss and recurrence of postprandial abdominal pain. Computed tomography (CT) abdominal angiogram showed mild in-stent restenosis of coeliac artery stent with dissection flap [Figure 1A, solid white arrow] in coeliac artery distal to stent. There was short segment complete total occlusion of the proximal superior mesenteric artery [Figure 1A and B, black arrows] for a length of 1.3 cm. Also noted was hypertrophied collateral in the pancreatic-duodenal arcade [Figure 1B, dashed white arrow]. On enquiry, there was a history of previous failed attempt of superior mesenteric artery (SMA) stenting. In view of the severe clinical symptoms and complete occlusion of SMA, endovascular revascularization of SMA using retrograde approach via pancreatic-duodenal arcade was sought.

Bilateral femoral accesses were taken and 6-Fr femoral sheaths were inserted using the seldinger technique. Flush aortogram showed flush occlusion of the proximal superior mesenteric artery with no evidence of a stump (precluding antegrade recanalization) and dissection with in-stent restenosis of 60% in coeliac trunk. Cobra (C2) (Terumo, New Jersey, USA) catheter was used to selectively cannulate coeliac trunk. 2.7-Fr progreat microcatheter (Terumo, New

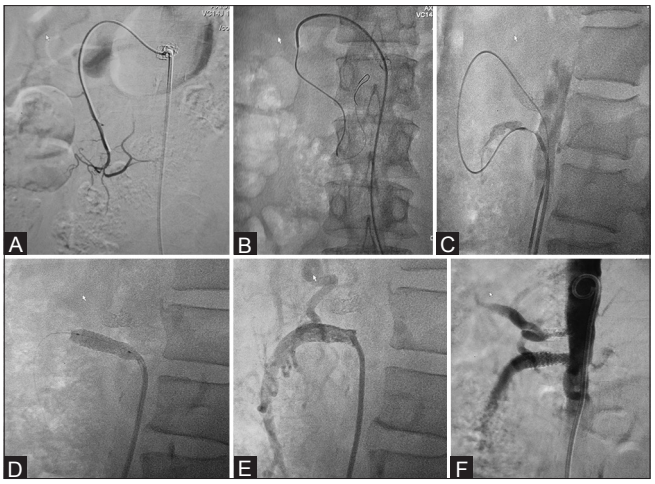

Figure 2 (A-F): Fluoroscopic images showing selective cannulation of gastroduodenual artery via the true lumen of coeliac trunk (A). The microcatheter and wire assembly was further negotiated into SMA using collateral arcade (B). Angiographic image showing wire loop in coeliac trunk-pancreaticoduodenal arcade-SMA passed using retrograde approach with 6 Fr guiding catheter passed till the ostium of SMA (C). A balloon expandable stent being deployed across the level of narrowing (D). Post stenting angiography showing patency of SMA with good antegrade flow in mesenteric branches of SMA (E and F)

Jersey, USA) was negotiated via the true lumen of coeliac trunk into gastroduodenual artery [Figure 2A]. Using the roadmap injection of pancreatic-duodenal arcade, microcatheter and wire assembly was further negotiated into inferior pancreatico-duodenal artery and finally into SMA proximal to inferior pancreatico-duodenal artery [Figure 2B]. A 300-cm long 0.014" balance middleweight (Abott vascular, Santa Clara, California, USA) wire was passed through the microcatheter across the occluded segment of SMA into the aorta and then snared out through the left femoral sheath using 10 mm gooseneck snare (Medtronic, Minneapolis, Minnesota, USA). Over the snared wire, a 6-Fr guiding catheter was passed till the ostium of SMA [Figure 2C], and angioplasty was done using 2.5 × 12 mm Maverick balloon catheter (Boston scientific, Marlborough, MA, USA). A 0.035" glide wire (Terumo, New Jersey, USA) was passed across the SMA antegradely, and a 7 mm × 19 mm express vascular SD stent (Boston scientific, Marlborough, MA, USA) was deployed across the level of narrowing [Figure 2D]. Post stenting, intraprocedure angiography showed patency of SMA with good antegrade flow, no dissection, and brisk filling of the right colic, ileocolic, and jejunal branches of SMA [Figure 2E and F]. The patient had complete resolution of symptoms in 3 days and is on regular clinical follow-up for the last 2 years with no recurrence of CMI symptoms.

Financial support and sponsorship
Nil.

Conflicts of interest
There are no conflicts of interest.

Suresh Giragani, Ankit Balani, D Prabakar[1], Viswanath Reddy[2]

Departments of Interventional Radiology, [1]Vascular Surgery, [2]Gastroenterology, Yashoda Hospital, Hyderabad, Telangana, India
E-mail: drankitbalani@gmail.com

References

1. Thomas T, Kader N, Prabhu N, Kannan R, Pullara S, Moorthy S. Percutaneous transluminal angioplasty and stenting in the management of chronic mesenteric angina: A single center experience. Indian Journal of Radiology and Imaging. 2016;26(4):460-5.
2. Joseph G, Chacko ST. Percutaneous retrograde recanalization of the celiac artery by way of the superior mesenteric artery for chronic mesenteric ischemia. Cardiovascular and interventional radiology. 2013;36(1):259-63.
3. Stephens JC, Cardenas G, Safian RD. Percutaneous retrograde revascularization of the superior mesenteric artery via the celiac artery for chronic mesenteric ischemia. Catheterization and cardiovascular interventions: Official journal of the Society for Cardiac Angiography & Interventions. 2010;76(2):222-8.

This is an open access article distributed under the terms of the Creative Commons Attribution-NonCommercial-ShareAlike 3.0 License, which allows others to remix, tweak, and build upon the work non-commercially, as long as the author is credited and the new creations are licensed under the identical terms.

Access this article online

Quick Response Code:

Website: www.ijri.org

DOI: 10.4103/ijri.IJRI_73_17

Cite this article as: Giragani S, Balani A, Prabakar D, Reddy V. Comment on: Percutaneous retrograde approach for mesenteric revascularization in chronic mesenteric ischemia. Indian J Radiol Imaging 2017;27:363-5.

© 2017 Indian Journal of Radiology and Imaging | Published by Wolters Kluwer - Medknow