

Back to the basics: Study of portable chest radiographic findings in 116 COVID-19 positive patients in an Indian tertiary care hospital

Parul Dutta, Zohra Ahmad, Mandeep Sagar, Rupjyoti Nath, Rahul C M

Department of Radiology, Gauhati Medical College, Guwahati, Assam, India

Correspondence: Dr. Zohra Ahmad, F1 IAS Colony Khanapara, Guwahati - 781 022, Assam, India. E-mail: zohraahmad@gmail.com

Abstract

Context: Paucity of literature of portable CXR findings in COVID-19. **Aims:** Evaluate radiographic findings in COVID-19 patients and calculate sensitivity of radiographs with RT-PCR as gold standard. **Subjects and Methods:** Total 116 COVID-19 patients underwent portable CXR between April-June, 2020. Two radiologists reviewed radiographs with respect to laterality, craniocaudal, mediolateral distribution, shape, density, unifocality/multifocality and number of lung zones. Sensitivity of radiography was calculated with RT-PCR as gold standard. **Statistical Analysis Used:** IBM SPSS Statistics Subscription software (IBM, New York, USA). **Results:** Many patients 67.2% (78/116) were asymptomatic. Cough (21.5%, 25/116) and fever (17.6%, 20/116) were the most frequent symptoms. 36.2% (42/116) patients revealed COVID-19 pneumonia-like abnormalities on CXR. Sensitivity of CXR with RT-PCR as gold standard was 36.2% (CI: Confidence interval = 27.46% - 44.95%). More patients in symptomatic group (68.4%, 26/38) had abnormal CXR compared to asymptomatic group (20.5%, 16/78) [$P < 0.0001$]. Radiographs revealed both unilateral (57.1%, 24/42), bilateral (42.8%, 18/42), GGO (80.9%, 34/42), or consolidation (11/42, 26.1%) in a middle (57.1%, 24/42), lower zone (83.3%, 35/42) and peripheral distribution (78.5%, 33/42). Lesions were commonly patchy (88%, 37/42) and multifocal (59.5%, 25/42). Majority had single (40.4%, 17/42) or two zone (35.7%, 15/42) involvement. **Conclusions:** Significant number of COVID-19 patients were asymptomatic. Over 1/3rd of patients showed radiographic abnormalities. Symptomatic patients were more likely to show radiographic findings than asymptomatic patients. If radiographs identify pneumonia in appropriate clinical setting, CT can be avoided. Common radiographic abnormalities among COVID 19 patients were bilateral/unilateral, patchy, multifocal, ground glass opacity or consolidation in peripheral and middle/lower zone distribution.

Key words: COVID-19; portable chest radiograph; pneumonia

Introduction

Coronavirus disease-19 (COVID-19) is a new global pandemic of viral pneumonia with common symptoms of fever, cough, and dyspnea, with high mortality in patients

with comorbidities and elderly age.^[1] This outbreak can be traced to a cluster of 27 pneumonia cases with unknown

This is an open access journal, and articles are distributed under the terms of the Creative Commons Attribution-NonCommercial-ShareAlike 4.0 License, which allows others to remix, tweak, and build upon the work non-commercially, as long as appropriate credit is given and the new creations are licensed under the identical terms.

For reprints contact: WKHLRPMedknow_reprints@wolterskluwer.com

Cite this article as: Dutta P, Ahmad Z, Sagar M, Nath R, Rahul CM. Back to the basics: Study of portable chest radiographic findings in 116 COVID-19 positive patients in an Indian tertiary care hospital. Indian J Radiol Imaging 2021;31:S148-53.

Received: 29-Jun-2020

Revised: 17-Jul-2020

Accepted: 17-Jul-2020

Published: 23-Jan-2021

Access this article online

Quick Response Code:



Website:
www.ijri.org

DOI:
10.4103/ijri.IJRI_550_20

etiology in Wuhan, China in December 2019 from where it spread worldwide over a period of months.^[2]

In radiology, the literature has focused primarily on computed tomography findings of COVID-19^[3-6] However, due to infection control issues, the need of serial X-rays in sick patients and those admitted in ICUs, and the difficulties in CT room decontamination, portable chest radiography (CXR) has been the most commonly utilized modality in this pandemic,^[7] especially in low-resource settings. Patients often need serial follow up to see the progression of the disease, which can be most effectively done by portable chest radiographs. As the prevalence of COVID-19 increases, it is also imperative for clinicians of all specialties to recognize COVID-19 features on CXR that may be performed for other purpose. Few studies which have described CXR findings in COVID-19 positive cases are ground glass densities, bilateral lower lobe consolidations, peripheral air space opacities and diffuse air space disease. The studies which have described CXR findings are only three till date with a maximum patient count of 64.^[8-10]

Subjects and Methods

We performed a retrospective observational study of 116 COVID-19 positive patients admitted in a tertiary care Indian hospital in a state capital between April 1 to June 10, 2020. The retrospective study was approved by our Institutional review board. COVID-19 infections were confirmed through a reverse transcriptase polymerase chain reaction (RT-PCR) assay of nasopharyngeal swabs and throat swabs.

We aimed to describe the radiographic findings in 116 COVID-19 positive patients and determine the sensitivity of radiography with RT-PCR as the gold standard diagnostic test. All CXRs were acquired using an Allegers Mars 15-30 portable CXR machine in the isolation wards. Chest radiographs (CXR) were acquired in the anteroposterior (AP) projection during the course of hospitalization. Two radiologists (P.D, general radiologist with 30 years of experience, Z.A. general radiologist with 7 years of experience) reviewed all the CXRs separately and were blinded to the clinical details. Any discrepancy was resolved with consensus later.

Distribution and characteristics of the lung changes on chest radiographs was categorized into:

- (1) Laterality: Right, left, or bilateral lung involvement
- (2) Mediolateral distribution: Peripheral predominance, central predominance, or no predominance
- (3) Craniocaudal distribution: Upper zone, mid or lower zone demarcated by upper 1/3rd, middle 1/3rd, and lower 1/3rd of the lung
- (4) Shape of opacity—patchy, nodular, or confluent
- (5) Density—Consolidation or ground glass opacity

- (6) Unifocal or multifocal
- (7) Number of zones involved
- (8) Presence or absence of pleural effusion

Statistical analysis

Statistical analysis was performed with IBM SPSS Statistics Subscription software (IBM, New York, USA). The sensitivity of CXR was calculated considering that CXR was done during the course of admission and which were interpreted as abnormal/or COVID-19 pneumonia, which were then compared to the RT-PCR results by Pearson Chi-squared test, the confidence interval was obtained too. In this study, we also looked for any statistical significance in the number of abnormal CXRs among the symptomatic and asymptomatic groups applying Pearson Chi-squared test. Statistical significance was defined as $P < 0.05$.

Results

Patient characteristics

83.6% (97/116) of the patients were males and 16.4% females (19/116) with a mean age of 32 years (range 2 months to 72 years). In our cohort, a large proportion of patients, (78/116 patients – 67.2%) were asymptomatic. Cough (25/116, 21.5%) and fever (20/116, 17.6%) were the two most frequent symptoms, followed by sore throat (7/116, 6%). Twenty-nine patients had at least one known comorbidity. The most common comorbidities were diabetes (9.5%) and hypertension (6.8%). All our patients were admitted to isolation wards except for two, who were admitted in ICU, one of whom later succumbed to the illness [Table 1].

Chest X-ray features

Forty-two patients (36.2%) demonstrated pneumonia-like abnormalities on CXRs at some point during hospital stay. Seventy patients (60.3%) demonstrated normal radiographs while four patients demonstrated findings not related to pneumonia. Among them, two patients revealed bilateral basal emphysema, one patient revealed fibro-bronchiectatic changes, and one patient revealed a lung cavitory lesion which was presumed to be a preexisting lesion. The sensitivity of CXR with RT-PCR as the gold standard was therefore 36.2% [CI Confidence interval = 27.46-44.95%]. None of the patients had pleural effusion.

The symptomatic group showed higher proportion of CXR abnormality (26/38, 68.4%), compatible with COVID pneumonia, than in the asymptomatic group (16/78, 20.5%). This difference was statistically significant ($P < 0.0001$).

Unilateral lung involvement was more common (57.1%, 24/42 patients with abnormal radiographs) than bilateral involvement (42.8%, 18/42) [Figures 1 and 2]. Peripheral distribution (78.5%, 33/42) was most common while central distribution and neither central/peripheral distribution

Table 1: Clinical Details (n=116)

| | Percentage (number of patients) |
|--|---------------------------------|
| Gender | |
| Male | 83.6 (97/116) |
| Female | 16.4 (19/116) |
| Age | |
| 0-10 | 3.4 (4/116) |
| 10-20 | 8.6 (10/116) |
| 20-30 | 48.3 (56/116) |
| 30-40 | 12.1 (14/116) |
| 40-50 | 6.8 (8/116) |
| 50-60 | 11.2 (13/116) |
| 60-70 | 7.7 (9/116) |
| >70 | 1.7 (2/116) |
| Clinical feature | |
| Fever | 17.2 (20/116) |
| Cough | 21.6 (25/116) |
| Sore throat | 6 (7/116) |
| Myalgia | 5.2 (6/116) |
| Dyspnea | 8 (5/116) |
| Diarrhea | 5.1 (1/116) |
| Asymptomatic | 67.2 (78/116) |
| Comorbidities | |
| Hypertension | 6.8 (8/116) |
| Diabetes mellitus | 9.5 (11/116) |
| Malignancy | 2.6 (3/116) |
| Chronic obstructive airway disease or asthma | 1.7 (2/116) |
| Chronic liver disease | 0.8 (1/116) |
| Chronic kidney disease | 0.8 (1/116) |
| Down syndrome | 0.8 (1/116) |
| Neuromyelitis optica | |

was found in 0% (0 in 42) and 21.4% (9/42) patients, respectively [Figures 3 and 4]. Lower zone involvement was most common (83.3%, 35/42), followed by mid zone (57.1%, 24/42) and upper zone involvement (7%, 3/42). The most common shape of radiographic lesion was patchy (88%, 37/42) followed by confluent (9.5%, 4/42) and nodular (4.7%, 2/42) [Table 2]. Lesions were more commonly multifocal (59.5%,

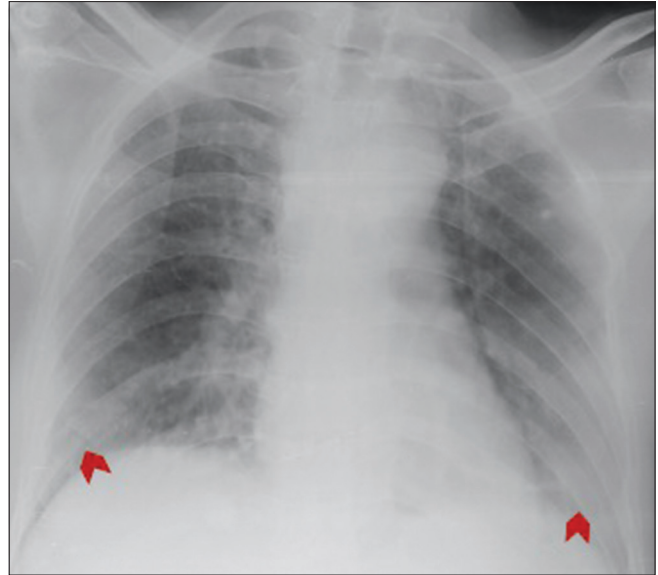


Figure 1: Asymptomatic, 60 year old male with hepatocellular carcinoma. CXR revealed patchy, bilateral, lower and left mid zone peripheral ground glass opacities (red arrowheads)

Table 2: Summary of chest radiographic findings

| Chest X-ray Findings (n=42) | Description | Percentage (number of patients/total number of patients with abnormal CXR) | Wong <i>et al.</i> ^[1] n=64 | Yoon <i>et al.</i> ^[2] n=10 | Lomoro <i>et al.</i> ^[3] n=32 |
|-----------------------------|---------------------------------|--|--|--|--|
| Laterality | Right lung | 9.5% (4/42) | 20%(10 patients) | 50% (5) | 6.2% (2) |
| | Left lung | 47.6% (20/42) | 18% (9) | 50% (5) | |
| | Bilateral | 42.8% (18/42) | 63%(32) | | 78.1% (25) |
| Crano-caudal distribution | Upper lung zone | 7% (3/42) | 0 | 20% (2) | 3.1% (1) |
| | Middle lung zone | 57.1% (24/42) | | 30% (3) | |
| | Lower lung zone | 83.3% (35/42) | 63%(32) | 50% (5) | 46.9% (15) |
| | No predominance | - | 37% (19) | | (50%) 16 |
| Mediolateral distribution | Central half | 0% (0/42) | 12%(6) | 20% (2) | |
| | Peripheral half | 78.5% (33/42) | 51%(26) | 60% (6) | |
| | No predominance | 21.4% (9/42) | 37%(19) | 20% (2) | |
| Shape | Patchy | 88% (37/42) | | 90% (9) | |
| | Nodular | 4.7% (2/42) | | 10% (1) | |
| | Confluent | 9.5% (4/42) | | | |
| Density | Consolidation | 26.1% (11/42) | 59%(30/64) | 80% (8) | 46.9%(15) |
| | Ground-glass lesion or haziness | 80.9% (34/42) | 41%(21/64) | 20% (2) | 37.5% (12) |
| Unifocal or multifocal | Unifocal | 40.4% (17/42) | | | |
| | Multifocal | 59.5% (25/42) | | | |
| Number of zones involved | 1 | 40.4% (17/42) | | | |
| | 2 | 35.7% (15/42) | | | |
| | 3 | 19% (8/42) | | | |
| | 4 | 4.7% (2/42) | | | |

25/42) than unifocal (40.4%17/42) [Figures 5 and 6]. Regarding density, ground glass opacity (GGO) was more common (34/42, 80.9%) than consolidation (11/42, 26.1%) [Figures 7 and 8]. The median number of zones involved was two, while the mean was 1.9. A higher number of patients had one (40.4%, 17/42) or two (35.7%, 15/42) zones involved as compared to three (19%, 8/42) or four (4.7%, 2/42%). Four was the maximum number of zones involved in our cohort.

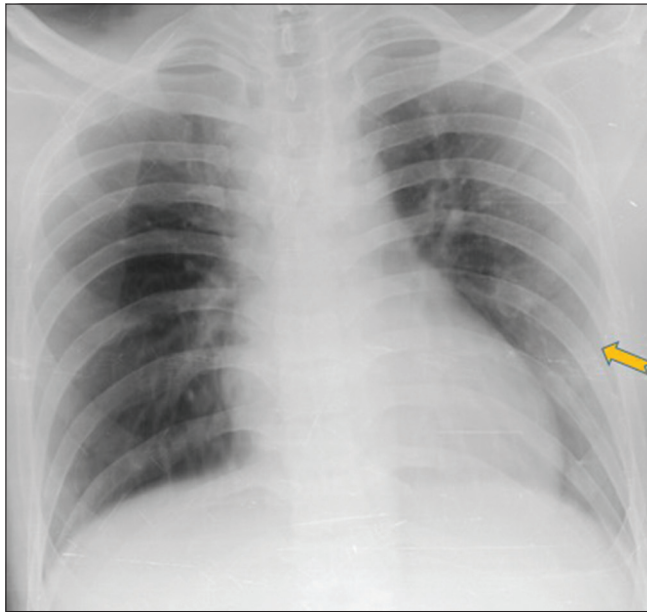


Figure 2: 27 year old resident doctor with mild recurrent fever and myalgia for 5 days. CXR revealed peripheral patchy ground glass opacities in left mid and lower zone. (yellow arrow)

Discussion

In present study, a good proportion of patients who tested positive for COVID-19 by RT PCR were asymptomatic (78/116, 67.2%). Among these patients, majority had cough (25/116 patients, 21.6%) and fever (20/116 patients, 17.2%). Asymptomatic state of the illness is well documented in previous studies also.^[11] Severe manifestations like ARDS were rare in our study. The large number of asymptomatic patients can be explained by the fact that our cohort included several patients detected on contact tracing of positive patients and asymptomatic travellers screened on entering our state. Diabetes mellitus and hypertension were the most common comorbidities present in our patients which is similar to previous studies.^[12]

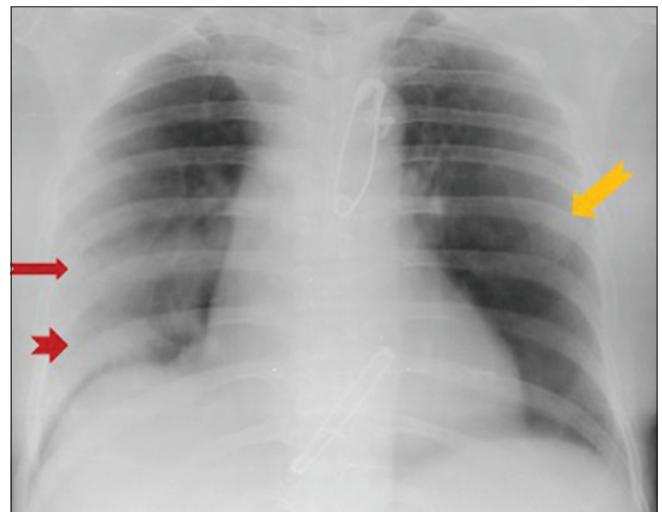


Figure 3: CXR revealed bilateral, multifocal, peripheral consolidations in bilateral mid zone and right lower zone (arrows)

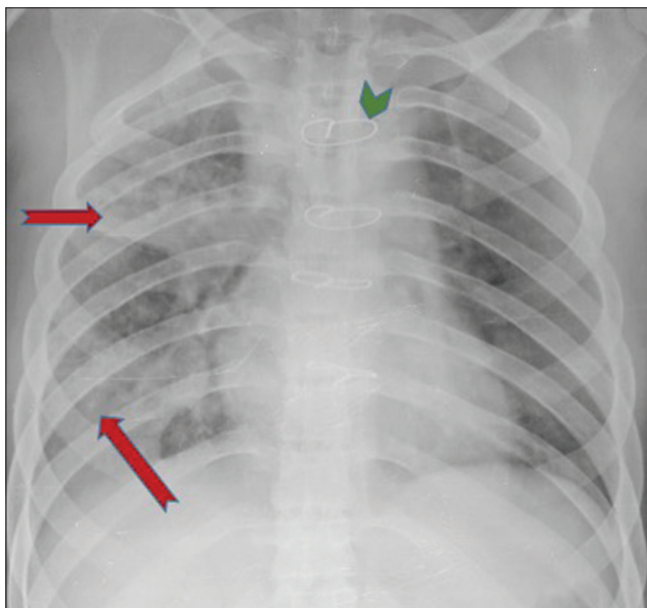


Figure 4: 13 year old girl, case of Down's syndrome with history of partial Atrio-ventricular septal defect repair. CXR revealed peripheral and central consolidation and nodules in all zones on right side (red arrows). Also note sternotomy sutures (Green arrowhead)

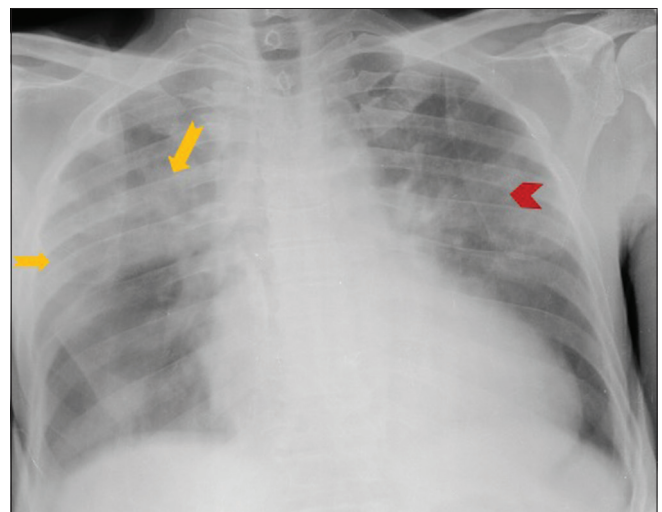


Figure 5: 72 year old diabetic, hypertensive patient with chronic kidney disease presented with fever, cough and dyspnoea. CXR revealed multifocal, patchy, right upper, lower zone and bilateral mid zone consolidation without mediolateral gradient (arrows). Note was also made of cardiomegaly

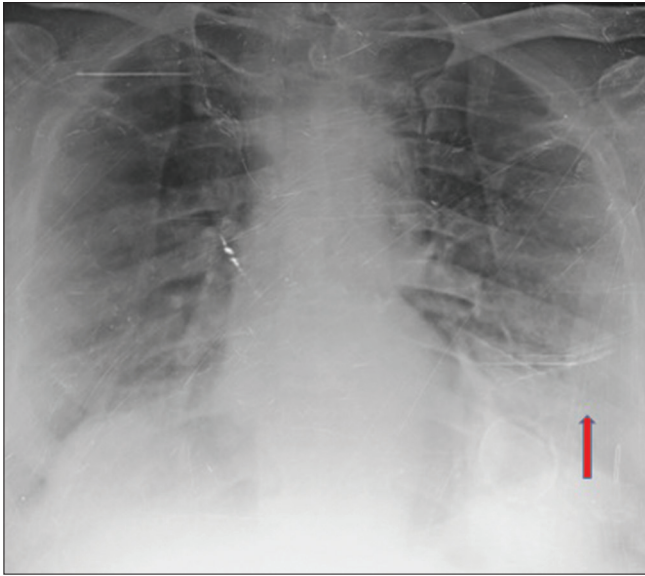


Figure 6: A 58 year old male presented with cough. CXR revealed patchy consolidation in left lower zone without mediolateral gradient (red arrow)

In the present study, the sensitivity of radiographs was 36.2% which is similar to the study by Yoon *et al.* (33.3%)^[9] and less as compared to the study by Wong *et al.*^[8] (69%) This could be due to large proportion of asymptomatic patients in the present study (68.1%) versus 14% in Wong *et al.*^[8] A higher number of patients in the symptomatic group (68.4%) than the asymptomatic group (20.5%) showed radiographic abnormalities consistent with pneumonia ($P < 0.0001$). In the present study, unilateral involvement was more common (57.1%) than bilateral involvement (42.8%). This is different from prior studies by Wong *et al.* and Lomoro *et al.* in which bilateral involvement were 63% and 78.1%, respectively.^[8,10] In the present study, lower zone involvement (83.3%) was more common followed by mid zone (57.1%) which is similar to other studies.^[8-10] Regarding density of lesion, ground glass opacities were most commonly found (80.9%) in contrast to all prior studies, in which consolidation was most commonly found.^[8-10] In current study, the opacities were predominantly peripheral (80.9%) similar to previous studies.^[9,10]

In addition to the above, in the present study, multifocal involvement (59.5%) was more common than unifocal (40.4%). Also, one-zone and two-zone involvement were more common than three- and four-zone involvement likely due to our cohort including large number of asymptomatic and less-severely ill patients. In our study population, only one patient succumbed to the illness, who died on day 6 after admission following rapid clinical worsening. He was a 71-year-old man, a diagnosed case of carcinoma pyriform sinus, with diabetes and hypertension who presented with fever. The CXR obtained from the patient on day 2 after admission showed bilateral lower zone peripheral ground glass opacities.

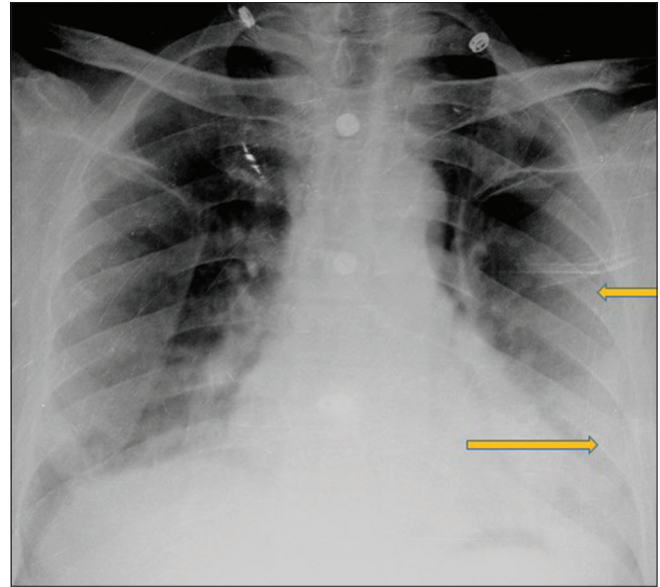


Figure 7: A 57 year old hypertensive patient presented with cough and fever. CXR depicting Left mid, lower zone peripheral and central, patchy, multifocal ground glass opacities (yellow arrows)

We had only four pediatric patients (<10 years of age) of which three were asymptomatic and had normal radiographs. One patient had fever and cough and showed unifocal peripheral opacity.

The limitations of our study are nonavailability of CT correlation and lack of a control group of COVID-19 negative patients due to which we were unable to calculate specificity. In the current pandemic, however, patients with suggestive symptoms and clinical profile who show typical radiographic findings can be diagnosed with confidence. We had very few severely ill/ICU patients in our group, and a separate study in such a group would be desirable. We found radiographs difficult to interpret in cases with suboptimal radiographic technique and positioning. In addition, in some patients with respiratory complaints, deep inspiration was difficult, which partially obscured the lower zones and made identification of opacity difficult. The advantages of radiographs include repeatability, ease of conducting in the isolation ward/ICU, and less requirement of infection control measures as opposed to CT.

To summarize, a significant proportion of COVID-19 patients are asymptomatic. A little over one-third of patients showed radiographic abnormalities compatible with pneumonia. This could be due to the large percentage of patients in our group being asymptomatic. Therefore, CXR cannot be used as a diagnostic tool. Instead, its use is to follow up and prognosticate patients especially in the ICU setting. If pneumonia-like abnormalities are found on radiographs in high clinical suspicion for COVID-19, CT can be avoided. Portable CXR was indispensable in our setting where CT

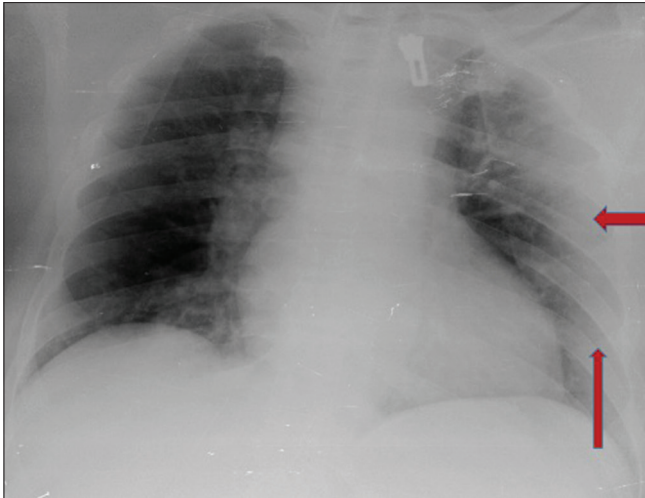


Figure 8: 45 years old asthmatic patient presented with dyspnoea. CXR showing peripheral, confluent, consolidations in left upper, mid and lower zones (red arrows)

was not part of the protocol, considering infection control measures and our hospital also catering to non-COVID patients. A larger percentage of symptomatic patients revealed radiographic abnormalities as compared to asymptomatic patients. The most common radiographic abnormalities among COVID 19 patients were bilateral or unilateral, patchy, multifocal, ground glass opacity, or consolidation in a peripheral and middle/lower zone distribution.

Conclusions

Portable chest radiography is a useful tool to evaluate the patients during this COVID-19 pandemic due to its widespread availability and reduced infection control issues that currently limit CT utilization. A significant number of COVID-19 patients were asymptomatic. Over one-third of the patients showed radiographic abnormalities. Symptomatic patients were more likely to show radiographic findings than asymptomatic patients. In cases of high clinical suspicion for COVID-19, a positive CXR may obviate the need for CT. Common radiographic abnormalities among COVID 19 patients were bilateral/unilateral, patchy, multifocal, ground glass opacity or consolidation in peripheral and middle/lower zone distribution.

Financial support and sponsorship

Nil.

Conflicts of interest

There are no conflicts of interest.

References

1. Wu Z, McGoogan JM. Characteristics of and important lessons from the coronavirus disease 2019 (COVID-19) outbreak in China: Summary of a report of 72 314 cases from the Chinese Center for Disease Control and Prevention. *Jama*. 2020 Apr 7;323(13):1239-42.
2. Peng PW, Ho PL, Hota SS. Outbreak of a new coronavirus: What anaesthetists should know. *BJA: British Journal of Anaesthesia*. 2020 May; 124(5):497.
3. Song F, Shi N, Shan F, Zhang Z, Shen J, Lu H, Ling Y, Jiang Y, Shi Y. Emerging 2019 novel coronavirus (2019-nCoV) pneumonia. *Radiology*. 2020 Apr; 295(1):210-7.
4. Sánchez-Oro R, Nuez JT, Martínez-Sanz G. Radiological findings for diagnosis of SARS-CoV-2 pneumonia (COVID-19). *Medicina Clinica (English Ed.)*. 2020 Apr 30.
5. Shi H, Han X, Jiang N, Cao Y, Alwalid O, Gu J, Fan Y, Zheng C. Radiological findings from 81 patients with COVID-19 pneumonia in Wuhan, China: A descriptive study. *The Lancet Infectious Diseases*. 2020 Feb 24.
6. Yang Q, Liu Q, Xu H, Lu H, Liu S, Li H. Imaging of coronavirus disease 2019: A Chinese expert consensus statement. *European Journal of Radiology*. 2020 Apr 18:109008.
7. Jacobi A, Chung M, Bernheim A, Eber C. Portable chest X-ray in coronavirus disease-19 (COVID-19): A pictorial review. *Clinical Imaging*. 2020 Apr 8.
8. Wong HY, Lam HY, Fong AH, Leung ST, Chin TW, Lo CS, Lui MM, Lee JC, Chiu KW, Chung T, Lee EY. Frequency and distribution of chest radiographic findings in COVID-19 positive patients. *Radiology*. 2020 Mar 27:201160.
9. Yoon SH, Lee KH, Kim JY, Lee YK, Ko H, Kim KH, Park CM, Kim YH. Chest radiographic and CT findings of the 2019 novel coronavirus disease (COVID-19): Analysis of nine patients treated in Korea. *Korean journal of radiology*. 2020 Apr 1;21(4):494-500.
10. Lomoro P, Verde F, Zerboni F, Simonetti I, Borghi C, Fachinetti C, Natalizi A, Martegani A. COVID-19 pneumonia manifestations at the admission on chest ultrasound, radiographs, and CT: Single-center study and comprehensive radiologic literature review. *European journal of radiology open*. 2020 Apr 4:100231.
11. Lai CC, Liu YH, Wang CY, Wang YH, Hsueh SC, Yen MY, Ko WC, Hsueh PR. Asymptomatic carrier state, acute respiratory disease, and pneumonia due to severe acute respiratory syndrome coronavirus 2 (SARSCoV-2): Facts and myths. *Journal of Microbiology, Immunology and Infection*. 2020 Mar 4.
12. Wang D, Hu B, Hu C, Zhu F, Liu X, Zhang J, Wang B, Xiang H, Cheng Z, Xiong Y, Zhao Y. Clinical characteristics of 138 hospitalized patients with 2019 novel coronavirus-infected pneumonia in Wuhan, China. *Jama*. 2020 Mar 17;323(11):1061-9.