

Cerebrotendinous xanthomatosis - A case report

Arshed Hussain Parry, Abdul Haseeb Wani, Muiez Bashir, Tariq A Gojwari

Department of Radiodiagnosis, Sher-i-Kashmir Institute of Medical Sciences, Srinagar, Jammu and Kashmir, India

Correspondence: Dr. Arshed Hussain Parry, Department of Radiodiagnosis, Sher-i-Kashmir Institute of Medical Sciences, Soura, Srinagar - 190 011, Jammu and Kashmir, India. E-mail: arshedparry@gmail.com

Abstract

Cerebrotendinous xanthomatosis (CTX) is a rare autosomal recessive disorder resulting from a defective enzyme in bile acid synthesis pathway leading to neurological, ocular, vascular, and musculoskeletal symptoms from deposition of cholestanol and cholesterol in these tissues. We present clinical and imaging features of a 32-year-old female who presented with mental retardation, gait instability and swelling along posterior aspect of both ankles. Imaging studies were performed which revealed spectrum of CTX findings in brain and tendons. Subsequently the diagnosis was confirmed by biopsy and laboratory tests.

Key words: Cerebrotendinous xanthomatosis; cholestanol; dentate nucleus

Introduction

Cerebrotendinous xanthomatosis (CTX) is a rare autosomal recessive disorder resulting from a defective enzyme in bile acid synthesis pathway with deposition of cholestanol and cholesterol in brain, tendons, soft tissues and eyes leading to cerebellar dysfunction, early cataract formation, tendon, and soft tissue xanthomas. Around 300 cases of CTX have been reported worldwide to date. The disease is potentially treatable with chenodeoxycholic acid. Early diagnosis and treatment is essential to prevent the neurological sequelae of the disease.

Case History

A 32-year-old, mentally retarded female presented with gait instability and right malar eminence swelling as well as swelling along the posterior aspect of both ankle joints. Patient had undergone surgery for cataracts in both eyes 10 years back. On examination patient was

found to have ataxia, soft, non-tender swelling along the posterior aspect of both ankle joints, as well as right malar eminence [Figure 1A]. A preliminary diagnosis of cerebrotendinous xanthomatosis was made and evaluation was started.

Lipid profile revealed total cholesterol of 306 mg/dl (LDL 205 mg/dl, VLDL 46mg/dl, HDL 55 mg/dl) and triglycerides of 526 mg/dl. Rest of the blood chemistry was normal. Radiograph of ankle joints revealed soft tissue swellings along the posterior aspect of both ankle joints and calcaneal bones [Figure 1B]. MRI of ankle joints revealed fusiform enlargement of bilateral Achilles tendons with signal intensity similar to muscle with speckled appearance on axial images consistent with tendinous xanthomatosis [Figure 2]. MRI brain revealed hyperintensity of bilateral dentate nuclei, deep cerebellar white matter with hyperintensity of posterior limbs

This is an open access journal, and articles are distributed under the terms of the Creative Commons Attribution-NonCommercial-ShareAlike 4.0 License, which allows others to remix, tweak, and build upon the work non-commercially, as long as appropriate credit is given and the new creations are licensed under the identical terms.

For reprints contact: reprints@medknow.com

Cite this article as: Parry AH, Wani AH, Bashir M, Gojwari TA. Cerebrotendinous xanthomatosis - A case report. Indian J Radiol Imaging 2019;29:332-4.

Received: 22-Nov-2018

Revision: 24-Nov-2018

Accepted: 10-Sep-2019

Published: 30-Oct-2019

Access this article online

Quick Response Code:



Website:
www.ijri.org

DOI:
10.4103/ijri.IJRI_444_18

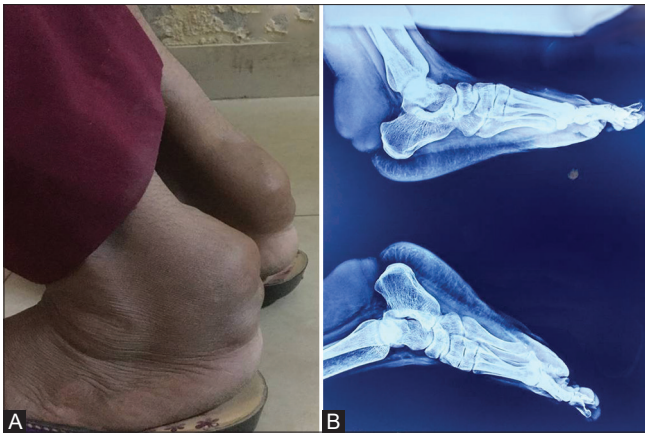


Figure 1 (A and B): Photograph of bilateral ankles revealing swelling along the posterior aspect of both ankles (A) with corresponding lateral radiograph of both ankles revealing soft tissue radio-opacities posterior to calcaneal bones and tibia in the region of Achilles tendons (B)

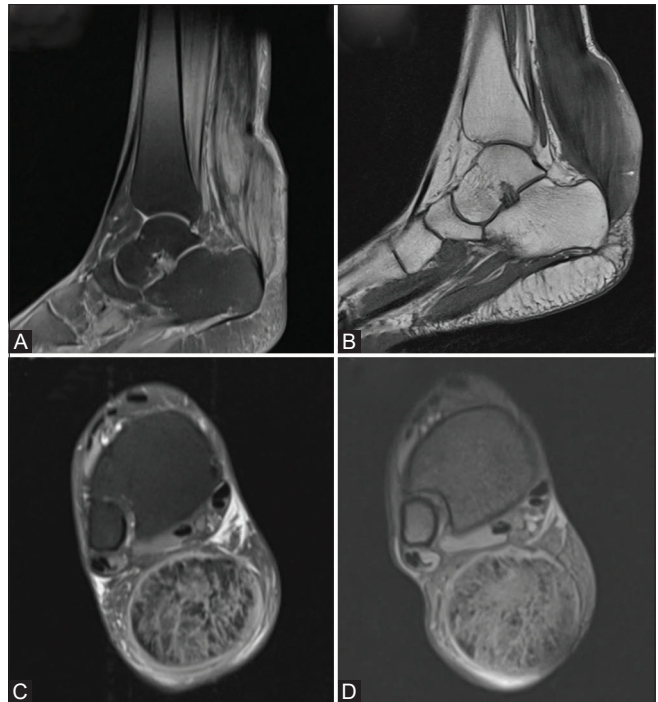


Figure 2 (A-D): Sagittal proton density image (A) and T1-weighted image (B) showing diffuse enlargement of Achilles tendon with axial proton density (C) and MEDIC (D) showing enlarged Achilles tendon with widely spaced tendon fibers interposed with fat (speckled appearance)

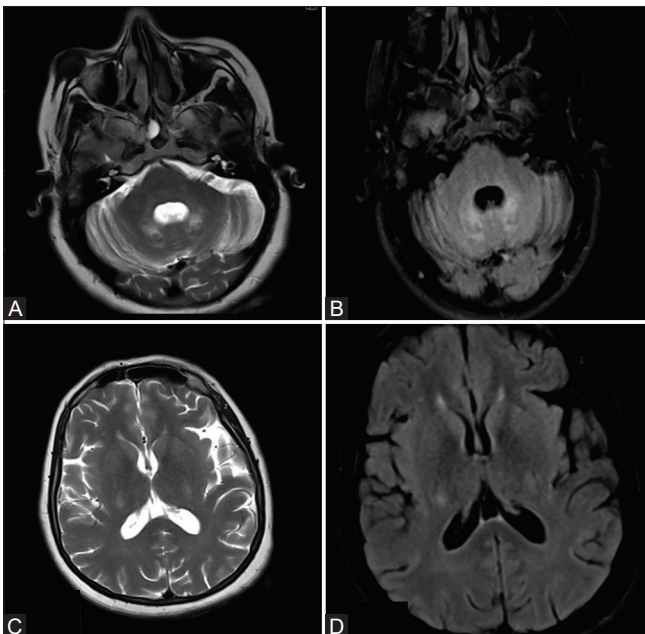


Figure 3 (A-D): Axial T2-weighted and FLAIR images (A and B) reveal hyperintensity of bilateral dentate nuclei and deep cerebellar white matter. Hyperintensity of posterior limb of bilateral internal capsules is also seen on T2-weighted and FLAIR images (C and D)

of internal capsules on T2W and FLAIR images with corresponding hypointensity on T1W images [Figure 3]. Susceptibility weighted images [Figure 4C] revealed comma shaped hypointense signal of bilateral dentate nuclei. Hypointense T1W and T2W round lesion was found in subcutaneous tissues of right malar eminence [Figure 4A and B] which was subjected to FNAC which revealed a xanthoma [Figure 4D]. Serum cholestanol levels were raised (14.1 micromole/liter).

With a combined spectrum of clinical, biochemical and radiological findings, a diagnosis of cerebrotendinous xanthomatosis (CTX) was made.

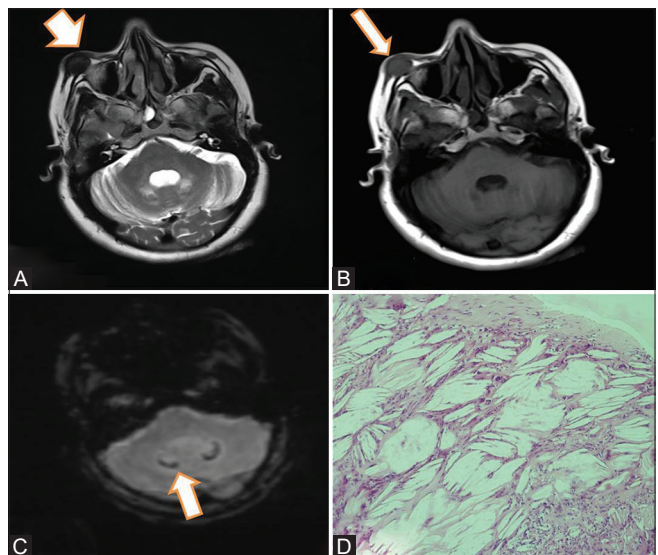


Figure 4 (A-D): Axial T2-weighted and T1-weighted images (A and B respectively) reveal a hypointense nodule (arrows) in the subcutaneous tissues of right malar eminence. Susceptibility weighted image (C) reveal comma shaped hypointensity (arrow) in the region of bilateral dentate nuclei. High power view photomicrograph (D) reveals multiple giant cells and cholesterol crystals consistent with diagnosis of xanthoma

Discussion

CTX is an autosomal recessive disorder characterized by defective sterol 27-hydroxylase enzyme which is

responsible for conversion of cholesterol into bile acids (cholic and chenodeoxycholic acid). Defect in this enzyme pathway results in accumulation of precursors of bile acids namely cholestanol and bile alcohols.^[1-3] Abnormally elevated cholesterol and cholestanol compounds get deposited in soft tissues leading to early cataract formation, soft tissue and tendon xanthomas, early atherosclerosis. Subnormal intelligence, learning difficulties, cerebellar dysfunction and neuropathy comprise the neurological spectrum of the disease. Serum cholesterol and cholestanol levels are elevated in CTX.^[1,3,4] Diagnosis is clinched by the characteristic combination of neurological, ocular and musculoskeletal symptoms supplemented by neuroimaging and biochemical results. In CTX, MRI of brain reveals hyperintensity of dentate nuclei and deep cerebellar white matter on T2-weighted and FLAIR sequences with associated cerebellar atrophy. Microcalcifications can occur within dentate nuclei which can be demonstrated as hypointensity of dentate nuclei on susceptibility weighted imaging. Cerebral atrophy with T2W and FLAIR hyperintensity of supratentorial white matter and deep grey nuclei can also be seen. Involvement of internal capsule as T2W/FLAIR hyperintensity.^[1-3,5,6] All these areas of signal intensity change exhibit increased diffusivity on DWI. Tendon xanthomas can be demonstrated by MRI as enlargement of tendons with hypointense signal intensity. Soft tissue xanthomas also exhibit hypointense signal intensity on both T1W and T2W images.

CTX has a myriad of differential diagnosis. It mimics hypercholesterolemia and sitosterolemia which share xanthoma as a clinical feature with it. Sitosterolemia is differentiated from CTX by absence of neurological symptoms and cataract formation. Hypercholesterolemia is characterized by formation of xanthomas with elevated cholesterol levels but with normal cholestanol levels. CTX also resembles Marinesco-Sjogren syndrome which also presents with triad of cataract formation, ataxia and mental retardation but the absence of tendon xanthomas and presence of scoliosis, short small bones of hand and feet reliably differentiate this disorder from CTX. On neuroimaging those disorders which exhibit hyperintensity of dentate nuclei on T2W images need to be differentiated from CTX. These include metronidazole toxicity and acutely decompensated maple syrup urine disease. These two disorders present with acute encephalopathy unlike CTX which has an insidious presentation.^[1,5,7]

Treatment consists of chenodeoxycholic acid which suppresses the formation of cholestanol. Treatment must be

started at the earliest to halt the neurological deterioration.^[1,4,7,8] Though this is a typical case of CTX but the fact that patient had not been diagnosed previously has led to permanent neurological damage in the form of subnormal intelligence and cerebellar ataxia. The fact that patient was operated for juvenile cataracts a decade back should have alerted the physician to ascertain the etiology of early cataract formation and early institution of appropriate therapy to avert the neurological sequelae of this otherwise treatable condition.

Declaration of patient consent

The authors certify that they have obtained all appropriate patient consent forms. In the form the patient(s) has/have given his/her/their consent for his/her/their images and other clinical information to be reported in the journal. The patients understand that their names and initials will not be published and due efforts will be made to conceal their identity, but anonymity cannot be guaranteed.

Financial support and sponsorship

Nil.

Conflicts of interest

There are no conflicts of interest.

References

- Gerrish AC, Gaba S. Case 239: Cerebrotendinous xanthomatosis. *Radiology* 2017;282:916-21.
- Barkhof F, Verrips A, Wesseling P, van der Knaap MS, van Engelen BG, Gabreëls FJ, *et al.* Cerebrotendinous xanthomatosis: The spectrum of imaging findings and the correlation with neuropathologic findings. *Radiology* 2000;217:869-76.
- Pudhiavan A, Agrawal A, Chaudhari S, Shukla A. Cerebrotendinous xanthomatosis-The spectrum of imaging findings. *J Radiol Case Rep* 2013;7:1.
- Gaikwad SB, Garg A, Mishra NK, Gupta V, Srivastava A, Sarkar C. Cerebrotendinous xanthomatosis: Neuroimaging findings in two siblings from an Indian family. *Neurol India* 2003;51:401.
- Chakraverty S, Griffiths PD, Walls TJ, McAllister VL. Cerebrotendinous xanthomatosis in two sisters: Case reports and MR imaging. *Clin Radiol* 1995;50:117-9.
- Inglese M, DeStefano N, Pagani E, Dotti MT, Comi G, Federico A, *et al.* Quantification of brain damage in cerebrotendinous xanthomatosis with magnetization transfer MR imaging. *AJNR Am J Neuroradiol* 2003;24:495-500.
- Nie S, Chen G, Cao X, Zhang Y. Cerebrotendinous xanthomatosis: A comprehensive review of pathogenesis, clinical manifestations, diagnosis, and management. *Orphanet J Rare Dis* 2014;9:179.
- Makary MS, Kisanuki YY, Amin NN, Slone HW. Teaching neuroimages: Cerebrotendinous xanthomatosis: A rare treatable adult-onset lipid storage disease. *Neurology* 2018;90:e637-8.