Article published online: 2021-07-26

Gangrenous cholecystitis: Analysis of imaging findings in histopathologically confirmed cases

Binit Sureka, Archana Rastogi[1], Amar Mukund, Shalini Thapar, Ajeet Singh Bhadoria[2], Tushar Kanti Chattopadhyay[3]

Departments of Radiology, [1]Pathology, [2]Community Medicine, [3]HPB Surgery, Institute of Liver and Biliary Sciences, New Delhi, India

Correspondence: Dr. Binit Sureka, Department of Radiology, Institute of Liver and Biliary Sciences, D-1, Vasant Kunj, New Delhi, India. E-mail: binitsurekapgi@gmail.com

Abstract

Purpose: To study the imaging findings in gangrenous acute cholecystitis. **Materials and Methods:** Retrospective analysis of imaging findings in 31 histopathologically confirmed cases of gangrenous cholecystitis was done. The following imaging findings were analyzed: wall thickness, gallbladder distension, intraluminal membranes, mural striation, edema, wall enhancement, gallstones, gas, pericholecystic fluid, stranding, hemorrhage, hyperaemia in adjacent liver, mucosal/wall irregularity, complications. **Statistical Analysis:** Appropriate statistical tests were used using SPSS.22.0 software. The two proportions were compared using Chi-square or Fisher exact test and two means were compared using student *t* test. **Results:** Mean gallbladder wall thickening was 6 ± 1.93 mm. Gallstones, mural edema, mural striation, pericholecystic fluid, intraluminal membranes, gas were seen in 30, 27, 18, 20, 14 and 3 cases respectively. The mean short-axis distension of gallbladder lumen was 4.24 ± 0.91 cm. Gallbladder wall enhancement was studied in only 10 cases. Complete absence of enhancement was seen in 1, focal decreased enhancement in 8 cases. Mucosal/wall irregularity was seen in 28 cases. 74.2% cases had ≥4 cm gallbladder distension. Intraluminal membranes were present in 14 cases with mean short-axis distension of 4.6 cm and absent in 17 (P = 0.041), in 11 cases with mural striation (P = 0.036). Mean wall thickening was 6.69mm in patients with intraluminal membranes and 5.46 mm with absence of membranes (P = .078). **Conclusion:** Presence of more than one of these findings - gallbladder distension (short axis diameter of ≥4 cm), intraluminal membranes, mural striation, absent or decreased enhancement of gallbladder wall suggest high probability of gangrenous change in acute cholecystitis.

Key words: Cholecystitis; gangrenous; gallbladder distension; membranes

Introduction

Gangrenous cholecystitis (GC) is a complicated advanced subtype of acute cholecystitis associated with high morbidity. This most severe variant of cholecystitis is considered the terminal stage of gallbladder (GB) inflammation, beyond which perforation and sepsis is inevitable.[1] Pathologically, gangrenous change in acute cholecystitis is characterized by transmural acute inflammation and intramural abscess formation resulting in full-thickness necrosis or ulceration of the GB wall secondary to obliteration of the cystic artery

Access this article online	
Quick Response Code:	Website: www.ijri.org
	DOI: 10.4103/ijri.IJRI_421_16

This is an open access journal, and articles are distributed under the terms of the Creative Commons Attribution-NonCommercial-ShareAlike 4.0 License, which allows others to remix, tweak, and build upon the work non-commercially, as long as appropriate credit is given and the new creations are licensed under the identical terms.

For reprints contact: reprints@medknow.com

Cite this article as: Sureka B, Rastogi A, Mukund A, Thapar S, Bhadoria AS, Chattopadhyay TK. Gangrenous cholecystitis: Analysis of imaging findings in histopathologically confirmed cases. Indian J Radiol Imaging 2018;28:49-54.

and/or sustained obstruction of the cystic duct.[2,3] Its incidence varies from 10 to 40% of all patients presenting with acute cholecystitis.

Clinically, it is very difficult to differentiate patients between gangrenous and nongangrenous acute cholecystitis (NGAC). But the management of these two entities is different. GC is managed by emergency cholecystectomy, while NGAC can be managed conservatively.[4,5]

The radiological findings suggestive of gangrenous change in acute cholecystitis are varied: gas in the wall or lumen, intraluminal membranes, irregular wall, pericholecystic abscess, lack of mural enhancement, pericholecystic fluid, gallbladder distention, and wall thickening.[5-7] There is significant overlap of these imaging findings with other forms of complicated acute cholecystitis. The purpose of our study is to retrospectively analyze the imaging findings of histopathologically confirmed cases of GC.

Materials and Methods

Patient Population

A total of 31 patients were evaluated. The study population comprised 13 males and 18 females. Mean age of the study group was 49.2 years (range 24–74 years). A retrospective study was done wherein data of patients operated at our institute with histopathological evidence of GC were collected and analyzed. In lieu of the retrospective nature of the study, Institutional Review Board approval was not required as per our institution's policy. For this, the histopathology records of operated cases of acute cholecystitis between January 2012 and August 2016 was searched and cases in which pathology reports mentioned necrosis, transmural inflammation with transmural ulceration were considered as gangrenous changes in the GB and only those patients were included in the present study. We excluded patients who had acute cholecystitis without gangrenous changes in GB.

Imaging protocol

Ultrasound protocol

Ultrasound was performed in either of the two machines available in our Department (Philips iU22, USA or Toshiba XARIO-SSA-660A, Tokyo, Japan) depending on the availability. The transducers used in this study were for abdominal use and the frequency ranged from 1.0 to 7.0 MHz. The patients were scanned in supine and decubitus positions depending on the patient comfort.

Contrast-enhanced computed tomography protocol

Computed tomography (CT) abdomen was performed using GE Discovery 750HD single-source dual-energy CT scanner (Discovery CT 750HD; GE Healthcare, Milwaukee, WI). 100 ml of nonionic iodinated contrast material (iodine concentration, 400 mg/ml) was injected through an 18–20-gauge antecubital intravenous cannula at a rate of 4 ml/s. Scans were acquired in hepatic arterial, portal venous, and hepatic venous phase using a Smart Prep Protocol with enhancement threshold set at 100 HU. Examination parameters were detector coverage 40 mm, 98.43 mm/s table speed, 0.6 s rotation time, pitch and speed of 0.984, 1.5 mm section thickness, 5-mm reconstruction interval, 100–120 kVp, and 200–360 mA. Additional images were reconstructed with 0.625 mm reconstruction intervals for detailed interpretation.

Magnetic resonance imaging protocol

All magnetic resonance (MR) cholangiograms in our department were obtained with a Signa HDxt 3.0-T scanner volume MR (GE, Fairfield, CT, USA). A body phased-array coil with eight elements, centered below the xiphoid process, was used for signal reception. We routinely acquire coronal and axial T2-weighted (T2W) single-shot fast spin-echo (FSE) sequences, axial respiratory-triggered fat-suppressed T2W FSE sequence, and axial breath-hold T1-weighted (T1W) dual-echo spoiled gradient recalled-echo sequence. Magnetic resonance cholangiopancreatography (MRCP) is performed using a respiratory-triggered high-spatial resolution isotropic three-dimensional (3D) fast-recovery FSE sequence with parallel imaging in axial and oblique coronal planes, which provides high signal-to-noise ratio and excellent spatial resolution (1-mm isotropic voxels) in a relatively short acquisition time (repetition time: one respiratory cycle, echo time: 700 ms, echo space: 8.5 ms, matrix: 320 × 256, section thickness: 1.4 mm, zero-fill interpolation to 0.7, 40–70 sections, receiver bandwidth: 25 kHz, acquisition time: 3–7 min, array spatial sensitivity encoding factor two, actual voxel dimensions (mm) isotropic at 1.4 _ 1.4 _ 1.4 interpolated to 0.7 _ 0.7 _ 0.7). In addition, 2D half-Fourier single-shot FSE sequence is implemented in thick-slab and multisection modes (image acquisition parameters: relaxation time –2.800 ms, effective TE – 750 ms, image matrix –384 × 256, field of view –200 × 200 mm, refocusing flip angle – 180°). The resulting images are displayed as projection images of the biliary tree after a 7.13 s acquisition time. Maximum intensity projection algorithm is used to produce a 3D cholangiogram from 3D FSE images.

Image interpretation

The images obtained were analyzed by experienced radiologists having sufficient expertise in abdominal imaging interpretations. The following features were recorded: (1) Wall thickness; (2) GB distension/diameter in short and long-axis; (3) intraluminal membranes (linear irregular density/signal/echogenic structures in the GB lumen); (4) mural striation (areas of high and low attenuation/signal/echogenicity in GB wall); (5) mural edema; (6) GB wall enhancement (only in cases where contrast study was done, assessed by visual evaluation compared with the liver parenchyma, and classified as normal, absent, or focally decreased); (7) gallstones; (8) stone in the common bile duct; (9) gas;

(10) pericholecystic fluid; (11) pericholecystic stranding; (12) wall hemorrhage (hyperdense wall on noncontrast CT scan/hyperintense signal on T1 gradient echo sequence); (13) hyperemia in adjacent liver [focally increased arterial enhancement on CT scan/diffusion restriction on magnetic resonance imaging (MRI)]; (14) mucosal/wall irregularity; (15) complications if any. Clinical parameters of age, sex, total leucocyte counts, diabetes mellitus, and time interval between surgeries were also recorded.

Statistical analysis

The data were presented as proportion, mean with standard deviation, or median with inter-quartile range, as and when required. The two proportions were compared using Chi-square test or Fisher's exact test, and the two means were compared using Student's *t*-test. The continuous data were graphically presented as a box plot. *P* value <0.05 was considered significant. Statistical Package for the Social Sciences version 22.0 software was used for data analysis.

Results

A total of 31 patients (male 13; female 18; mean age 49.2 years, age range 24–74 years) were included in the study. Ultrasound, contrast-enhanced computed tomography (CECT) and MRI examinations were done in 16, 10, and 18 patients, respectively. The median age group of the patients included in the study was 48 (24–74 years). Out of 31 patients, 17 patients had diabetes mellitus. The mean white blood cells (WBC) count of the patients was $11.9 \pm 3.19 \times 10^3$/cu.mm (normal range 4–11 × 10^3/cu.mm). The median time of surgery was 2 days. Histopathological reports suggested features of acute cholecystitis in 19, and 12 cases had acute on chronic cholecystitis. All cases had necrosis of the GB wall.

The results of the study are shown in Table 1. The mean wall thickening of the GB wall was 6 ± 1.93 mm (range 3–11 mm). Gallstones were present in 30 cases. One case had acalculous acute cholecystitis. None of the patients had stones in the common bile duct. Mural edema, mural striation, pericholecystic fluid, and intraluminal membranes were seen in 27, 18, 20, and 14 cases, respectively. Pericholecystic stranding was seen in 24 cases and presence of intraluminal gas was seen in 3 cases.

The mean long and short-axis distension of GB lumen was 9.73 ± 1.96 and 4.24 ± 0.91 cm. Hyperemia on CECT and diffusion restriction on MRI of the adjacent liver parenchyma was seen in 17 cases. GB wall enhancement was studied in only 10 cases. Complete absence of GB wall enhancement was seen in 1, focal decreased enhancement in 8, and normal wall enhancement was present in 1 case. On imaging, mucosal/wall irregularity was seen in 28 (90.3%) cases, although on histopathological evaluation necrosis of GB wall was seen in all the 31 cases. GB wall hemorrhage was seen in 7 cases, though histopathological reports revealed hemorrhage only in 4 cases. Complications in the form of rupture and pericholecystic or liver abscess formation were seen in 4 cases [Figures 1–6].

In our study, 23 (74.2%) cases had ≥4 cm short-axis GB distension. Intraluminal membranes were present in 14 cases with mean short-axis distension of 4.6 cm and absent in 17 cases with mean short-axis distension of 3.94 cm and this was found to be statistically significant (*P* = 0.041) [Figure 7]. Intraluminal membranes were present in 14 cases with mean wall thickening of 6.69 mm and absent in 17 cases with mean wall thickening of 5.46 mm; however, this was not statistically significant (*P* = 0.078) [Figure 8]. No statistical significance was seen between intraluminal membranes and WBC counts. Out of 14 cases with intraluminal membranes, 11 (78.6%) cases had mural striation which was statistically significant (*P* = 0.036) [Table 2]. All cases with GB wall hemorrhage had intraluminal membranes within the lumen.

Discussion

This study is the largest series in Indian population discussing the imaging findings of pathologically proven cases of GC (*n* = 31). The present study has shown that combination of imaging findings of GB distension (short-axis diameter of ≥4 cm), intraluminal membranes,

Table 1: Imaging findings in our study population

Imaging features	Patients (*n*=31)
GB wall thickening (>3 mm)	30 (96.7%)
Gallstones	30 (96.7%)
Mucosal/wall irregularity	28 (90.3%)
Mural edema	27 (87%)
Pericholecystic stranding	24 (77.4%)
Mean distension of gallbladder (short-axis diameter ≥4 cm)	23 (74.2%)
Pericholecystic fluid	20 (64.5%)
Mural striation	18 (58%)
Hyperemia/diffusion restriction of liver parenchyma	17 (54.8%)
Intraluminal membranes	14 (45.1%)
GB wall hemorrhage	7 (22.5%)
Complications (GB perforation; abscess; subcapsular collection)	4 (12.9%)
Gas	3 (9.6%)
Stones in the common bile duct	0
Gallbladder wall enhancement (*n*=10)	
Focal decreased	8
Absent	1

Table 2: Comparison of intraluminal membranes with GB distension, mural striation, and wall thickening

Imaging findings	Intraluminal membranes		*P*
	Present (*n*=14)	Absent (*n*=17)	
GB distension (short-axis diameter)	4.6±0.67	3.94±0.98	0.041
Mural striation	11 (78.5%)	10 (58.8%)	0.036
Wall thickening	6.69±1.93	5.46±1.79	0.07

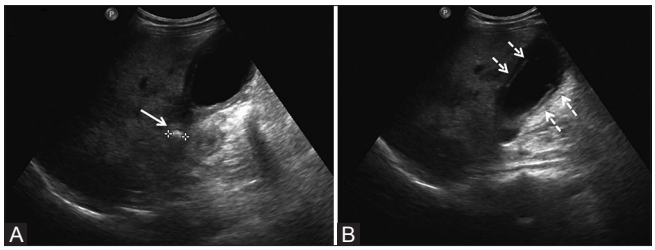

Figure 1 (A and B): Gangrenous cholecystitis in a 44-year-old female. Ultrasound images showing (A) gallstone (*arrow*) impacted at the neck resulting into distended gallbladder with wall thickening; (B) sloughed membranes (*dashed arrows*) within the lumen in a case of gangrenous cholecystitis

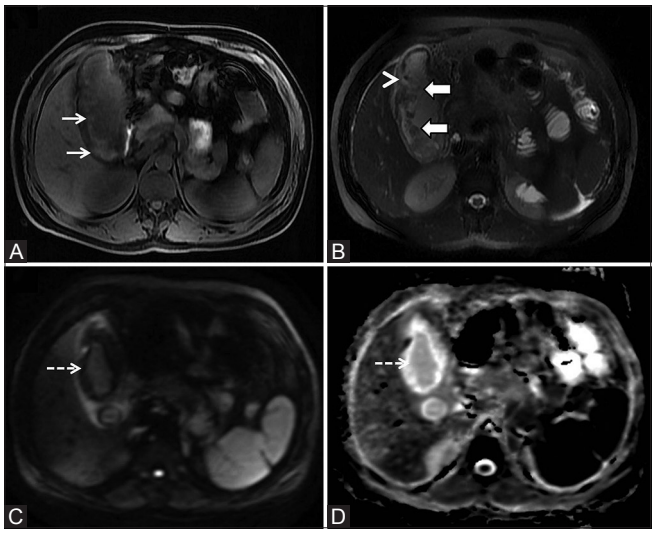

Figure 3 (A-D): Gangrenous cholecystitis in a 34-year old diabetic male. (A) Axial T1-gradient echo MRI showing over-distended GB with hyperintense GB wall (*thin arrows*) suggestive of hemorrhage; (B) T2-fat saturated MR showing full-thickness defect in the wall (*arrowhead*), intraluminal membranes (*thick arrows*), and pericholecystic fluid. (C) Diffusion-weighted trace image and (D) ADC map showing diffusion restriction within the contents of GB suggestive of suppurative bile

gallstones, wall irregularity, and mural striation in patients with acute cholecystitis suggests high probability of gangrenous change in GB.

In the majority of patients worldwide, gallstones are the cause of acute cholecystitis.[8] More than 80% of people with gallstones are asymptomatic. Acute cholecystitis develops only in 1–3% of patients with symptomatic gallstones.[9] Acute cholecystitis is an emergency condition and the patient should be referred to the hospital immediately. Around 20% of the patients with acute cholecystitis would require emergency surgery due to risk of developing GC or perforation.[8] Pathologically, acute cholecystitis has four stages – edematous (2–4 days), necrotizing (3–5 days), suppurative (7–10 days), and the fourth stage of chronic cholecystitis.[10] The second and the third stage comprises gangrenous changes in acute cholecystitis. The rapidity of progression to the second and third stages depends on the degree of obstruction and intraluminal pressure within

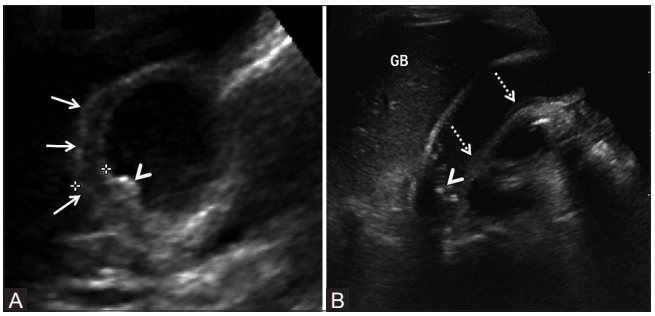

Figure 2 (A and B): Gangrenous cholecystitis in a 25-year-old-female. (A and B) Ultrasound images showing distended GB with mural striation (*arrows*), cholelithiasis (*arrowheads*), and linear echogenic intraluminal membranes (*dashed arrows*) within the lumen of gallbladder

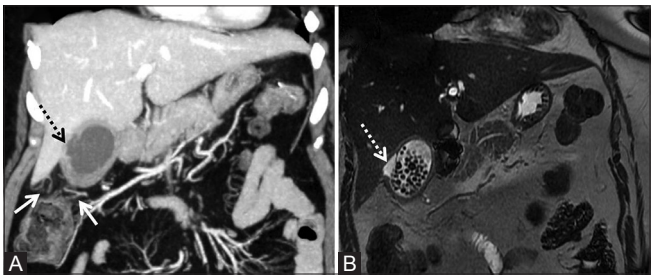

Figure 4 (A and B): Gangrenous cholecystitis in a 63-year-old-female. (A) Coronal CECT image showing distended gallbladder with focal necrosis of wall (*dashed arrow*) and attendant pericholecystic stranding (*arrows*). (B) Coronal T2-weighted MR image confirming necrosis (*dashed arrow*) of the GB wall with multiple T2-hypointense calculi

the GB. Different scoring systems have been devised to predict GC using various clinical parameters, but still it is very difficult for the surgeons to accurately diagnose this entity preoperatively.[11-13] Thus, the responsibility of the radiologists increased two-fold, not only to diagnose acute cholecystitis but also to alert the surgeon if there are associated complications and the difficulties that can be encountered during surgery.

The recent World Society of Emergency Surgery (WSES) guidelines recommend abdominal ultrasound as the first-line modality for the diagnosis of acute calculus cholecystitis.[14] Compared to CECT, MRI is a superior modality in diagnosing acute calculus cholecystitis.[15] Our institutional protocol is ultrasound and/or MRCP in clinically suspected cases of acute cholecystitis. CECT is recommended only in cases where the diagnosis other than acute cholecystitis is considered or when a complication as a consequence of acute cholecystitis is suspected.

Previous studies on GC have shown that the presence of intraluminal membranes is highly specific for GC, which pathologically suggests sloughed, ulcerated GB mucosa.[6] Bennett *et al*.[6] in their series of 23 cases showed that the CT findings that are most specific for acute GC are presence of gas, intraluminal membranes, irregular wall, and pericholecystic abscess. Chang *et al*.[5] have recently reported

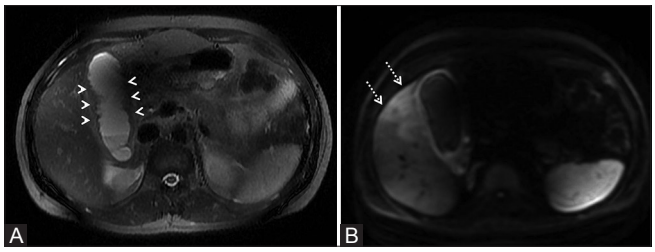

Figure 5 (A and B): Gangrenous cholecystitis in a 34-year-old-male. (A) Axial T2-weighted MR showing distended gallbladder with wall/mucosal irregularity (*arrowheads*). (B) Diffusion-weighted trace MR image showing subtle diffusion restriction (*dashed arrows*) suggestive of hyperemia in the adjacent liver parenchyma

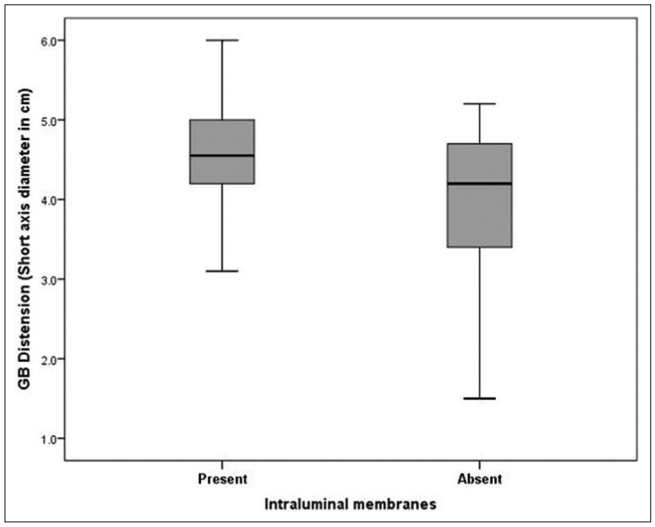

Figure 7: Box plot comparing gallbladder distension and intraluminal membranes

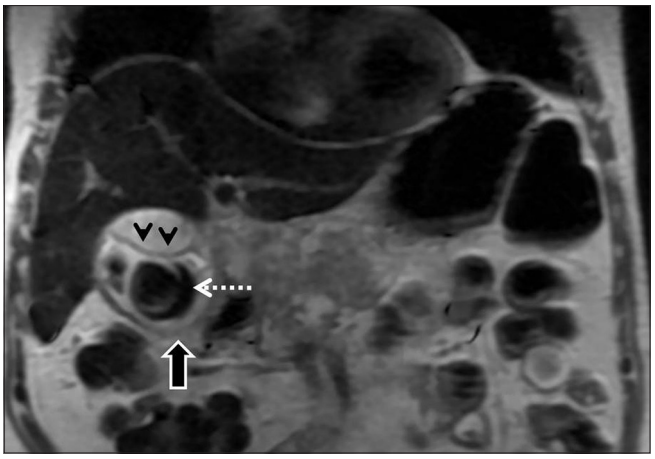

Figure 6: Gangrenous cholecystitis in a 62-year-old-male. Coronal T2-weighted MR showing distended GB with multiple T2-hypointense calculi (*arrow*) with linear hypointense intraluminal membranes (*arrowheads*) and necrosis (*thick arrow*) of the wall

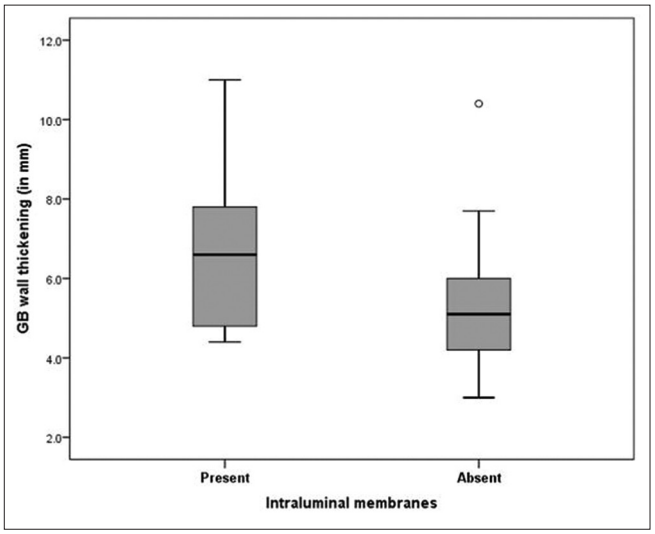

Figure 8: Box plot comparing gallbladder wall thickening and intraluminal membranes

that markedly distended GB associated with decreased wall enhancement is highly specific for GC. The presence of intraluminal membranes was seen only in 9/28 cases in their study. GB distension of >4 cm, mural striation and gallstones of 92.9% and 50% in each of their cases were seen, while in our study it was seen in 74.2, 58, and 96.7% of the cases, respectively. In the present study, the most commonly observed findings were distended GB, wall irregularity, wall thickening, gallstones, pericholecystic stranding, and mural edema, similar to the findings reported by Bennett *et al*.[6] and Chang *et al*.[5] The presence of mural striation was significantly higher in patients with intraluminal membranes in our study group. The presence of mural striation in GB wall has not been conclusive of GC in previous studies, although 50% and 96% cases of GC had mural striation in series by Chang *et al*.[5] and Revel *et al*.,[7] respectively. Bennett *et al*.[6] and Wu *et al*.[16] did not study the presence of GB wall mural striation with much detail. This finding could be of significant value for the radiologists, especially when assessing the patient of acute cholecystitis on ultrasound. Pathologically, mural striation refers to presence of submucosal edema and is an indirect clue to raised intraluminal pressure. Presence of mural striation with intraluminal membranes on initial ultrasound examination thus can be a pointer toward impending ischemia.

In the present study, GB wall hemorrhage was seen only in 7 and gas in 3 cases on imaging. Among 7 cases with GB wall hemorrhage, 3 cases did not correlate with histopathological findings. This could be due to misinterpretation of GB wall hyperdensity as hemorrhage. We did not find GB wall hemorrhage to be a reliable finding in GC, similar to the study by Chang *et al*.[5] However, previous studies by Cheng *et al*.[17] and Soyer *et al*.[18] have shown that significant number of their patient cohort had GB wall hemorrhage. Mucosal or wall irregularity was seen in 28 (90%) cases in our study, highlighting the presence of this important finding in cases of GC, similar to previous studies by Bennett *et al*.[6] and Revel *et al*.[7] However, this finding was not reported by Chang *et al*.[5] and was seen in only 4/17 cases in the study by Wu *et al*.[16]

CECT was done in only 10 cases in our series of 31 patients. GB wall enhancement was studied in these 10 cases. Decreased enhancement was seen in 9/10 (90%) cases, which is similar to previous studies.[5,6,16,19] Complete absence of GB wall enhancement was seen in 1 and focal decreased enhancement was seen in 9 cases. We also compared decreased enhancement of the GB wall with GB distention, and 7/8 cases showed decreased wall enhancement with GB distension >4 cm. We could not draw any conclusion from this finding in our study due to very small number of patients; however, Chang *et al*.[5] have shown that distended GB with decreased wall enhancement is highly specific for GC. We also support this hypothesis.

Increased adjacent liver parenchyma enhancement on CECT and diffusion restriction on MRI was suggestive of hyperemia in the adjacent liver parenchyma and was seen in 17 (54.8%) of the cases, which was higher as compared to previous studies.[5,6,16,19] This finding appears to be nonspecific and can be seen in other forms of non-GC as well.

The present study has some limitations. This was a retrospective study and the data on imaging findings were analyzed on heterogeneous radiological modalities. However, we think that radiologists should be aware of the imaging findings on different imaging modalities because it creates a practical real-world scenario, especially in resource-constraint settings. Contrast-enhanced scans were studied in limited number of patients. More studies with contrast examination in future can shed light on the problem. Prospective studies enrolling more patients with subset of patients having acute, acute on chronic, GC and analyzing radiological data in diverse patient population are needed. Interdisciplinary studies comparing clinical scoring system and radiological findings are scope of further research.

Conclusion

We would like to state that no single imaging finding is specific for GC. However, presence of more than one of these findings, GB distension (short-axis diameter of ≥4 cm), intraluminal membranes, mural striation, absent, or decreased enhancement of GB wall suggests high probability of gangrenous change in acute cholecystitis. These ominous radiological findings should be effectively communicated to the treating surgeon.

Acknowledgement

Dr Nikhil Agrawal and Dr Asit Arora, Associate Professors, Department of HPB Surgery, ILBS; Dr Shiv Kumar Sarin, Senior Professor and Director, ILBS.

Financial support and sponsorship

Nil.

Conflicts of interest

There are no conflicts of interest.

References

1. Girgin S, Gedik E, Taçyildiz IH, Akgün Y, Baç B, Uysal E. Factors affecting morbidity and mortality in gangrenous cholecystitis. Acta Chir Belg 2006;106:545-9.
2. Mentzer RM Jr, Golden GT, Chandler JG, Horsley JS 3rd. A comparative appraisal of emphysematous cholecystitis. Am J Surg 1975;129:10-5.
3. Fry DE, Cox RA, Harbrecht PJ. Gangrene of the gallbladder: A complication of acute cholecystitis. South Med J 1981;74:666-8.
4. Nikfarjam M, Niumsawatt V, Sethu A, Fink MA, Muralidharan V, Starkey G, *et al*. Outcomes of contemporary management of gangrenous and non-gangrenous acute cholecystitis. HPB (Oxford) 2011;13:551-8.
5. Chang WC, Sun Y, Wu EH, Kim SY, Wang ZJ, Huang GS, *et al*. CT findings for detecting the presence of gangrenous ischemia in cholecystitis. AJR Am J Roentgenol 2016;207:302-9.
6. Bennett GL, Rusinek H, Lisi V, Israel GM, Krinsky GA, Slywotzky CM, *et al*. CT findings in acute gangrenous cholecystitis. AJR Am J Roentgenol 2002;178:275-81.
7. Revel L, Lubrano J, Badet N, Manzoni P, Degano SV, Delabrousse E. Preoperative diagnosis of gangrenous acute cholecystitis: Usefulness of CEUS. Abdom Imaging 2014;39:1175-81.
8. Indar AA, Beckingham IJ. Acute cholecystitis. BMJ 2002;325:639-43.
9. Friedman GD. Natural history of asymptomatic and symptomatic gallstones. Am J Surg 1993;165:399-404.
10. Kimura Y, Takada T, Kawarada Y, Nimura Y, Hirata K, Sekimoto M, *et al*. Definitions, pathophysiology, and epidemiology of acute cholangitis and cholecystitis: Tokyo Guidelines. J Hepatobiliary Pancreat Surg 2007;14:15-26.
11. Yacoub WN, Petrosyan M, Sehgal I, Ma Y, Chandrasoma P, Mason RJ. Prediction of patients with acute cholecystitis requiring emergent cholecystectomy: A simple score. Gastroenterol Res Pract 2010;2010:901739.
12. Falor AE, Zobel M, Kaji A, Neville A, De Virgilio C. Admission variables predictive of gangrenous cholecystitis. Am Surg 2012;78:1075-8.
13. Wu B, Buddensick TJ, Ferdosi H, Narducci DM, Sautter A, Setiawan L, *et al*. Predicting gangrenous cholecystitis. HPB (Oxford) 2014;16:801-6.
14. Ansaloni L, Pisano M, Coccolini F, Peitzmann AB, Fingerhut A, Catena F, *et al*. 2016 WSES guidelines on acute calculous cholecystitis. World J Emerg Surg 2016;11:25.
15. Kiewiet JJ, Leeuwenburgh MM, Bipat S, Bossuyt PM, Stoker J, Boermeester MA. A systematic review and meta-analysis of diagnostic performance of imaging in acute cholecystitis. Radiology 2012;264:708-20.
16. Wu CH, Chen CC, Wang CJ, Wong YC, Wang LJ, Huang CC, *et al*. Discrimination of gangrenous from uncomplicated acute cholecystitis: Accuracy of CT findings. Abdom Imaging 2011;36:174-8.
17. Cheng SM, Ng SP, Shih SL. Hyperdense gallbladder wall sign: An overlooked sign of acute cholecystitis on unenhanced CT examination. Clin Imaging 2004;28:128-31.
18. Soyer P, Hoeffel C, Dohan A, Gayat E, Eveno C, Malgras B, *et al*. Acute cholecystitis: Quantitative and qualitative evaluation with 64-section helical CT. Acta Radiol 2013;54:477-86.
19. Revel L, Lubrano J, Badet N, Manzoni P, Degano SV, Delabrousse E. Preoperative diagnosis of gangrenous acute cholecystitis: Usefulness of CEUS. Abdom Imaging 2014;39:1175-81.