Article published online: 2021-07-26

Plain CT vs MR venography in acute cerebral venous sinus thrombosis: Triumphant dark horse

Poornima Digge, Koteshwar Prakashini[1], K V Bharath[2]

Department of Radio-Diagnosis, Pramukhswami Medical College, Karamsad, Gujarat, Departments of [1]Radio-Diagnosis and [2]Anaesthesia and Critical Care, Kasturba Medical College (KMC), Manipal, Karnataka, India

Correspondence: Dr. Poornima Digge, Assistant Professor, Department of Radio-Diagnosis, Pramukhswami Medical College, Karamsad, Gujarat, India. E-mail: dr.poornima04@gmail.com

Abstract

Context: Most patients with cerebral venous sinus thrombosis (CVST) present with nonspecific signs and symptoms and are likely to undergo nonenhanced head computed tomography (NCT) at presentation, which may show a normal report in up to two-thirds of patients. However, in case of acute thrombosis, sensitivity of diagnosing CVST is high as sinuses are hyperdense. Though magnetic resonance imaging (MRI) is considered the imaging modality of choice for diagnosing CVST, it is not universally available in an acute setting. **Aims:** To evaluate whether increased attenuation in cerebral venous sinuses in acute condition can be used to diagnose acute CVST and to determine its diagnostic value. **Materials and Methods:** The study involves two independent groups. One group of patients with sinus thrombosis were confirmed by MR venography (group A). The other group included patients without sinus thrombosis (group B). The HU (CT attenuation), hemoglobin (HGB), hematocrit (HCT), and H: H (HU: HCT) ratio of both groups were compared. Thirty-six patients (59 thrombotic sinuses) were studied in group A and 40 in group B. **Statistical Analysis:** Average HU and H: H ratio were compared using two-tailed *t*-test, and linear regression analysis was used to assess correlation between HCT and HU. **Results:** Average HU (73.7 vs 48.6) and H: H ratio values were higher in group A patients compared to group B ($P < 0.05$). Linear regression analysis showed positive correlation between HGB and HCT with HU among both the groups ($P < 0.05$). **Conclusions:** Our study demonstrates that acute CVST can be diagnosed using HU values in NCT.

Key words: Computed tomography; Hounsfield unit; intracranial venous sinus thrombosis; magnetic resonance imaging

Introduction

Cerebral venous sinus thrombosis (CVST) is predominantly a disease of young adults (<50 years old), accounting for 1-2% cases of stroke.[1,2] Most patients with CVST present with nonspecific signs and symptoms and are likely to undergo nonenhanced head computed tomography (NCT) at presentation. However, NCT may be normal in up to two-thirds of patients with venous sinus thrombosis.[3] In acute stages of thrombosis, the sensitivity of diagnosing CVST is higher as the sinuses are hyperdense. The findings on NCT are often subtle and nonspecific in the early stages which are evident as "hyperdense" venous sinuses and cerebral swelling.[3] Though magnetic resonance imaging (MRI) is considered the imaging modality of choice for diagnosing CVST, it is not universally available in an acute setting.[4,5] Moreover, it is also known for artefacts,

Access this article online	
Quick Response Code:	Website: www.ijri.org
	DOI: 10.4103/ijri.IJRI_328_17

Cite this article as: Digge P, Prakashini K, Bharath KV. Plain CT vs MR venography in acute cerebral venous sinus thrombosis: Triumphant dark horse. Indian J Radiol Imaging 2018;28:280-4.

flow-related void rendering it as a suboptimal study for diagnosing CVST.

One alternative diagnostic modality could be CT venography (CTV), which is more readily available compared to MRI. CTV is nearly as good as MRI or may be even better in some cases.[6] With recent advancement in technology, CTV and MR venography (MRV) have now replaced digital subtraction cerebral angiography as the diagnostic test of choice for CVST.[4,7-9] Hyperdense sign of venous sinuses on NCT scan has a sensitivity of 84% and 95% and specificity of 96% and 95% with a HU (Hounsfield unit) cut-off value of 65 and 62, respectively, as shown by some recent studies.[10,11] Measurement of H:H ratio (average HU vs hematocrit) in addition to venous sinus attenuation is likely to increase sensitivity.[11] Complications such as venous infarcts and fragmented hemorrhage occur late during the course of CVST, which are easily diagnosed on NCT; hence, diagnosing CVST at initial stages remains challenging.

The primary aim of the present study was to evaluate whether increased attenuation in cerebral venous sinuses in acute condition (less than 3 days) can be used to diagnose acute CVST and to determine its diagnostic value. The secondary aim was to determine whether there is possible correlation between HCT and HU.

Early detection of CVST is important as initiation of anticoagulation therapy is thought to prevent the propagation of thrombus and subsequent venous infarcts and hemorrhage. This in turn reduces the mortality and morbidity associated with long-term neurological sequelae.[12]

Patients and Methods

This was a retrospective, observational study conducted between December 2013 and December 2015 in a tertiary care hospital. The study involved two independent groups. One group of patients with sinus thrombosis confirmed by MR venography (group A) who underwent NCT. For group B (nonthrombotic/control), we retrospectively reviewed data of NCT in 200 patients with complaints of headache and seizures whose study was normal. Out of the 200 patients, those who underwent MRV but did not show any evidence of venous sinus thrombosis were included in group B (control). The HU, hemoglobin (HGB), hematocrit (HCT), and H:H (HU to HCT) ratio of both groups were recorded and compared.

Patients in the age group of 10–80 years of either sex who underwent MRV within 24 hours of NCT were included in both the groups. Only patients who had an acute history (<3 days) and whose HGB and HCT reports were available within 24 hours of scan were included in the study group. Patients with a history of trauma, intracranial surgery, intracranial artefacts, and those who received contrast 24 hours prior to the scan were excluded.

All patients were imaged on Philips brilliance 64 slice CT scanner. Images were acquired by using CT parameters of 120 kV; section thickness, 5 mm (reconstruction images slice thickness, 1 mm); 300 mA; and pitch, 0.675.

We retrospectively reviewed and analyzed the data through radiology information system PACS (Picture Archiving and Communication System).

In group A patients, HU was measured in individual thrombotic segments. For patients with multiple sinus thrombosis, average HU of all thrombosed sinuses (hyperdense segments) on CT was taken for ease of comparison. Each segment is a single venous sinus which go by the name SSS, transverse sinus, sigmoid sinus, and others.

In a previous study, Black *et al*. concluded that variation in the size of region of interest (ROI) does not have different HU's.[13] We used the best fit circle for HU measurement in group B patients at the inferior aspect of superior sagittal sinus (SSS) and at venous confluence in axial image [Figure 1A and B]. The other cerebral venous sinuses in group A patients were also measured in axial image, where it was best seen [Figures 1C, 2A and B]. Minimum, maximum, and average HU were noted. We also calculated the H: H ratio for each patient to normalize observed blood attenuation with regard to hemoconcentration.

Statistical analysis

Baseline parameters such as age, sex ratio, HGB, HCT, and average HU, between patients with and without thrombosis were compared using two-tailed unpaired *t*-test. To assess the correlation between HGB and HCT with measured CT attenuation linear regression analysis was used. Two-tailed unpaired *t*-test was used to compare H:H ratio between patients with and without sinus thrombosis.

Results

After meeting inclusion and exclusion criteria, 36 patients (59 thrombotic sinuses) were included in group A, and out of 200 patients, 40 were included in group B. Analysis was carried out as shown in Table 1.

In patients without sinus thrombosis (group B), the age group ranged from 10 to 78 years (average 40.4 years and SD 19.2). Average age of males was 39.2 years and that of females was 41.8 years. In patients with sinus thrombosis (group A), age group ranged from 17 to 61 years (average 31.7 years and SD 10.7). Average age of male patients was 30.2 years whereas in female patients it was 37 years.

HU values were higher in group A patients (73.7 vs 48.6) ranging from 62.3 to 80.7. Except for 3 patients in group A, all patients had HU values above 70. HU values in group B ranged from 31.2 to 64.1 [Figure 3]. ROC curve analysis of HU shows an area under the curve of 1.0 with cut-off of 70 as well as sensitivity of 92% and specificity of 100%.

Average hematocrit value was higher in group A patients, 46.2 (SD 8.2) whereas it was 38.8 (SD 7) in group B patients. H:H ratio in patients without thrombosis ranged from 0.95 to 2.38 (mean 1.27), and in patients with thrombosis it ranged from 1.24 to 2.41 (mean 1.64).

There was statistically significant difference between both the groups in terms of age, sex, HGB, HCT, average HU, and H:H ratio ($P < 0.05$). Linear regression analysis showed positive correlation between HGB and HCT with CT attenuation (HU) among both the groups ($P < 0.05$).

Discussion

Hyperattenuation of cerebral sinuses is particularly seen in acute stages of thrombosis. The increase in attenuation occurs due to clot retraction, elimination of water, and increased concentration of red blood cells (RBC) and hemoglobin, thus resulting in high HU values. As time passes, RBC and hemoglobin gets degraded, and hence, the attenuation gradually decreases over several days.[14] Therefore, there is normalization of HU values in subacute and chronic stages of CVST.

In our study, we included only those patients who had acute symptoms (less than 3 days) and measured HU density in venous sinuses. Average HU value in our study was 73.7 (SD 3.8) in group A and 48.6 (SD 7.7) in group B. To our knowledge, no study have been done to provide a definitive cut-off value of HU for CVST on NCT. Black *et al.* considered 70 HU as a cut-off for suspecting thrombosis, but they also concluded that further studies needed to confirm

Table 1: Comparison of baseline parameters, HU and H: H ratio values between both the Groups

Parameters	Group A (36)	Group B (40)	*P*
Avg age (range, SD)	31.7 (17-61, 10.7)	40.4 (10-78,19.2)	0.03
Male	30.2 (17-53, 8.5)	39.2 (12-70,17.8)	
Female	37 (22-61, 16.1)	41.8 (10-78, 21.1)	
Sex (M: F)	28:8	22:18	0.03
HGB (range, SD)	14.8 (8.7-20.5, 2.7)	12.6 (6.7-18.6, 2.3)	0.00
Male	15.7 (8.9-20.5, 2.2)	13.1 (6.7-18.6, 2.6)	
Female	11.8 (8.7-15.3, 2.18)	12 (7.5-14.7, 1.66)	
HCT (range, SD)	46.2 (27.4-61.3, 8.2)	38.8 (19.1-55.9, 7)	0.00
Male	49 (31.9-61.3, 6.18)	40.1 (19.1-55.9, 8.4)	
Female	36.4 (27.4-46.8, 7)	37.3 (27.2-47.8, 4.8)	
HU (range, SD)	73.7 (62.3-80.7, 3.8)	48.6 (31.2-64.1, 7.7)	0.00
Male	74.7 (69.6-80.7, 3.3)	49.2 (31.2-61.8, 8.2)	
Female	70.4 (62.3-75.9, 3.97)	47.9 (33-64.1, 7.29)	
H:H ratio (range, SD)	1.64 (1.24-2.41, 0.29)	1.27 (0.95-2.38, 0.23)	0.00
Male	1.54 (1.24-2.18, 0.19)	1.26 (0.95-2.38, 0.29)	
Female	1.98 (1.51-2.41, 0.34)	1.28 (1.01-1.5, 0.12)	

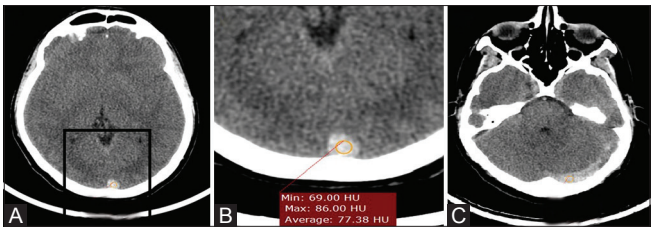

Figure 1 (A-C): A 23-year-old male patient presented with headache; plain CT scan shows superior sagittal sinus thrombosis (HU, 77.38) in A. A is zoomed to show the best fit ROI in SSS, which is showing thrombosis (B) and left transverse sinus thrombosis (HU, 70) in C

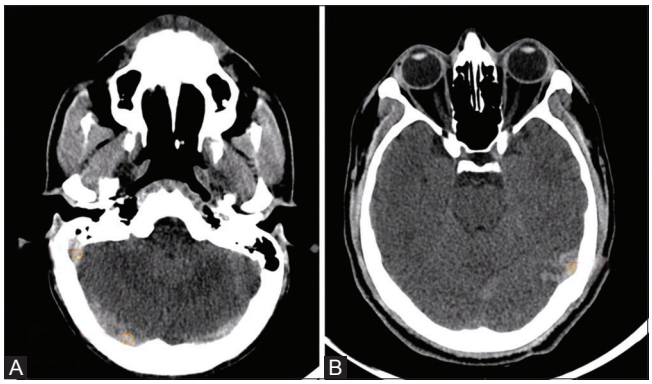

Figure 2 (A and B): A 21-year-old male patient presented with altered sensorium. Unenhanced CT scan of head shows thrombosis in right transverse sinus (HU, 74.5) and right sigmoid sinus (HU, 75) in A and left transverse sinus (HU, 77.8) thrombosis in B

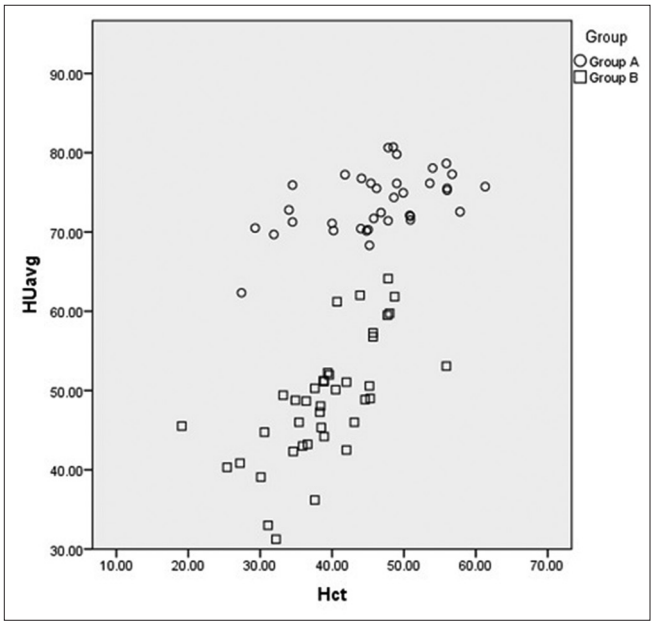

Figure 3: Scatterplot of sinus attenuation (HU average) vs HCT comparing both groups (○ = Group A, □ = Group B)

the diagnosis.[13] In our study, we observed that CT HU of >70 confirms thrombosis in group A patients compared to group B whose HU values were less than 64.1 (average 48.6).

As per our study, HU >70 is highly valuable for diagnosing thrombosis (sensitivity 92% and specificity 100%), and further investigation is not required to confirm the diagnosis. Similarly, HU value of <64 is very specific in ruling out thrombosis. Drawback of these HU value occurs when it is in the intermittent range, which happens as the stage of thrombosis moves to subacute or chronic phase. We may misinterpret HU values as normal, and in such cases, it is advisable to perform venography.

Recent studies showed sensitivity (84% and 95%) and specificity (96% and 95%) with an HU cut-off value of 65 and 62, respectively.[10,11] Black *et al*. noted that patients with CVST often had a HU of >70 and those without had a HU of <70; H: H ratio of >2 also showed a good correlation with CVST. They also demonstrated a correlation between the patient's HCT and venous sinus density (HU).[13] In a recent study by Ali Alsafi *et al*., 768 venous sinuses were analyzed; 46 with CVST and 720 without. The average HU of vessels containing a thrombus was 68 ± 1.56, which was significantly higher than that of normal vessels 52 ± 0.28.[15]

In our study, H:H ratio showed a value of 1.64 ± 0.29 in patients with thrombosis and 1.27 ± 0.23 in patients without thrombosis. Black *et al*. found mean H: H values of 2.20 in patients with CVST and 1.44 in patients without CVST.[13] Buyck *et al*. study also showed higher mean H:H value in patients with acute CVST (1.91 vs 1.33).[11] Compared to other studies, a little overlap of H:H ratio values were seen between the groups in our study [Figure 4],[11,13] whereas HU values showed almost no overlap between the groups [Figure 5].

ROC curve analysis of H:H ratio showed an area of 0.90 and with an optimum cut-off of 1.40 for sensitivity of 86% and specificity of 82.5%. A threshold value of 1.50 gives a high specificity of 95% but with low sensitivity (64%). A study by Besachio *et al*. reported a higher H: H ratio value of 1.7 for similar sensitivity and specificity.[10] An H: H ratio of more than 1.52 suggests a strong likelihood of a clot (sensitivity 95%, specificity 100%), as recommended by Buyck *et al*.[11] Black *et al*. suggested a threshold value of 1.8 to suspect the presence of thrombosis.[13]

In most centres in an acute setting, clinician prefers plain CT of the head. Early detection and initiation of treatment is mandatory in these cases. MRI is time consuming and moreover patient cooperation is important. Thus, if acute CVST is diagnosed accurately in plain CT scan itself, we can save valuable time and start the required treatment at the earliest which can further reduce the complications or disease progression. As the age of thrombosis increases, and if the treatment is not started early, there is a high chance of extension of thrombus across multiple venous sinuses and venous hemorrhagic infarct may also occur. This leads to significant morbidity to the patient.

Limitations of the study

This was a retrospective study, and the sample size in the thrombotic group was less. However, the number of patients were more compared to several previous studies. No data is available regarding hydration and medication status of patients. Interobserver variability in measuring ROI was not calculated.

Conclusion

In case of an acute setting, plain CT is specific for the diagnosis of acute CVST, but as the age of the clot

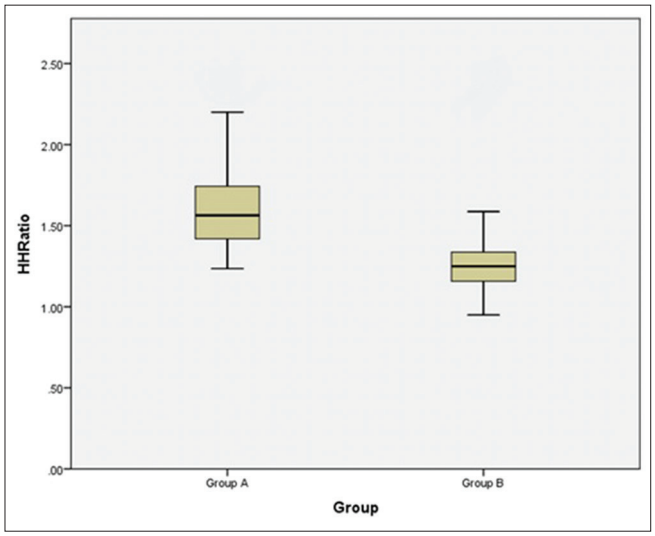

Figure 4: Box plot showing average H:H ratio values compared between both the groups

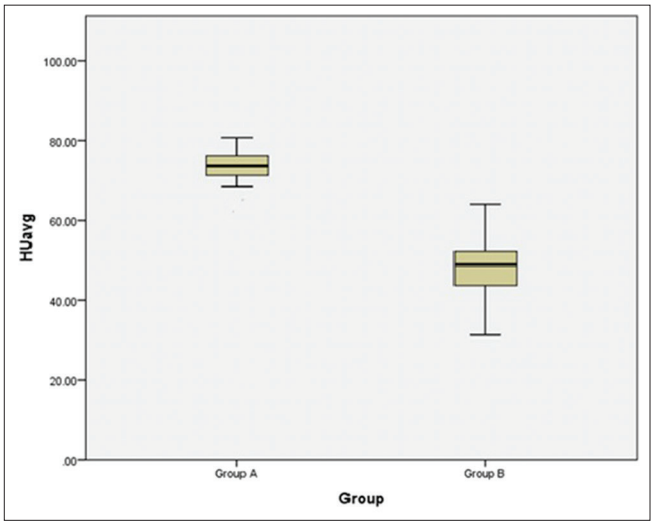

Figure 5: Box plot showing average sinus attenuation values (HU) compared between both the groups

progresses, density of venous sinuses reduces. Based on our study, we recommend 70 HU as the cut-off value (sensitivity 92%, specificity 100%) for diagnosis of CVST, and there is no need for further confirmatory studies such as venography.

It is important to note that a normal HU value does not exclude the presence of thrombosis in venous sinuses. In patients with possible risk factors for thrombosis or unexplained symptoms, further conclusive imaging studies such as CTV or MRI should be done despite a negative head CT.

Financial support and sponsorship

Nil.

Conflicts of interest

There are no conflicts of interest.

References

1. Bousser MG, Ferro JM. Cerebral venous thrombosis: An update. Lancet Neurol 2007;6:162-70.
2. Canhão P, Ferro JM, Lindgren AG, Bousser MG, Stam J, Barinagarrementeria F; ISCVT Investigators. Causes and predictors of death in cerebral venous thrombosis. Stroke 2005;36:1720-5.
3. Poon CS, Chang JK, Swarnkar A, Johnson MH, Wasenko J. Radiologic diagnosis of cerebral venous thrombosis: Pictorial review. AJR Am J Roentgenol 2007;189:S64-75.
4. Saposnik G, Barinagarrementeria F, Brown RD Jr, Bushnell CD, Cucchiara B, Cushman M *et al.* Diagnosis and management of cerebral venous thrombosis: A statement for healthcare professionals from the American Heart Association/American Stroke Association. Stroke 2011;42:1158-92.
5. Qu H, Yang M. Early imaging characteristics of 62 cases of cerebral venous sinus thrombosis. Exp Ther Med 2013;5:233-6.
6. Ozsvath RR, Casey SO, Lustrin ES, Alberico RA, Hassankhani A, Patel M. Cerebral venography: comparison of CT and MR projection venography. AJR Am J Roentgenol 1997;169:1699-707.
7. Janjua, N. Cerebral angiography and venography for evaluation of cerebral venous thrombosis. J Pak Med Assoc 2006;56: 527-30.
8. Rizzo L, Crasto SG, Rudà R Gallo G, Tola E, Garabello D, *et al*. Cerebral venous thrombosis: role of CT, MRI and MRA in the emergency setting. Radiol Med 2010;115:313-25.
9. Wasay M, Azeemuddin M. Neuroimaging of cerebral venous thrombosis. J Neuroimaging 2005;15:118-28.
10. Besachio DA, Quigley EP 3rd, Shah LM, Salzman KL. Noncontrast Computed Tomographic Hounsfield unit evaluation of Cerebral venous thrombosis: A quantitative evaluation. Neuroradiology 2013;55:941-5.
11. Buyck PJ, De Keyzer F, Vanneste D, Wilms G, Thijs V, Demaerel P. CT density measurement and H: H ratio are useful in diagnosing acute cerebral venous sinus thrombosis. AJNR Am J Neuroradiol 2013;34:1568-72.
12. Coutinho J, de Bruijn SF, Deveber G, Stam J. Anticoagulation for cerebral venous sinus thrombosis. Cochrane Database Syst Rev 2011;10:CD002005.
13. Black DF, Rad AE, Gray LA, Campeau NG, Kallmes DF. Cerebral venous sinus density on noncontrast CT correlates with hematocrit. AJNR Am J Neuroradiol 2011;32:1354-7.
14. Virapongse C, Cazenave C, Quisling R, Sarwar M, Hunter S. The empty delta sign: Frequency and significance in 76 cases of dural sinus thrombosis. Radiology 1987;162:779-85.
15. Alsafi A, Lakhani A, Carlton Jones L, Lobotesis K. Cerebral Venous Sinus Thrombosis, a Nonenhanced CT Diagnosis?. Radiol Res Pract 2015;2015:581437.