Article published online: 2021-07-26



# t-PA power-pulse spray with rheolytic mechanical thrombectomy using cross-sectional image-guided portal vein access for single setting treatment of subacute superior mesenteric vein thrombosis

Mubin I. Syed[1,2], Ryan M. Gallagher[2], Rukan S. Ahmed[3], Azim Shaikh[1], Edward Roberto[2], Sumeet Patel[1]

[1]Dayton Interventional Radiology, Dayton, [2]Wright State University, Boonshoft School of Medicine, Dayton, Ohio, [3]Lincoln Memorial University-DeBusk College of Osteopathic Medicine, Harrogate, Tennessee, USA

**Correspondence:** Dr. Mubin I. Syed, 3075 Governors Place Blvd., Ste. 120, Dayton, Ohio, USA. E-mail: mubinsyed@aol.com

## Abstract

**Background:** Isolated superior mesenteric vein (SMV) thrombosis is a rare but potentially fatal condition if untreated. Current treatments include transjugular or transhepatic approaches for rheolytic mechanical thrombectomy and subsequent infusions of thrombolytics. Tissue plasminogen activator (t-PA) power-pulse spray can provide benefit in a single setting without thrombolytic infusions. Computed tomography (CT) guidance for portal vein access is underutilized in this setting. **Materials and Methods:** Case 1 discusses acute SMV thrombosis treated with rheolytic mechanical thrombectomy alone using ultrasound guidance for portal vein access. Case 2 discusses subacute SMV thrombosis treated with the addition of t-PA power-pulse spray to the rheolytic mechanical thrombectomy, using CT guidance for portal vein access. **Results:** With rheolytic mechanical thrombectomy alone, the patient in Case 1 had significant improvement in abdominal pain. Follow-up CT demonstrated no residual SMV thrombosis and the patient continued to do well in long-term follow-up. With the addition of t-PA power-pulse spray to rheolytic mechanical thrombectomy, the patient in Case 2 with subacute SMV thrombosis dramatically improved postprocedure with resolution of abdominal pain. Follow-up imaging demonstrated patency to the SMV and partial resolution of thrombus. The patient continued to do well at 2-year follow-up. **Conclusions:** Adding t-PA power-pulse spray to rheolytic mechanical thrombectomy can provide benefit in a single setting versus mechanical thrombectomy alone and prevent the need for subsequent infusions of thrombolytic therapy. CT guidance is a useful alternative of localization for portal vein access via the transhepatic route that is nonoperator-dependent and helpful in the case of obese patients.

**Key words:** CT guidance portal vein access; rheolytic mechanical thrombectomy; superior mesenteric vein thrombosis, t-PA power-pulse spray



| Access this article online | |
|---|---|
| Quick Response Code: | **Website:** www.ijri.org |
| | **DOI:** 10.4103/ijri.IJRI_215_17 |

**Cite this article as:** Syed MI, Gallagher RM, Ahmed RS, Shaikh A, Roberto E, Patel S. t-PA power-pulse spray with rheolytic mechanical thrombectomy using cross-sectional image-guided portal vein access for single setting treatment of subacute superior mesenteric vein thrombosis. Indian J Radiol Imaging 2018;28:93-8.

## Introduction

Superior mesenteric vein (SMV) thrombosis is a rare, yet potentially life-threatening condition with a mortality of greater than 90% if untreated. Treatment with surgery (bowel resection) and surgical thrombectomy results in a mortality rate of 20%.[1] Recently, percutaneous interventions, including thrombolytic infusions and mechanical thrombectomy, have offered excellent results with reduced mortality.[2,3] Approaches have included both transhepatic (fluoroscopic cholangiographic technique and ultrasound guidance) and transjugular intrahepatic access. The technique has been contraindicated in patients with evidence of infarcted bowel.

We present two cases for comparison of different treatment techniques. The first case discusses the utilization of rheolytic mechanical thrombectomy alone for acute (within one week) SMV thrombosis. A transhepatic approach was utilized with ultrasound-guided left portal vein access. The second case discusses the addition of t-PA power-pulse spray to rheolytic mechanical thrombectomy for subacute (1–3 weeks, more organized) SMV thrombosis. In the second case, we highlight the utilization of cross-sectional CT guidance (besides standard ultrasound guidance) to gain right transportal vein access for intervention.

The uniqueness of this technique is that cross-sectional anatomical guidance (CT) for portal vein access was used in addition to performing the intervention with t-PA power-pulse spray rheolytic thrombectomy. CT guidance does not appear to have previously been described for portal vein access in this clinical scenario. Thus, some major technological advancements were incorporated for the successful treatment of this life-threatening condition in one setting. In both cases, the transhepatic tract was embolized using gel foam and embolization coils.

## Case History

### Case 1

The patient was a 39-year-old woman with a history of stage four colon cancer status post left hemicolectomy and resection of liver metastasis with no measurable disease and normal carcinoembryonic antigen level. She was status postchemotherapy with FOLFOX and Avastin with 11 of 12 treatments received (every 2 weeks). The patient presented with a 2-day history of abdominal cramping and periumbilical pain. She also had an episode of bright red blood per rectum. CT demonstrated isolated acute SMV thrombosis [Figure 1]. Colonoscopy demonstrated mild inflammation of the rectosigmoid junction with no active bleeding.

The patient was then referred for SMV intervention. The right portal vein was accessed transhepatically with ultrasound guidance. A 6 FR vascular sheath was then placed. A Kumpe catheter (Cook, Bloomington, IN) with angle tipped glidewire was then used to catheterize the SMV. Note was made of extensive thrombus within the SMV [Figure 2]. Rheolytic [Angiojet (Possis Medical, Minneapolis, MN)] thrombectomy was performed with marked angiographic improvement [Figure 3]. A small gel foam plug was placed in the hepatic tract allowing sheath removal. The patient had dramatic improvement in her abdominal pain and was discharged on anticoagulation. There was no complication post-procedure. Follow-up CT demonstrated no residual SMV thrombosis [Figure 4]. The patient continued to do well 3 years and 1 month post-intervention.

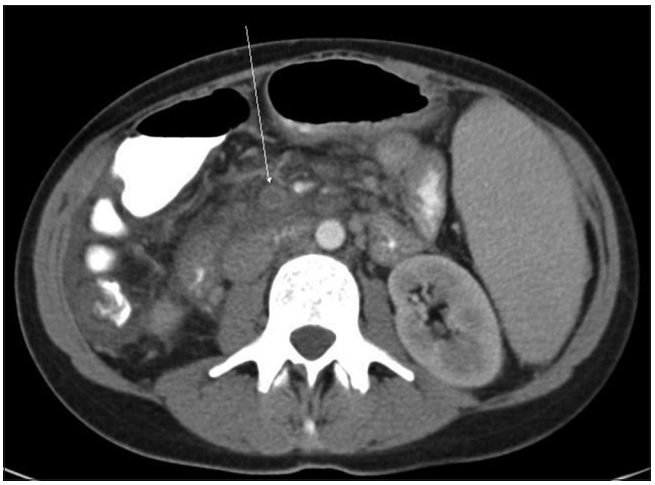

**Figure 1:** Case 1: CT of the abdomen with IV contrast. Arrow points to the SMV which has a round nonenhancing filling defect consistent with acute thrombus

### Case 2

A 62-year-old obese man was admitted with one and one-and-half weeks of severe lower abdominal pain, nausea/vomiting, leukocytosis, and diarrhea. His symptoms were attributed to viral causes because his family members had similar symptoms. He was initially treated with NPO status, IV hydration, analgesia, and antiemetics. However, his nausea, vomiting, and diarrhea persisted. Therefore, gastroenterologist was consulted and stool studies were performed. The patient subsequently developed worsening emesis and was noted to be acidotic. Mesenteric ischemia was therefore considered. CT of the abdomen was obtained and demonstrated isolated subacute SMV thrombosis with mesenteric edema within a loop of bowel involving the ileum as well as ascites. There was no CT evidence of bowel obstruction. The patient was initially given IV heparin and warfarin with improvement in his symptoms. He then developed a small bowel obstruction (confirmed with repeat CT) with further worsening of nausea and vomiting requiring a nasogastric tube with suctioning [Figures 5–7]. Intervention was therefore offered due to his clinical deterioration despite adequate anticoagulation.


**Figure 2:** Case 1: Selective superior mesenteric venogram (digital subtraction technique). Note catheter tip within the inferior portion of the SMV. The venogram demonstrates luminal narrowing and filling defects consistent with acute thrombus

**Figure 4:** Case 1: CT of the abdomen with IV contrast at 3 months post-intervention. Note restoration of complete patency to SMV

Because the patient was in the Interventional Radiology Department, only vascular access ultrasound was available. Abdominal imaging capability with the diagnostic ultrasound unit (from the ultrasound department) was not available at the time. However, CT was readily available at the time; therefore, it was decided to use CT guidance for portal vein access. CT was used to visualize the right portal vein anterior division bifurcation. This was punctured with CT guidance via a right lateral lower intercostal approach using a 22 gauge Chiba needle (Cook, Bloomington, IN). A 0.018-inch guidewire was advanced into the portal vein from a Neff set (Cook, Bloomington, IN). Intraluminal guidewire position was confirmed with CT. The patient was then transferred to the angiography


**Figure 3:** Case 1: Superior mesenteric venogram post thrombectomy. Note restoration of patency to SMV

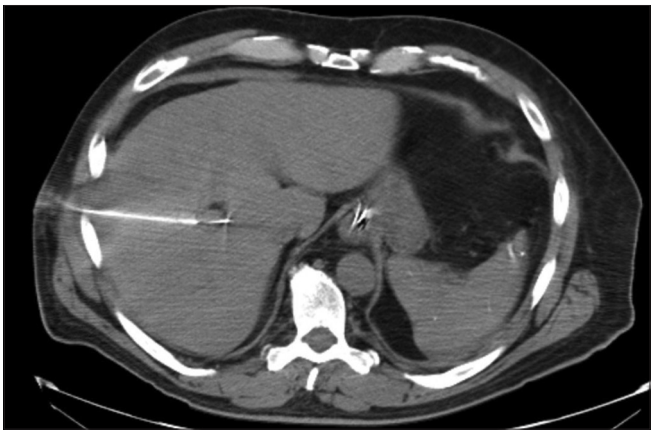

**Figure 5:** Case 2: CT of the abdomen demonstrating CT-guided transhepatic portal vein access

suite. A 0.018-inch Quick-Cross Select Support Catheter (Spectranetics, Colorado Springs, CO) was advanced over the wire and hand injected to confirm intraluminal guidewire position in the portal vein. Next the 6.5 FR sheath of the Neff set was advanced into the portal vein. A stiff glidewire (Terumo Medical Corporation, Japan) was advanced through the Neff dilator into the portal vein. A standard 6 FR vascular sheath was then advanced through the tract into the right portal vein. A portal venogram was then performed that demonstrated patency of the main portal vein and its branches. Using anatomic landmarks from the CT scan, the SMV was catheterized with a 5 FR Kumpe catheter and Roadrunner (Cook, Bloomington, IN) hydrophilic guidewire. Hand injection of this vein demonstrated complete thrombosis. Angiojet thrombectomy was initially performed with the DVX catheter (Possis Medical Inc., Minneapolis, MN) without

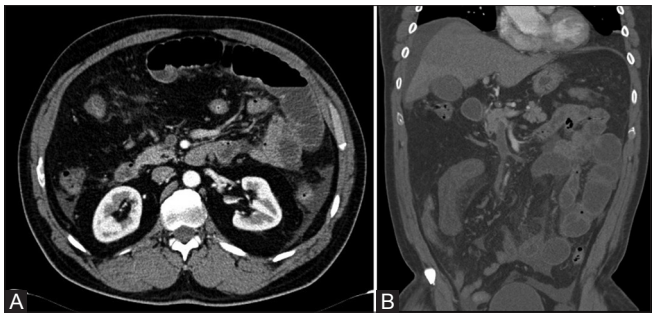


**Figure 6 (A and B):** (A) Case 2: CT of the abdomen with IV contrast demonstrating filling defect within the SMV (nonopacification) consistent with subacute thrombus. (B) Case #2: CT of the abdomen with IV contrast coronal reconstruction demonstrates venous distention due to occlusive thrombosis of the SMV and its branches

significant improvement. Power-pulse spray t-PA infusion was then performed with 25 mg of t-PA and 15-min dwell time. Angiojet thrombectomy was then repeated throughout the SMV main trunk along with jejunal and ileal branches. There was restoration of some patency, although the result was not dramatic. Because the patient had known edema within his terminal ileum with possible ischemia, it was believed that he would be potentially prone to intraperitoneal hemorrhage (with prolonged thrombolytic infusion). Overnight catheter-directed infusion of t-PA was considered, but not offered. The tract was embolized with gel foam and 3 × 4 $mm^2$ embolization coils (Cook, Bloomington, IN) prior to removal of the sheath to prevent bleeding.

The patient dramatically improved within 24 h post-procedure. His NG tube was removed and he was able to tolerate oral intake within 48 h. His abdominal pain also resolved. CT of the abdomen with IV contrast at 1-month post-intervention demonstrated decreased thrombus burden (with decreased venous distention) in the SMV and its branches [Figure 8A and B]. The patient was discharged on anticoagulation and continued to do well at 2-year follow-up. Magnetic resonance venography of the abdomen at 5 months also showed patency of the SMV and partial resolution of the thrombus and multiple large collateral veins visualized. It was later discovered by the hematologist after discharge that the cause of the patient's thrombosis was antiphospholipid antibody syndrome. The hematologist recommended treatment with lifelong anticoagulation.

## Discussion

Superior mesenteric venous thrombosis is an uncommon condition accounting for 5–20% of all mesenteric ischemia.[4] It is a potentially fatal condition that has a current 30-day mortality rate of 20% even with anticoagulation, bowel resection, and operative mesenteric vein thrombectomy.[5] Etiologies of SMV thrombosis are multiple and often associated with portal hypertension,


**Figure 7:** Case 2: Selective superior mesenteric venogram (digital subtraction technique) demonstrates occlusive thrombosis of the SMV and its branches

inflammatory states, postoperative states, trauma, hypercoagulable states, renal disease, and cardiac disease.[6]

SMV thrombosis presents typically as vague abdominal pain progressing over 7–10 days. Often the pain is out of proportion to the physical examination findings. Abdominal distention may be present along with occult or overt gastrointestinal bleeding. The rate of hemorrhage is 28% for upper and 23% for lower gastrointestinal tracts.[7] This may have implications for prolonged thrombolytic infusions. Intestinal ischemia leading to infarction may occur necessitating surgery. Spiral CT with contrast will usually demonstrate a filling defect within the SMV. Secondary signs of bowel distention and bowel wall edema may be seen along with ascites. Frank small bowel obstruction may also be seen.

Standard treatment of SMV thrombosis includes medical therapy consisting of anticoagulation, intravenous hydration, and bowel rest with NG suctioning if needed. Surgical treatment is necessitated when peritoneal signs have developed due to intestinal infarction. Operative mesenteric vein thrombectomy is rarely performed.

In recent years, percutaneous intervention has shown great promise. Approaches include thrombolytic infusion via indirect superior mesenteric artery, or direct portal vein access via transhepatic or transjugular intrahepatic approaches.[8-14] A transsplenic approach for accessing the portal vein also exists, but is not as widely utilized.[15,16] The transhepatic approach can be performed using the standard

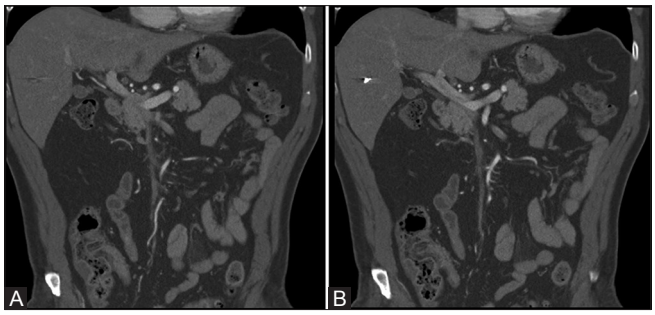


**Figure 8 (A and B):** Case 2: CT of the abdomen with IV contrast coronal reconstruction at 1 month postintervention demonstrates decreased thrombus burden (with decreased venous distention) in the SMV and its branches

cholangiographic technique and fluoroscopic guidance, but may require numerous passes, which could potentially predispose the patient to hemorrhage.

Sonographic guidance can be useful and has been successful in direct access of the portal vein.[17] Nevertheless, portal vein access can be technically demanding in the obese patient. CT is a readily available option in most departments and can overcome the limitations of ultrasound. While it does not provide the real-time visualization that ultrasound provides, CT is not operator-dependent and may allow one to track the wire easily once portal vein access has been achieved to confirm intraluminal positioning. CT guidance has previously been described for marking the area just outside of the portal vein for the purpose of subsequent TIPS procedures.[18] To our knowledge, no one has reported using CT guidance for portal vein access in the clinical setting of isolated SMV thrombosis. The patient does have to be transferred to the angiography suite for intervention which can result in some delay. A transjugular intrahepatic approach would be the best approach if there was a preexisting TIPS.[19] On the contrary, this may add to the complexity of the procedure if it is simply done as a means to obtain access to the SMV. It has been described successfully by operators who perform large numbers of TIPS.[20,21]

Mechanical thrombectomy has been described via either the transhepatic or transjugular intrahepatic approaches as both adjunctive to thrombolytic infusion and stand-alone therapy. Devices utilized have included manual guiding catheter suction thrombectomy, pigtail fragmentation catheter, as well as commercially available mechanical devices, including Angiojet, Amplatz, and Trerotola devices.[7,8,21,22]

The use of thrombolytic infusion and mechanical thrombectomy can be combined with pharmaco-mechanical technique. This can be performed simply by lacing the thrombus with thrombolytic agent using catheter direction or manual pulse spray technique. This is followed by a relatively short dwell time (15–45 min); mechanical thrombectomy is then performed. Power-pulse spray thrombectomy may be considered as an advancement of this technique. In this procedure, the thrombolytic agent is forcibly injected into the thrombus using the energy generated by the thrombectomy device. This technique has successfully been able to clear portal vein thrombus in a single setting.[23] One advantage of this technique is that the systemic toxicity of thrombolytic infusion can be avoided while clot disruption and dissolution can occur at much higher efficacy (even prior to the action of mechanical thrombectomy).

This technique could be particularly useful in the setting of a patient with ischemic bowel (within a subacute presentation) who may not benefit from mechanical thrombectomy alone. In such a patient, a prolonged (overnight) thrombolytic infusion may result in a life-threatening hemorrhage. In one series in prolonged thrombolytic infusions, 60% had major complications including one death. Most major complications in this series included bleeding and decreased hematocrit.[2]

The uniqueness of this technique is that cross-sectional anatomical guidance (CT) for portal vein access was used in addition to performing the intervention with t-PA power-pulse spray rheolytic thrombectomy (Case 2). As noted previously, CT guidance does not appear to have previously been described for portal vein access in this clinical scenario. Thus, some major technological advancements have been incorporated for the successful treatment of this life-threatening condition in one setting.

The limitations of CT versus ultrasound include: 1) In CT-guided portal vein access, intravenous iodinated contrast may be necessary, which may be problematic for patients with renal insufficiency. However, often the portal vein/porta hepatis may be visualized without contrast. 2) Portal vein access using CT may be more time-consuming than with ultrasound depending upon operator skill. On the contrary, CT imaging is less operator-dependent. 3) There is a definite risk of transpleural access and pneumothorax due to lack of real-time imaging and respiratory variation. Fortunately, this can be recognized immediately and in an early stage with CT imaging and corrected with a chest tube (if clinically warranted) should this complication arise. 4) Shifting the patient from CT to interventional radiology may be cumbersome with a risk of losing the access to the SMV/portal vein. Placing a guidewire gently through the catheter may be helpful to provide more purchase to these veins.

The limitations of the power-pulse spray technique are that in older (2 weeks old) thrombi, the thrombus may not be completely removed. It is noted, however, that lack of significant angiographic improvement may still result in dramatic clinical improvement, ultimately with complete resolution of symptoms. Perhaps this is due to restoration of collateral flow that may be sufficient.

In summary, SMV thrombosis is a rare yet potentially life-threatening condition if not addressed appropriately; however, multiple treatment options exist, with an emphasis on less invasive percutaneous transhepatic or transjugular approaches. In the case of acute SMV thrombosis, rheolytic mechanical thrombectomy alone may be sufficient. However, in the case of subacute SMV thrombosis, that alone may not be enough. The addition of t-PA power pulse spray may permit efficacious treatment of subacute SMV thrombosis in a single treatment instance and may prevent the need for an overnight infusion of thrombolytics. Although ultrasound guidance is commonly used in gaining portal access, CT guidance may provide a useful alternative that is not operator-dependent and can be especially helpful in the obese patient. With this technical utilization, t-PA power-pulse spray may prove to be beneficial in the treatment of acute to subacute SMV thrombosis.

### Declaration of patient consent

The authors certify that they have obtained all appropriate patient consent forms. In the form the patient has given her consent for her images and other clinical information to be reported in the journal. The patient understands that name and initial will not be published and due efforts will be made to conceal identity, but anonymity cannot be guaranteed.

### Financial support and sponsorship

Nil.

### Conflicts of interest

There are no conflicts of interest.

## References

1. Goldberg MF, Kim HS. Treatment of acute superior mesenteric vein thrombosis with percutaneous techniques. AJR Am J Roentgenol 2003;181:1305-7.
2. Hollingshead M, Burke CT, Mauro MA, Weeks SM, Dixon RG, Jaques PF. Transcatheter thrombolytic therapy for acute mesenteric and portal vein thrombosis. J Vasc Interv Radiol 2005;16:651-61.
3. Liu FY, Wang MQ, Fan QS, Duan F, Wang ZJ, Song P. Interventional treatment for symptomatic and acute-subacute portal and superior mesenteric vein thrombosis. World J Gastroenterol 2009;15:5028-34.
4. Rivitz SM, Geller SC, Hahn C, Waltman AC. Treatment of acute mesenteric venous thrombosis with transjugular intramesenteric urokinase infusion. J Vasc Interv Radiol 1995;6:219-23; discussion 224-8.
5. Hedayati N, Riha GM, Kougias P, Huynh TT, Chang C, Bechara C, *et al*. Prognostic factors and treatment outcome in mesenteric vein thrombosis. Vasc Endovascular Surg 2008;42:217-24.
6. Grendell JH, Ockner RK. Mesenteric venous thrombosis. Gastroenterology 1982;82:358-72.
7. Sze DY, O'Sullivan GJ, Johnson DL, Dake MD. Mesenteric and portal venous thrombosis treated by transjugular mechanical thrombolysis. AJR Am J Roentgenol 2000;175:732-4.
8. Wang MQ, Liu FY, Duan F, Wang ZJ, Song P, Fan QS. Acute symptomatic mesenteric venous thrombosis: Treatment by catheter-directed thrombolysis with transjugular intrahepatic route. Abdom Imaging 2011;36:390-8.
9. Yang S, Liu B, Ding W, He C, Wu X, Li J. Acute superior mesenteric venous thrombosis: Transcatheter thrombolysis and aspiration thrombectomy therapy by combined route of superior mesenteric vein and artery in eight patients. Cardiovasc Intervent Radiol 2015;38:88-99.
10. Rosen MP, Sheiman R. Transhepatic mechanical thrombectomy followed by infusion of TPA into the superior mesenteric artery to treat acute mesenteric vein thrombosis. J Vasc Interv Radiol 2000;11:195-8.
11. Hechelhammer L, Crook DW, Widmer U, Wildermuth S, Pfammatter T. Thrombosis of a superior mesenteric vein aneurysm; transarterial thrombolysis and transhepatic aspiration thrombectomy. Cardiovasc Intervent Radiol 2004;27:551-5.
12. Chawla YK, Bodh V. Portal vein thrombosis. J Clin Exp Hepatol 2015;5:22-40.
13. Midia M, Razavi M. Splanchnic venous thrombosis: Challenges and opportunities. Endovasc Today 2014;July:56-60.
14. Takahashi N, Kuroki K, Yanaga K. Percutaneous transhepatic mechanical thrombectomy for acute mesenteric venous thrombosis. J Endovasc Ther 2005;12:508-11.
15. Saad WE, Madoff DC. Percutaneous portal vein access and transhepatic tract hemostasis. Semin Interv Radiol 2012;29:71-80.
16. Habib A, Desai K, Hickey R, Thornburg B, Vouche M, Vogelzang R, *et al*. Portal vein recanalization-transjugular intrahepatic portosystemic shunt using the transsplenic approach to achieve transplant candidacy in patients with chronic portal vein thrombosis. J Vasc Interv Radiol 2015;26:499-506.
17. Zhou W, Choi L, Lin PH, Dardik A, Eraso A, Lumsden AB. Percutaneous transhepatic thrombectomy and pharmacologic thrombolysis of mesenteric venous thrombosis. Vascular 2007;15:41-5.
18. Fontaine AB, Verschyl A, Hoffer E, Borsa J, Dowd M. Use of CT-guided marking of the portal vein in creation of 150 transjugular intrahepatic portosystemic shunts. J Vasc Interv Radiol 1997;8:1073-7.
19. Ferro C, Rossi UG, Bovio G, Dahamane M, Centanaro M. Transjugular intrahepatic portosystemic shunt, mechanical aspiration thrombectomy, and direct thrombolysis in the treatment of acute portal and superior mesenteric vein thrombosis. Cardiovasc Intervent Radiol 2007;30:1070-4.
20. Haskal ZJ, Edmond J, Brown R. Mesenteric venous thrombosis. N Engl J Med 2002;346:1252-3.
21. Seghal M, Haskal ZJ. Use of transjugular intrahepatic portosystemic shunts during lytic therapy of extensive portal splenic and mesenteric venous thrombosis: Long-term follow-up. J Vasc Interv Radiol 2000;11:61-5.
22. Lopera JE, Correa G, Brazzini A, Ustunsoz B, Patel S, Janchai A, *et al*. Percutaneous transhepatic treatment of symptomatic mesenteric venous thrombosis. J Vasc Surg 2002;36:1058-61.
23. Stambo GW, Grauer L. Transhepatic portal venous power-pulse spray rheolytic thrombectomy for acute portal vein thrombosis after CT-guided pancreas biopsy. AJR Am J Roentgenol 2005;184(3 Suppl):S118-9.