Article published online: 2021-07-26

Hernia uteri inguinalis in ovotesticular disorder of sexual differentiation: A rare complication and role of imaging

Janardhana Ponnatapura

Department of Radiodiagnosis, Kempegowda Institute of Medical Sciences, Bengaluru, Karnataka, India

Correspondence: Dr. Janardhana Ponnatapura, 301/1-1, 23 Cross, 6 Block, Jayanagar, Bengaluru - 560 070, Karnataka, India.
E-mail: psjanardhan@yahoo.com

Abstract

Neonate with ambiguous genitalia can cause great apprehension for the family as well as for healthcare providers. We report a rare complication of delayed diagnosis of hernia uteri inguinalis in ovotesticular disorder of sexual differentiation (DSD) in 20-year-old male patient who presented with pain and swelling in left inguinal region since 1 month. He had a past surgical history of repair of hypospadias 10 years back. On imaging, the left inguinal hernia sac contained nonfunctioning uterus and one ovary in the left scrotal sac and one testis in the right scrotal sac. Further investigation confirmed genotypically female (46XX) with negative sex determining region-Y gene on fluorescence *in situ* hybridization. The patient was given psychiatric counseling and wished to remain as male. The left inguinal hernia was repaired with excision of nonfunctioning uterus, ovary, and fallopian tube. Hernia uteri inguinalis is rare complication seen in DSD with only three cases being reported worldwide thus far, including our case.

Key words: Hernia uteri inguinalis; magnetic resonance imaging; ovotesticular disorder of sexual differentiation; true hermaphrodite

Introduction

Neonate with ambiguous genitalia can cause great apprehension for the family as well as for healthcare providers. Timely and appropriate gender assignment is necessary for healthy physical and psychologic development of these children. Work-up is best accomplished with a coordinated medical team that includes a pediatric endocrinologist, geneticist, urologist, and radiologist to ensure timely diagnosis and proper management. Imaging plays an important role in accurately demonstrating the anatomy and possible effects on other organs.[1]

Disorder of sexual differentiation (DSD) is defined as a condition in which chromosomal sex is inconsistent with phenotypic sex, or in which the phenotype is not classifiable as either male or female, and the estimated prevalence is about 0.018% (i.e., one in 5555 persons).[2,3]

Hernia uterine inguinale is a rare condition and an even more uncommon cause of loin pain, instead presenting as an asymptomatic palpable groin mass early in life. This has been rarely reported in the literature associated with true hermaphrodite or ovotesticular disorder of sexual differentiation (OT-DSD) with only three cases being reported worldwide thus far, including our case. It is most often seen in a phenotypically normal male infant having both testes and uterine tissue present. Abdominal and pelvic imaging is useful in the diagnosis of this condition because

Access this article online	
Quick Response Code:	Website: www.ijri.org
	DOI: 10.4103/ijri.IJRI_178_17

This is an open access journal, and articles are distributed under the terms of the Creative Commons Attribution-NonCommercial-ShareAlike 4.0 License, which allows others to remix, tweak, and build upon the work non-commercially, as long as appropriate credit is given and the new creations are licensed under the identical terms.

For reprints contact: reprints@medknow.com

Cite this article as: Ponnatapura J. Hernia uteri inguinalis in ovotesticular disorder of sexual differentiation: A rare complication and role of imaging. Indian J Radiol Imaging 2018;28:41-4.

it may aid in identifying patients with coexisting Müllerian malformations.

Case History

A 20-year-old phenotypic male presented with left inguinal swelling and pain since 1 month. He had a past surgical history of repair of hypospadias 10 years back. On examination, sparse facial hair was noted. Axillary and pubic hair (Tanner stage 4) was noted. Phallus length was 3.5 cm [Figure 1B]. Bilateral gynecomastia [Figure 1A] with left indirect inguinal hernia was noted. Left testis was not identified.

Abdomen and inguino-scrotal ultrasound revealed solitary small testis in the right scrotal sac with an approximate volume of 3 cm^3 [Figure 2A], solitary normal-sized ovary in the left scrotal sac with an approximate volume of 6 cm^3 [Figure 2B], and left indirect inguinal hernia with suspicious uterus and fallopian tube in the hernia sac [Figure 2C].

On biochemical examination, testosterone (156 ng/dl) and dehydroepiandrosterone sulfate (79 µg/dl) levels were below normal range; however, follicle stimulating hormone, luteinizing hormone, progesterone, prolactin, and thyroid hormones were within normal range.

Karyotyping showed 46XX [Figure 3] and fluorescence *in situ* hybridization was negative for sex determining region-Y (SRY) gene [Figure 4]. Patient was subjected to magnetic resonance imaging (MRI) pelvis, which demonstrated solitary testis in the right scrotal sac [Figure 5A] with inguinal hernia on the left side with herniation of ovary and nonfunctioning uterus [Figure 5B]. Prostate could not be definitely identified. Contralateral testis and ovary were not identified.

On operation, the left inguinal sac contained small uterus, ovary, and fallopian tube, which was excised. The histopathology confirmed the same [Figure 6A-C]. Psychiatric counseling was done and decided to raise the patient as a male. Testis was retained.

Discussion

OT-DSD is a congenital anomaly characterized by the presence of both ovary and testis tissues. Genotypic sex is determined by chromosomes. For phenotypic sex development, these chromosomes activate some pathways and hormones. In the presence of SRY gene, differentiation into male phenotype begins. Absence or inactivation of SRY gene causes the development of the female phenotype.[4] Fetus has both Müllerian and Wolffian ducts until the sixth week of gestation. In early gestational period (<7 weeks), embryological developmental defect influences both Wolffian and Müllerian ducts.[5] Testicular testosterone production promotes the growth of Wolffian duct. Anti-Müllerian hormone (AMH) is secreted by sertoli cells. AMH is responsible for regression of Müllerian duct between 8 and 10 weeks of gestation. Any abnormality during gonadal development and differentiation of male or female phenotype can result in DSD. Either of the Müllerian

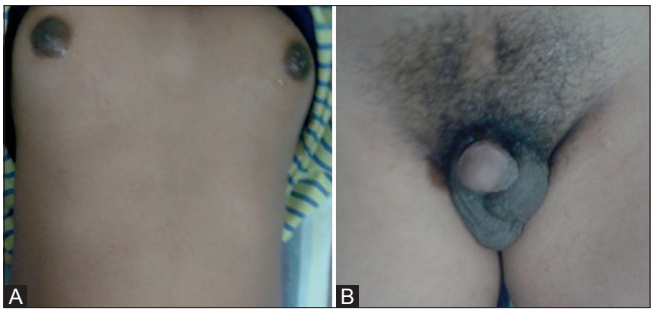

Figure 1 (A and B): (A) Phenotypic male patient with bilateral gynecomastia. (B) Small phallus with scrotum

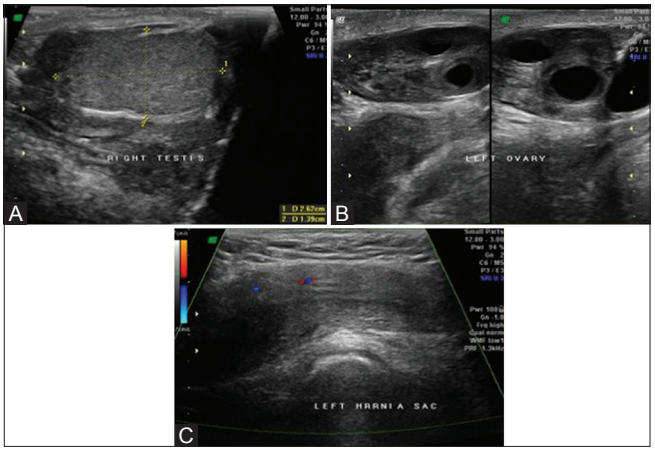

Figure 2 (A-C): (A) Grey scale ultrasound image shows small testis in the right scrotal sac. (B) Grey scale ultrasound image shows normal sized ovary with follicles in the left scrotal sac. (C) Grey scale ultrasound image shows left inguinal hernia sac with non-functioning uterus within it

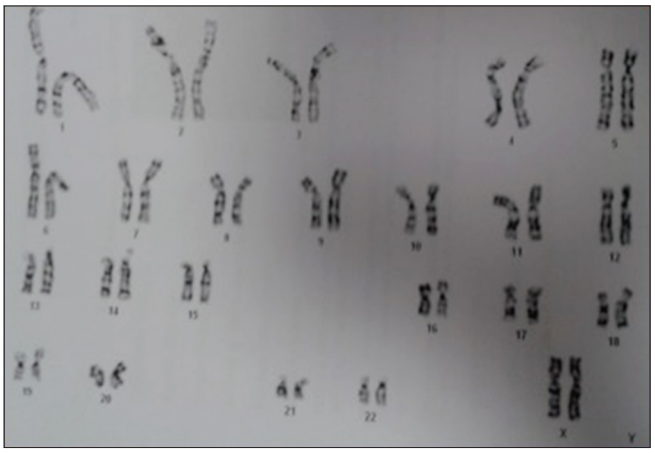

Figure 3: Double X chromosomes with absent Y chromosome suggestive of genotypic female)

duct remnants, such as the uterus, fallopian tube, and cervix, is also seen in patients with OT-DSD.[5]

In 2006, a task force sponsored by the European Society for Pediatric Endocrinology and the Lawson Wilkins Pediatric Endocrine Society proposed a new nomenclature and classification system as well as new management recommendations for DSD.[6] These disorders were further subdivided into 46XY DSD (disorders of gonadal or testicular development and impaired androgen synthesis or action), 46XX DSD (disorders of gonadal or ovarian development and androgen excess), and chromosomal DSD (numeric sex chromosome anomalies). There is some overlap between these three subgroups.

This new terminology has replaced the older terms hermaphroditism and pseudohermaphroditism and emphasizes the genetic origin of the disorders.[3] In the presence of the penis, hypospadias is commonly seen. If testis is present, it is usually undescended. Due to undescended testes, infertility is a common problem but ovulation or spermatogenesis can occur. In delayed diagnosis of OT-DSD, there is also a high risk of malignancy in the ectopic gonads.[7,8] Therefore, surgery is necessary in the treatment of OT-DSD. Ocal G has prepared a diagnostic algorithm of 46XX DSD for new classification[7] [Figure 7].

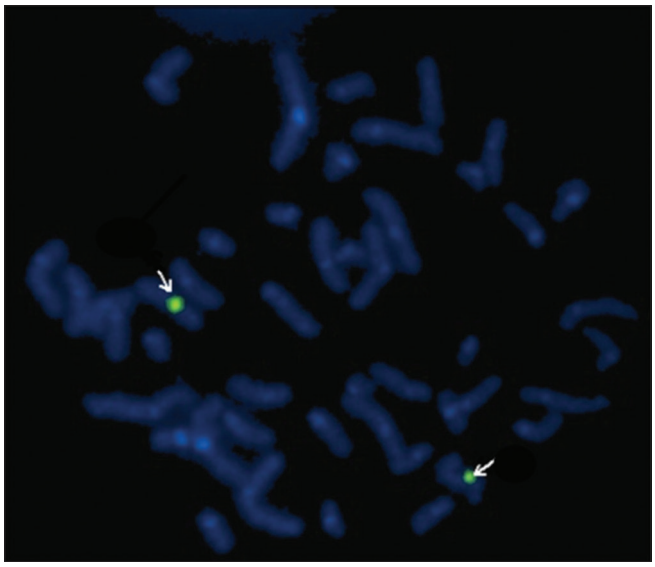

Figure 4: Fish shows two X with absent SRY gene

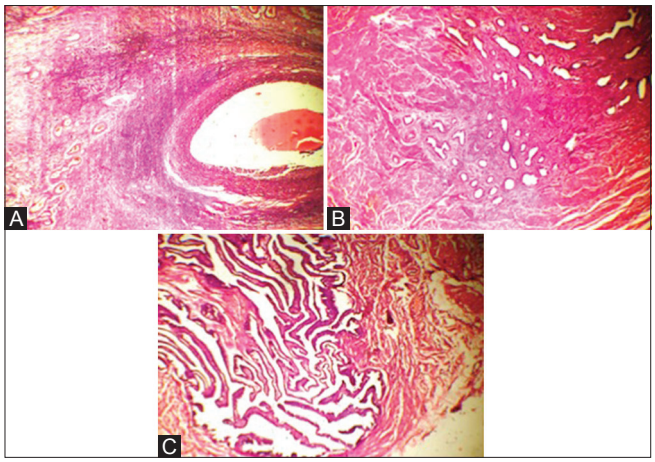

Figure 6 (A-C): (A) HPE shows ovarian follicle. (B) HPE of uterus shows endometrium with adenomyosis. (C) HPE shows fallopian tube

The imaging modalities can be used for preoperative evaluation of anatomy. Ultrasound (US), computed tomography (CT), or MRI can be performed. US is cost-effective, dynamic, noninvasive, and easily available and can differentiate the echotexture of ovaries and testis definitively. It can be used as primary imaging modality, especially with different approaches (transabdominal, endoluminal, and transperineal). Transperineal US can be performed using conventional and high-resolution linear probe positioned directly above the anus, and may capture images of the anal canal, rectum, puborectalis muscle, vagina, uterus, urethra, and urinary bladder. CT has a limited role in evaluation of DSD due to poor soft tissue resolution of pelvis.

MRI helps to characterize the abnormal pelvic anatomy. MRI examination should be reserved for cases in which

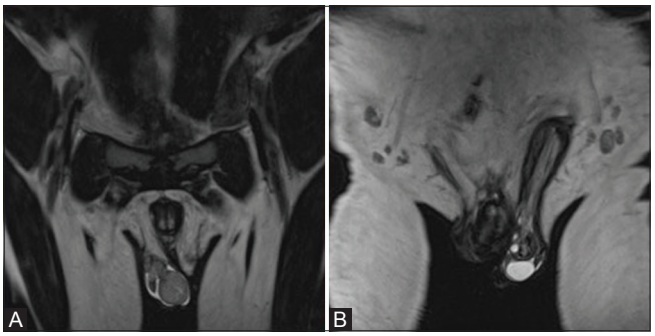

Figure 5 (A and B): (A) Coronal T2 weighted MRI pelvis shows testis in the right scrotal sac. (B) Coronal T2 weighted MRI pelvis shows left inguinal hernia with left ovary and non-functioning uterus

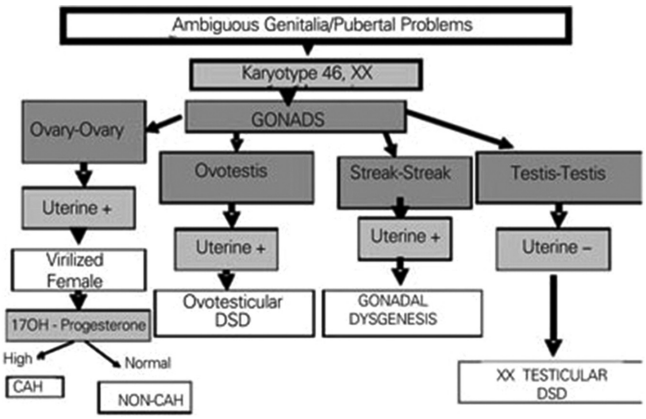

Figure 7: Diagnostic algorithm of 46XX DSD

DSD is suspected but US failed to identify the gonads, or when proper differentiation between clitoral hypertrophy and micropenis is required for proper precorrective surgery assessment.[9] MRI multiplanar investigation with high-contrast resolution provides excellent soft tissue characterization. The other advantage of MRI is lack of radiation exposure.

"Hernia uteri inguinalis" is rarely seen in DSD with only three cases being reported worldwide thus far, including our case. Two other cases are reported by Venkataram *et al*.[10] and Ceylan *et al*.[11] Infants and children born with DSD pose a diagnostic and therapeutic challenge to the clinicians and radiology plays a very important role in management.

Declaration of patient consent

The authors certify that they have obtained all appropriate patient consent forms. In the form the patient(s) has/have given his/her/their consent for his/her/their images and other clinical information to be reported in the journal. The patients understand that their names and initials will not be published and due efforts will be made to conceal their identity, but anonymity cannot be guaranteed.

Financial support and sponsorship

Nil.

Conflicts of interest

There are no conflicts of interest.

References

1. Wright NB, Smith C, Rickwood AM, Carty HM. Imaging children with ambiguous genitalia and intersex states. Clin Radiol 1995;50:823-9.
2. Sax L. How common is intersex? A response to Anne Fausto-Sterling. J Sex Res 2002;39:174-8.
3. Hughes IA, Houk C, Ahmed SF, Lee PA; LWPES Consensus Group; ESPE Consensus Group. Consensus statement on management of intersex disorders. Arch Dis Child 2006;91:554-63.
4. Allen L. Disorders of sexual development. Obstet Gynecol Clin North Am 2009;36:25-45.
5. Josso N, Belville C, di Clemente N, Picard JY. AMH and AMH receptor defects in persistent Mullerian duct syndrome. Hum Reprod Update 2005;11:351-6.
6. Pasterski V, Prentice P, Hughes IA. Impact of the consensus statement and the new DSD classification system. Best Pract Res Clin Endocrinol Metab 2010;24:187-95.
7. Ocal G. Current concepts in disorders of sexual development. J Clin Res Pediatr Endocrinol 2011;3:105-14.
8. Moshiri M, Chapman T, Fechner PY, Dubinsky TJ, Shnorhavorian M, Osman S, *et al*. Evaluation and management of disorders of sex development: Multidisciplinary approach to a complex diagnosis. Radiographics 2012;32:1599-618.
9. Mansour SM, Hamed ST, Adel L, Kamal RM, Ahmed DM. Does MRI add to ultrasound in the assessment of disorders of sex development? Eur J Radiol 2012;81:2403-10.
10. Venkataraman A, Shivaswamy S, Babu R, Santhosh S. Hernia uteri inguinalis in a case of ovotesticular disorder of sexual differentiation. J Pediatr Adolesc Gynecol 2013;26:17-9.
11. Ceylan K, Algun E, Gunes M, Gonulalan H. True hermaphroditism presenting as an inguinal hernia. Int Braz J Urol 2007;33:72-3.