

Precontrast T1 signal measurements of normal pituitary and microadenoma: A retrospective analysis through DCE MRI signal time curves

Ishan Kumar, Tanya Yadav, Ashish Verma, Ram C Shukla, Surya K Singh¹

Departments of Radiodiagnosis and ¹Endocrinology, Institute of Medical Sciences, Banaras Hindu University, Varanasi, Uttar Pradesh, India

Correspondence: Dr. Ashish Verma, Department of Radiodiagnosis, Institute of Medical Sciences, Banaras Hindu University, Varanasi - 221 005, Uttar Pradesh, India. E-mail: drdnv5@gmail.com

Abstract

Background: The dynamic contrast enhanced magnetic resonance imaging (DCE MRI) has currently become the most utilized technique for the detection of pituitary microadenoma. However, owing to differential enhancement of normal pituitary, high rate of false positivity remains a concern in its interpretation. **Purpose:** Our aim was to assess the utility of precontrast T1 signal intensity ratio (SIR) of the lesions suspected on DCE MRI, in prediction of presence of microadenoma. **Materials and Methods:** We retrospectively reviewed MRI of 23 patients referred for DCE MRI of pituitary (group 1, 15 patients with diagnosis of pituitary microadenoma; and group 2, patients not clinically labeled as microadenoma). STC were plotted and T1-SIR at $t = 0$ s was obtained at the suspicious zone of differential enhancement (SIR T) and normal pituitary (SIR P). SIR difference (SIR P – SIR T) and relative SIR difference (SIR P – SIR T/SIR P) were calculated for each patient and was compared between the two groups. **Results:** Mean T1 SIR is lower in patients with microadenoma than those without ($P = 0.065$). SIR difference and relative SIR difference was higher in patients with microadenoma ($P = 0.003$ and 0.005 , respectively). Receiver-operated characteristic curve analysis demonstrated that a cut-off of 26 and 0.107 for SIR difference and relative SIR difference, respectively, could diagnose microadenoma with 100% specificity and reasonable sensitivities. **Conclusion:** The baseline precontrast T1 SIR evaluation of the lesion suspected to be microadenoma on DCE MRI, derived through STC curve, can increase diagnostic confidence in diagnosis of microadenoma.

Key words: Dynamic contrast magnetic resonance imaging; pituitary microadenoma; signal time curve

Introduction

Pituitary adenomas are diverse group of tumors arising from the pituitary gland that are estimated to be present in 14.4%–22.5% of the general population.^[1] They have been traditionally classified, based on size into macroadenoma (size > 1 cm) and microadenoma (size < 1 cm).

Magnetic resonance imaging (MRI) remains the mainstay of pituitary imaging and has largely supplanted computed tomography (CT) for detection and localization of microadenomas. Spin echo (SE) MR sequences were the first to be utilized in detection of pituitary adenoma; however,

This is an open access journal, and articles are distributed under the terms of the Creative Commons Attribution-NonCommercial-ShareAlike 4.0 License, which allows others to remix, tweak, and build upon the work non-commercially, as long as appropriate credit is given and the new creations are licensed under the identical terms.

For reprints contact: reprints@medknow.com

Cite this article as: Kumar I, Yadav T, Verma A, Shukla RC, Singh SK. Precontrast T1 signal measurements of normal pituitary and microadenoma: A retrospective analysis through DCE MRI signal time curves. Indian J Radiol Imaging 2018;28:380-4.

Access this article online

Quick Response Code:



Website:
www.ijri.org

DOI:
10.4103/ijri.IJRI_104_18

the sensitivity of these sequences remained low, especially in cases of microadenoma.^[2,3] Subsequent studies showed that microadenoma detection improved on contrast studies and was dependent on time of acquisition after contrast administration. To augment the contrast difference between normal gland and microadenoma, early dynamic scan was proposed.^[4-6] Dynamic pituitary MRI during contrast scanning has resulted in increased diagnostic yield for these lesions and has presently become the criterion standard. A significant problem with dynamic MRI is the increased false positivity.^[2,3,7,8] At present, none of the MRI sequence is found to be unequivocally optimal for their detection, and thus, diagnosis depends on combination of images obtained before, during and after the contrast injection.^[9]

This study was intended to combine the merits of precontrast T1 SE sequence and dynamic contrast enhanced magnetic resonance imaging of the pituitary gland in evaluation of microadenoma, through the signal time curve (STC) analysis. More specifically, we aimed to assess whether the evaluation of precontrast T1 signal intensity ratio (SIR) of the suspicious lesion observed on DCE MRI can improve the diagnostic performance for localizing microadenoma.

Materials and Methods

Patients

This study was approved by institutional review board (IRB) and an informed consent was obtained from each patient enrolled in the study. We retrospectively reviewed MRI images of consecutive 23 patients referred for dynamic postcontrast MRI of pituitary gland. For our study, these patients were divided into two groups.

Group 1 ($n = 15$; male/female ratio, 4:11; mean age, 36 years) consisted of 15 patients who were labeled as pituitary microadenoma in clinical records based on compelling clinical and biochemical evidence compatible with adenomas. In all these patients, MRI had reported a focus of differential enhancement sized 3–10 mm in the pituitary gland on dynamic contrast study suggestive of microadenoma. Of these, 11 were labeled as prolactinomas, who had galactorrhea, infertility, or amenorrhea with serum prolactin >50 ng/mL. Four of these patients presented with acromegaly with growth hormone level exceeding 20 ng/mL.

Group 2 ($n = 8$; male/female ratio, 1:7; mean age, 34 years) consisted of eight patients who were not labeled as microadenomas based on hormonal evaluation and MRI study. Seven of these patients had presented with the complaints of galactorrhea, amenorrhea, or infertility; however, the serum prolactin levels remained <26 ng/mL. One male patient was being evaluated for bulky pituitary reported from an outside institute and was subsequently diagnosed as hypothyroidism.

MRI in six of these patients was reported as normal study. In two of these patients, MRI had reported a focus of differential enhancement on dynamic contrast study suspicious for adenoma.

MR protocol

MRI was done in all patients on a 1.5 Tesla (Siemens Avanto, Erlangen, Germany) system with an actively shielded whole body superconducting magnet. Imaging was done using a 20-channel head-neck coil. A coronal precontrast VIBE sequence was obtained with TR/TE of 497/10 ms, 320×320 matrix, 230 mm Field-of-view (FOV), and 2.5 mm slice thickness without gap for assessment of pituitary and brain morphology. After precontrast sequence, coronal dynamic contrast scan was done using fast SE sequence, 15 mm FOV, 3 mm slice thickness, 0.2 mm slice gap. Contrast was injected when first dynamic ended and second began. Total duration of the dynamic sequence was 225 s which included 1 dynamic of precontrast study and six cycles during and after contrast injection. 10 mL of 0.01-mmol/kg gadopentetate dimeglumine (Magnevist; Bayer HealthCare Pharmaceuticals, Wayne, NJ) was injected at a rate of 2 mL/s.

MRI analysis

For the group 1 patients, the final MRI report of our institute was referenced for obtaining the tumor location. The first author confirmed the presence of the lesion by analyzing the MR images. For group 2 patients, a senior radiologist with 15 years of experience was required by forced choice to outline a focus of decreased signal in the dynamic contrast images and to specify whether an adenoma could be present in the images. The radiologist was blinded to the MRI report but was not blinded to the final clinical diagnosis. Of these eight patients, he indicated the presence of suspicious foci of differential enhancement in two of the patient, which was present in two or more of the sequential postcontrast enhancement. In other six patients, an area of differential enhancement (lowest signal) was outlined for analysis, which was present in single image.

Region of interest (ROI) was drawn on the focus of differential enhancement (zone a) in all the patients of group 1 and group 2. Another ROI was drawn on all the patients in normal appearing tissue of pituitary gland (zone b). Signal intensity time curves were generated in all the patients at both these locations as per the standard institutional protocol.

Three parameters were recorded for each patient:

1. Baseline T1 SIR at 0 s at suspicious zone (zone a) of differential enhancement (SIR T) and at normal pituitary (zone b) (SIR P)
2. SIR difference: $SIR P - SIR T$
3. Relative SIR difference: The ratio of the SIR difference divided by the SIR of normal pituitary = $(SIR P - SIR T) / SIR P$.

The negative values, if any, for SIR difference and relative SIR difference was ignored for calculation of mean.

Statistical analysis

Statistics was performed using SPSS software (IBM Corp 2013. Version 22.0. Armonk, NY). The first part was using the independent sample Mann–Whitney *U*-test to compare mean of all these three parameters between group 1 and group 2. Second part was drawing receiver-operated characteristic (ROC) curve for these three parameters to predict the presence of microadenoma.

Results

Evaluation of STC from ROI placed over the normally enhancing anterior pituitary and suspicious area of differential enhancement in group 1 [Figure 1] and group 2 patients [Figure 2] revealed that 14 out of 15 cases of group 1 (with microadenoma) demonstrated lower baseline T1 signal intensity compared with the normal anterior pituitary. While one patient, who was on bromocriptine therapy for prolactinoma, showed mildly higher T1 signal than normal pituitary. In group 2, in six of eight patients, the area under consideration showed lower T1 signal, whereas two showed higher T1 signal than the normal pituitary.

The mean values, standard deviation, and results of Independent-sample Mann–Whitney *U*-test to compare the mean values between the two groups for the three parameters are summarized in Table 1. The mean baseline T1 SIR was lower in patients with the diagnosis of microadenoma (group 1), although the difference was not significant ($P = 0.065$). The difference of baseline T1 SIR between the normal pituitary and the zone of concern (SIR difference) was significantly higher in group 1 ($P = 0.003$). The relative SIR difference was also significantly higher in cases compared with controls ($P = 0.005$).

ROC curve drawn to predict the presence of microadenoma demonstrates high area under curve for all the three parameters [Figures 3 and 4]. Table 2 summarizes the results

of ROC curve analysis for the three parameters. Of these, the SIR difference showed highest area under curve closely followed by the Relative SIR difference.

Based on ROC curves, we found that a value of 312 for baseline T1 signal predicts microadenoma with moderate sensitivity and specificity. A SIR difference of 21 and relative SIR of 0.057 between the normal pituitary and the area showing differential enhancement predicted microadenoma with high sensitivity and specificity. More importantly, we could obtain a specificity of 100%, for cut-off values of 26 and 0.107 of SIR difference and the relative difference, respectively, with reasonable sensitivities.

Discussion

DCE MRI has currently become the most utilized technique for the detection of pituitary microadenoma. Most of the previous studies evaluating DCE MRI in detection of microadenoma have relied on subjective visual assessment in delineating these tumors. An area of low signal in anterior pituitary on dynamic post contrast images measuring 3–10 mm is diagnosed as microadenoma. The problem with this technique is increased rate of false positivity.^[2,3] Pituitary often shows heterogeneous contrast enhancement owing to variable blood supply. An area of lower contrast enhancement on a single image can be misinterpreted as an adenoma. Moreover, the accuracy of the diagnosis is dependent upon the experience of the interpreting radiologist and there are no objective criteria for the diagnosis.

Table 1: Mean, standard deviation, and comparison of the mean values of three parameters between two groups using Independent-sample Mann-Whitney U-test

Parameters	Group 1 (n=15)		Group 2 (n=8)		P
	Mean	SD	Mean	SD	
Baseline T1 SIR value	285.13	48.6	331.13	50.79	0.065
SIR difference	95.07	111.84	12.25	8.97	0.003
Relative SIR difference ratio	0.215	0.205	0.037	0.028	0.005

SIR=Signal intensity ratio

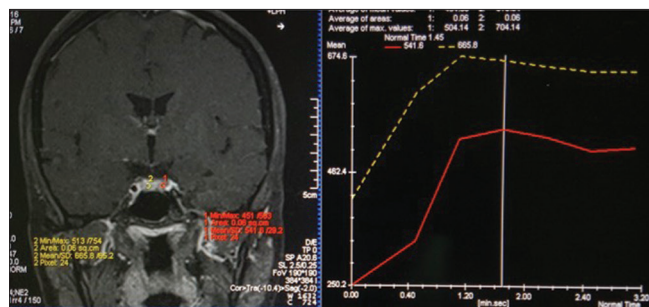


Figure 1: Demonstrates placement of ROI within the normal appearing anterior pituitary gland (yellow) and microadenoma (red). Corresponding signal-time curve shows that there is significant difference enhancement between the microadenoma and normal pituitary and difference in precontrast signal at $t = 0$ s

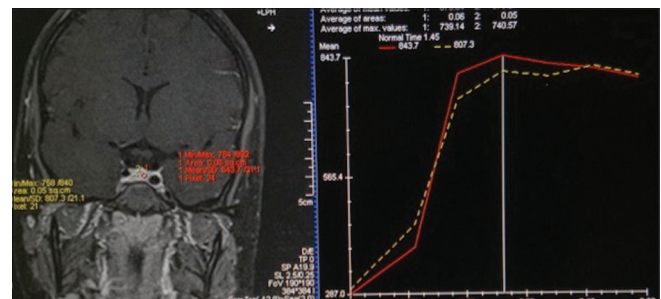


Figure 2: Dynamic MRI of a 24-year-old female patient in group 2, presenting with galactorrhea. ROI placed in normally enhancing anterior pituitary (red) and an area of differential decreased signal (yellow) is shown and the corresponding signal–time curves show that the suspicious area shows almost similar (and slightly higher) baseline T1 signal at $t = 0$ s

Table 2: Receiver-operated characteristic curve drawn to predict the presence of micro adenoma for baseline T1 SIR values, its difference from normal pituitary SIR, ratio (difference/SIR of normal pituitary)

Test parameter	Area under curve	Cut off value	Sensitivity (%)	Specificity (%)	Cut-off with 100% specificity	Sensitivity of cut off with 100% specificity (%)
Baseline T1 SIR value	0.738	312	66.7	62.5	-	-
SIR difference	0.863	21	73.3	75	26.5	66.7
Relative SIR difference ratio	0.850	0.057	80	75	0.107	60

SIR=Signal intensity ratio

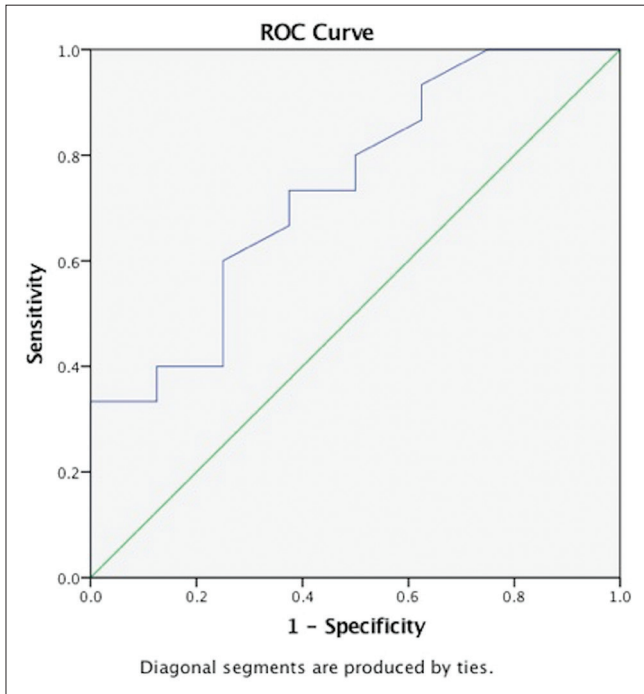


Figure 3: Receiver-operated characteristic curve of the baseline T1 signal if the suspicious lesions in prediction of presence of microadenoma

Few studies have attempted to evaluate STCs on DCE MRI to assess time course of enhancement of tumors and the normal pituitary, enabling an increased diagnostic confidence. One such study was conducted by Yuh *et al.*, who concluded that pituitary adenoma enhanced 9.3 ± 1.5 s after straight-sinus enhancement and significantly (12.0 s) before anterior pituitary enhancement.^[10] Rossi Espagnet *et al.*, were first to study STCs of the pituitary in 52 patients to establish optimum acquisition time for microadenoma detection and concluded that 120 s is ideal time for imaging.^[11] They also found out that there was significant difference in peak enhancement of microadenoma and normal anterior pituitary. Moreover, pituitary microadenoma showed mean time-to-peak of 90 s, whereas normal anterior pituitary showed an earlier peak enhancement with mean time-to-peak of 80 s.

Stadnik *et al.* compared DCE MRI and precontrast T1 images in 12 patients with microadenoma and found that both T1 sequence and DCE MRI was able to detect 84% (10/12) lesions, whereas the combination of both dynamic MRI

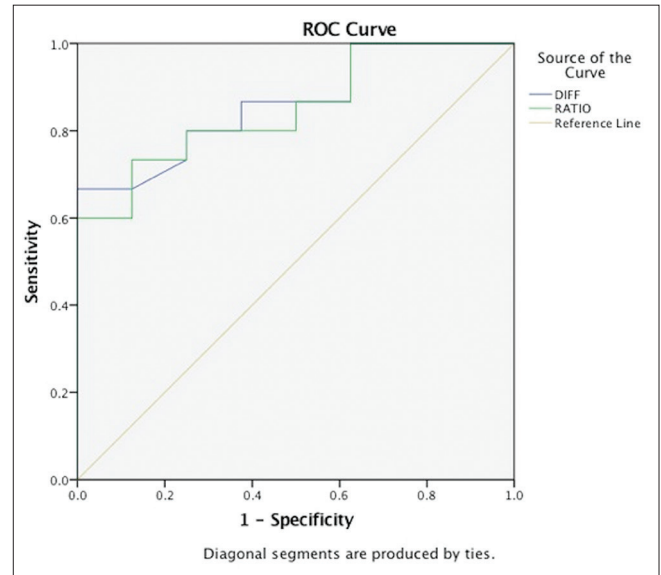


Figure 4: Receiver-operated characteristic curve of the signal intensity ratio (SIR) difference (blue) and relative SIR difference ratio (green) in prediction of presence of microadenoma

and precontrast T1 sequence was able to detect 100% of cases.^[12] Ma *et al.* in his study observed that a significant correlation between tumor consistency and expression of collagen IV was seen with signal intensity on precontrast T1 SE sequences.^[13]

In our study, 14 out of 15 cases of microadenoma revealed lower signal intensity compared with the normal anterior pituitary. While in one patient, who was on bromocriptine therapy for prolactinoma, showed mildly higher T1 signal than normal pituitary. This result was in concordance with the previous studies that showed that most of the microadenoma demonstrates increased T1 and T2 relaxation times. One of the initial studies has reported atypical T1 and T2 relaxation signals in patients with bromocriptine and attributed this to loss of cell volume owing to medical therapy.^[14]

Our study demonstrated that difference of T1 SIR of the normal pituitary and the lesion under consideration is significantly high in patients with pituitary microadenoma than those without. The SIR difference and the relative SIR difference were able to predict the presence of microadenoma with 100% specificity with reasonable sensitivities. A difference of T1-SIR of 26.5 between

the lesion and the normal pituitary and a relative SIR difference ratio of 0.028 were able to predict the presence of microadenoma in all the cases. The findings of the present study have great implication while interpretation of DCE MRI and we speculate that addition of these parameters can reduce false positivity rate that has been one of the major criticisms of DCE MRI.

Our study utilizes the combined merits of dynamic contrast properties as well as internal relaxation properties of microadenomas for their diagnosis. Moreover, this study provides quantitative parameters that can be reliably used to increase the diagnostic confidence of DCE MRI in diagnosing pituitary microadenoma.

Small sample size and lack of surgical and histopathological evidence were the major limitations of this study. Moreover, owing to its retrospective nature, we could not perform T1 mapping of pituitary, which could further validate our concept. Also, presence of nonfunctioning adenomas in the control group could not be excluded as the clinical diagnosis was considered gold standard in the present study and surgical evidence was lacking. Last, interpreting radiologist in our study was not blinded to the clinical picture that can lead to patient selection bias. We recommend future multicentric prospective studies having larger sample sizes with an effort to reduce selection bias and histopathological confirmation to validate the results of our study.

Conclusion

In conclusion, our study demonstrated that assessment of baseline precontrast SIR derived through STC of the pituitary microadenoma, suspected on dynamic contrast MRI, can increase diagnostic confidence in their diagnosis and localization. Moreover, we have shown that the quantitative assessment would be more meaningful if interpreted with the SIR of an internal reference, i.e., normal appearing pituitary gland.

Acknowledgements

The authors would also like to acknowledge their team of MR technicians led by Mrs Raichel Luyees and Dr B N Maurya for their role in this study.

Declaration of patient consent

The authors certify that they have obtained all appropriate patient consent forms. In the form the patient(s) has/have given his/her/their consent for his/her/their images and other clinical information to be reported in the journal. The patients understand that their names and initials will not

be published and due efforts will be made to conceal their identity, but anonymity cannot be guaranteed.

Financial support and sponsorship

Nil.

Conflicts of interest

There are no conflicts of interest.

References

- Ezzat S, Asa SL, Couldwell WT, Barr CE, Dodge WE, Vance ML, *et al.* The prevalence of pituitary adenomas: A systematic review. *Cancer* 2004;101:613-9.
- Chaudhry IN, Sinaii N, Oldfield EH, Patronas N, Nieman LK. A change in pituitary magnetic resonance imaging protocol detects ACTH-secreting tumours in patient with previously negative results. *Clin Endocrinol (Oxf)* 2010;72:502-6.
- Kasaliwal R, Sankhe SS, Lila AR. Volume interpolated 3D-spoiled gradient echo sequence is better than dynamic contrast spin echo sequence for MRI detection of corticotropin secreting pituitary microadenomas. *Clin Endocrinol* 2013;78:825-30.
- Hemminghytt S, Kalkhoff RK, Daniels DL, Williams AL, Grogan JP, Haughton VM. Computed tomographic study of hormone-secreting microadenomas. *Radiology* 1983;46:65-9.
- Miki Y, Michimasa M, Nishizawa S, Kuroda Y, Keyaki A, Makita Y, *et al.* Pituitary adenomas and normal pituitary tissue: Enhancement patterns on gadopentetate-enhanced MR imaging. *Radiology* 1990;177:35-8.
- Bartynski WS, Lin L. Dynamic and conventional spin-echo MR of pituitary microlesions. *Am J Neuroradiol* 1997;18:965-72.
- Tabarin A, Laurent F, Catargi B, Olivier-Puel F, Lescene R, Berge J, *et al.* Comparative evaluation of conventional and dynamic magnetic resonance imaging of the pituitary gland for the diagnosis of Cushing's disease. *Clin Endocrinol* 1998;49:293-300.
- Doppman JL, Frank JA, Dwyer AJ, Oldfield EH, Miller DL, Nieman LK, *et al.* Gadolinium DTPA enhanced MR imaging of ACTH-secreting microadenomas of the pituitary gland. *J Comput Assist Tomogr* 1988;12:728-35.
- Kucharczyk W, Davis DO, Kelly WM, Sze G, Norman D, Newton TH, *et al.* Pituitary adenomas: High-resolution MR imaging at 1.5 T. *Radiology* 1986;161:761-5.
- Yuh WT, Fisher DJ, Nguyen HD, Tali ET, Gao F, Simonson TM, *et al.* Sequential MR enhancement pattern in normal pituitary gland and in pituitary adenoma. *Am J Neuroradiol* 1994;15:101-8.
- Rossi Espagnet MC, Bangiyev L, Haber M, Block KT, Babb J, Ruggiero V, *et al.* High-resolution DCE-MRI of the pituitary gland using radial k-Space acquisition with compressed sensing reconstruction. *Am J Neuroradiol* 2015;36:1444-9.
- Stadnik T, Stevenaert A, Beckers A, Luypaert R, Buisseret T, Osteaux M. Pituitary microadenomas: Diagnosis with two- and three-dimensional MR imaging at 1.5 T before and after injection of gadolinium. *Radiology* 1990;176:419-28.
- Ma Z, He W, Zhao Y, Yuan J, Zhang Q, Wu Y, *et al.* Predictive value of PWI for blood supply and T1-spin echo MRI for consistency of pituitary adenoma. *Neuroradiology* 2016;58:51-7.
- Pojunas KW, Daniels DL, Williams A, Haughton VM. MR imaging of prolactin-secreting microadenomas. *Am J Neuroradiol* 1986;7:209-13.