

Original Article

Can drains be avoided in lipo-abdominoplasty?

Medha Anand Bhave (Khair)

Department of Plastic and Cosmetic Surgery, Param Hospital and ICU, Thane, Maharashtra, India

Address for correspondence: Dr. Medha Anand Bhave (Khair), Row House 6, Gautam Parag Society, Green Road, Louisewadi, Thane - 400 604, Maharashtra, India. E-mail: bhavemedha@yahoo.co.in

ABSTRACT

Context: Seroma formation is a common complication after lipoabdominoplasty. Conventionally, drains have been placed to prevent seroma; however, there are problems with drains, namely, pain, compromised mobilisation, breakage, tissue irritation and infection. Strategies to prevent seroma, such as the use of glue or quilting sutures have all been attempted with variable and unpredictable benefit. **Aims:** The author extrapolated the experience with own liposuction protocols to lipoabdominoplasty and began doing away with drains from the year 2006 onwards unless absolutely indicated. Incidence of complications is evaluated here. **Settings and Design:** This retrospective study is the report of our experience with 204 lipoabdominoplasties performed since 2006 upto December 2016. **Subjects and Methods:** Consecutive abdominoplasty patients were evaluated for seroma formation, wound dehiscence till suture removal. Nuances of operative details that helped avoid drains were contemplated. **Results:** Only one patient who had drainless abdominoplasty had seroma formation and wound dehiscence. **Conclusions:** We found that (a) 'toilet liposuction', (a term the author would like to introduce) (b) multilayer wound closure without tension, (c) avoidance of gliding surfaces d) continuous use of pressure garment for 4 days post-operative and (e) reducing the amount of infiltration are the key factors in avoidance of collections and thus seroma formation. If such a technique is diligently followed, desired results are obtained; yet there is no need to insert drains in most patients. Reducing the need of drains permits early ambulation and better patient comfort without seroma and other complications.

KEY WORDS

Drainless abdominoplasty; seroma; toilet liposuction, no drains abdominoplasty.

INTRODUCTION

It is routine practice to use drains in lipoabdominoplasty operations. It can be safely assumed that only closed; suction drains are being used. Open drains are obsolete

due to inconvenience, soakage, soiling of surrounding skin and inability to calculate exact amount of effluent. Closed drains are less messy and facilitate measurement of the drainage fluid. Active drains are preferred over passive.

Access this article online	
Quick Response Code: 	Website: www.ijps.org
	DOI: 10.4103/ijps.IJPS_23_18

This is an open access journal, and articles are distributed under the terms of the Creative Commons Attribution-NonCommercial-ShareAlike 4.0 License, which allows others to remix, tweak, and build upon the work non-commercially, as long as appropriate credit is given and the new creations are licensed under the identical terms.

For reprints contact: reprints@medknow.com

How to cite this article: Bhava MA. Can drains be avoided in lipo-abdominoplasty? Indian J Plast Surg 2018;51:15-23.

The function of negative suction drain is purported to be evacuation of accumulated fluids - blood, serum and pus if any. Suction is expected to improve approximation of raw areas by better apposition of the surfaces. However, problematic issues with drains are ineffectiveness, discomfort, difficulty in mobilisation, breakage or premature extrusion, bacterial colonisation and increased the duration of hospitalisation.^[1]

Our earlier experience with liposuction patients showed that seromas could be avoided by uninterrupted use of elastic garment for initial 4 days post-operatively. This prompted us to adopt the same protocol for our lipoabdominoplasty patients. Once drains were done away with, we could implement uninterrupted garment support for initial 4 days with early mobilisation after abdominoplasty.

The objective of our retrospective study is to evaluate the results of lipoabdominoplasty, wherein drains were avoided and to define a protocol to avoid seromas after drainless abdominoplasty.

SUBJECTS AND METHODS

Clinical records of 204 consecutive abdominoplasty patients operated in the last 11 years (2006–2017) by a single surgeon were reviewed retrospectively. Parameters observed were (1) method of abdominal closure (2) occurrence of seroma, haematoma, pus collection, skin necrosis and wound discharge or dehiscence till the time of suture removal. (3) Whether drains had to be inserted and time of removal if inserted.

All patients underwent abdominoplasty depending on type of deformity they had, without any compromise on extent of dissection as shown in Figure 1. Infiltration was done with standard Toledo's formula in wet technique proportion, 1:2. Waiting time was a minimum of 10 min. Extensive liposuction was done in all required areas including upper abdomen, flanks, back and trochanters. Thighs and buttocks were treated if indicated. Superficial liposculpture as depicted in Figure 2 was used, especially around bony prominences such as iliac crests, flanks, back and trochanters. The liposuction was done using MicroAire power assisted device, using three, four and five calibre, single or double Mercedes cannulae in all patients done after 2008. Traditional liposuction was done for patients operated between 2006 and 2008

(27 in number). The abdominoplasty flap was raised taking care to leave a layer of loose areolar tissue and fat behind on the rectus sheath as shown in Figure 3. Dissection was done with diathermy and scissors as needed. Perfect haemostasis was achieved using diathermy and ligatures.

'Toilet liposuction' was done by holding the cannulae in the tunnels of liposuction – without to-and-fro movement – and sucking out the fluid from time to time

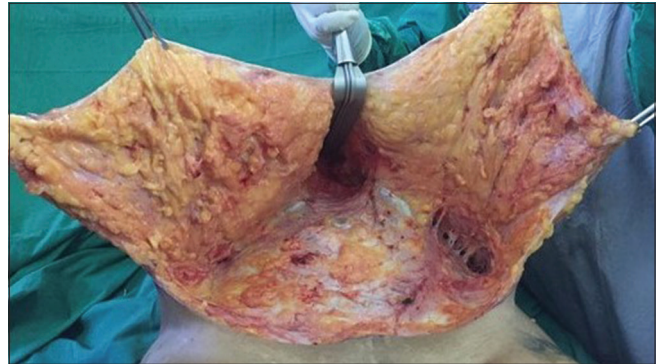


Figure 1: Extent of dissection in typical abdominoplasty. It cannot be compromised in drainless procedure

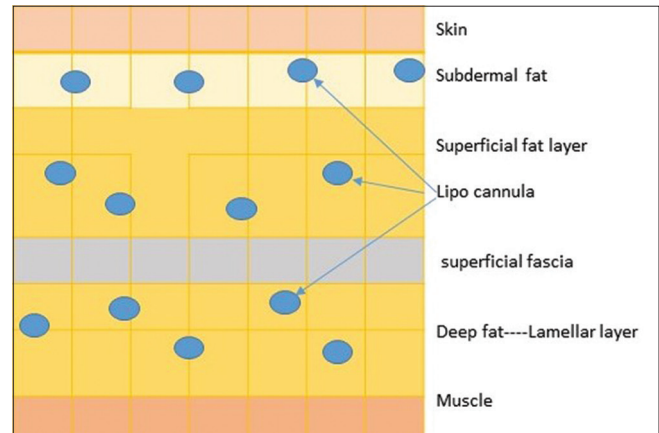


Figure 2: Concept of superficial liposculpture – diagrammatic representation. Subdermal liposuction helps retraction of skin as well as better draping

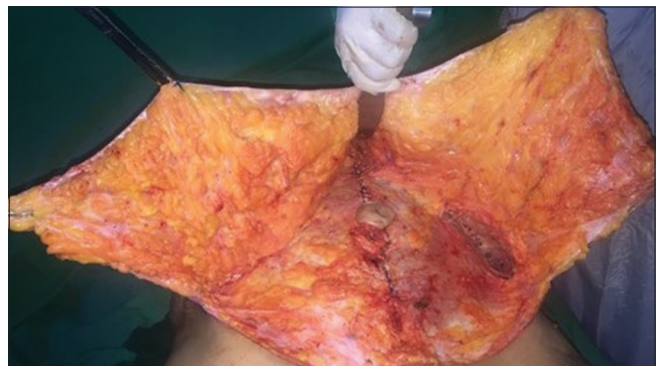

Figure 3: Flap in abdominoplasty with rectus sheath tightening. Note the amount of flap left on the sheath which prevents formation of gliding surfaces leading to seroma formation

throughout the procedure and during closure. Particular care was taken to rest the cannulae in flanks and over trochanters to wring out as much fluid as possible. The deep fat at the lower end of abdominoplasty flap was excised, taking care to preserve superficial layer of the fascia. Closure was done in multiple layers using Vicryl, PDS, Ethilon or staplers as required; rolling out accumulated fluid intermittently. Three patients underwent closure with barbed suture as shown in Figure 4. The deepest layer of closure incorporated the loose areolar layer and the rectus sheath below. Neither Baroudi's sutures/progressive tension sutures nor fibrin glue were used. All liposuction ports were sutured with 6-0 ethilon. The surgical wound was dressed with compressive dressing.

A thick gumjee sheet, secured with elastic tapes, was used as padding. After shifting the patient to the room, a custom-made, pre-stitched one in four stretchable lycra pressure garment was put on, with help of the patient, ensuring a proper fit.

All patients had suturing done in the position of flexion at the hips and the same was maintained for 18 h that is up to next morning. After that, the flexion was slowly released and patients were mobilised by late afternoon. Deep vein thrombosis pump was used during this period to prevent leg vein thrombosis.

The patients were mobilised after 24 h and discharged after 36–48 h after surgery. They were instructed not to remove garment till 96 h after operation. Follow-ups were done at 96 h, 10th post-operative day and 14–18th post-operative day to check for following:

(a) The comfort level, (b) incidence of seroma by palpation, (c) wound dehiscence and (d) discharge.

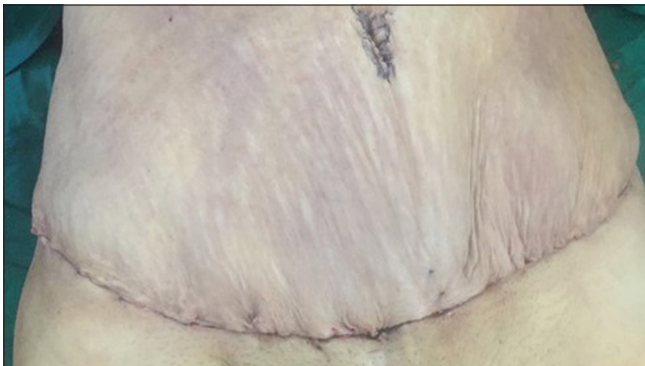


Figure 4: Barbed suture for closure used in three patients. Note absence of drains

The usual time of suture removal was 14–18 days after surgery.

RESULTS

The total number of abdominoplasty patients was 204; females – 203, male – 1. No drains were used in 201 patients (200 females and 1 male).

Drains had to be used only in three female patients, as below:

- Patient underwent Buck's procedure for urinary incontinence. A pelvic drain as well as subcutaneous drain were used
- Patient had total hysterosalpingo-oophorectomy for dysplasia in large ovarian cyst found in frozen section. Pelvic and subcutaneous drains were kept. Subcutaneous drain was removed on 3rd day after effluent dropped to 20 cc. Pelvic drain left *in situ* for 12 days as advised by the oncosurgeon
- Patient had general oozing despite adequate haemostasis. Hence, the decision was taken to keep drain.

Amount of lipoaspirate – 5–22 L.

Number of seromas-two, one each in the DRAIN and NON-DRAIN groups.

Wound dehiscence with serous discharge – one.

Patient A in the drains group developed a seroma despite the drain, and it responded to serial aspiration performed three times. This was the patient who had simultaneous pelvic procedure done for urinary incontinence by gynaecologist.

The other seroma occurred in non-drain group. The seroma was tapped twice and the patient asked to wear garment continuously. She presented with inflamed suprapubic skin and an area of fat necrosis on the 6th day as shown in Figure 5. This was managed with excision of the fat and packing the wound with collagen particles and intrasite gel. The wound healed by 24th day after surgery.

The results of abdominoplasty in certain patients, with respect to age, body mass index (BMI), type of deformity are shown in Figures 6-9. The post-operative contours are satisfactory, indicating that there is no compromise in the extent of dissection and liposuction.

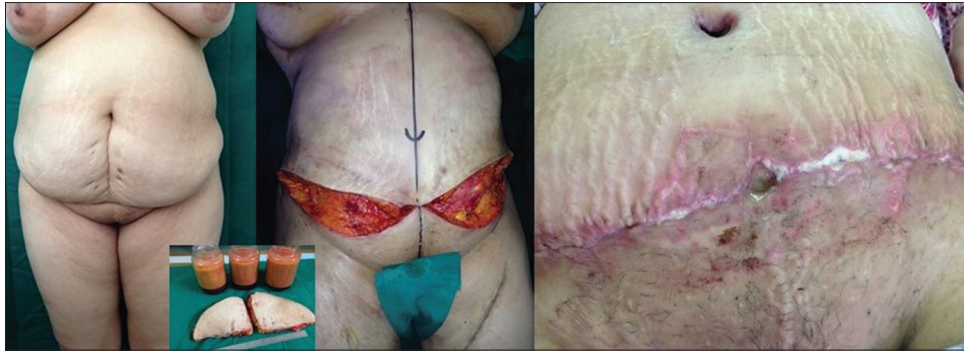

Figure 5: Wound dehiscence in drainless abdominoplasty seen in one patient secondary to seroma formation. Patient responded to conservative management without surgical intervention

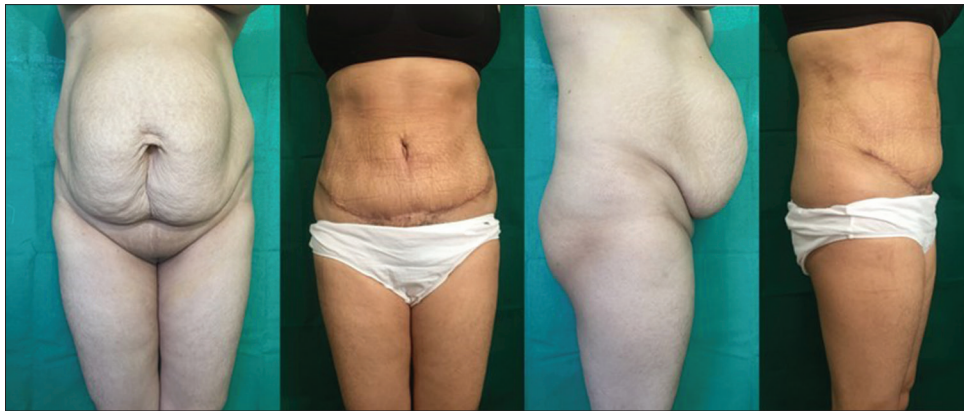


Figure 6: Pre- and post-operative pictures of patient shown in Figures 1, 3 and 4

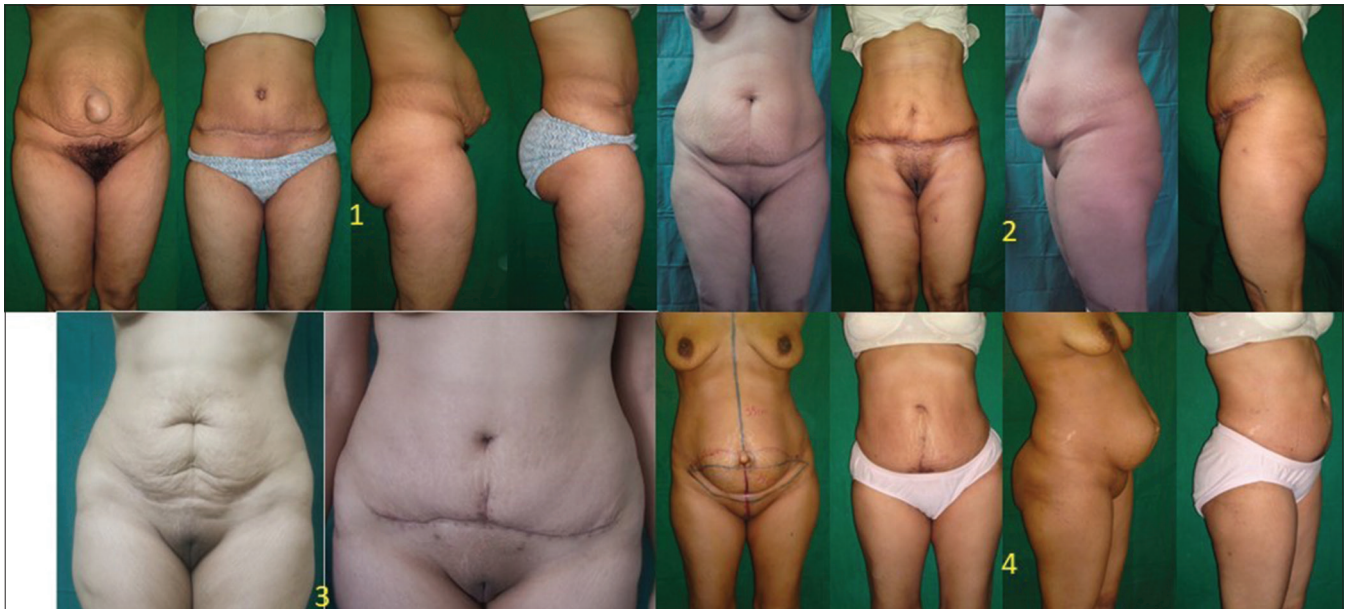

Figure 7: Results of drainless method in mild deformity patients. Patient 1 had umbilical hernia. Three had only skin excess

DISCUSSION

The primary purpose of inserting drain after any operation is to avoid accumulation of collecting fluid. The collected fluid gets lined by a pseudo capsule and

is termed seroma. The fluid also increases tissue tension and prevents wound healing. The source of seroma in abdominoplasty is residual infiltrate as well as damaged fat and fluid secreted in the third space. The third space fluid continues to form in post-operative period also.

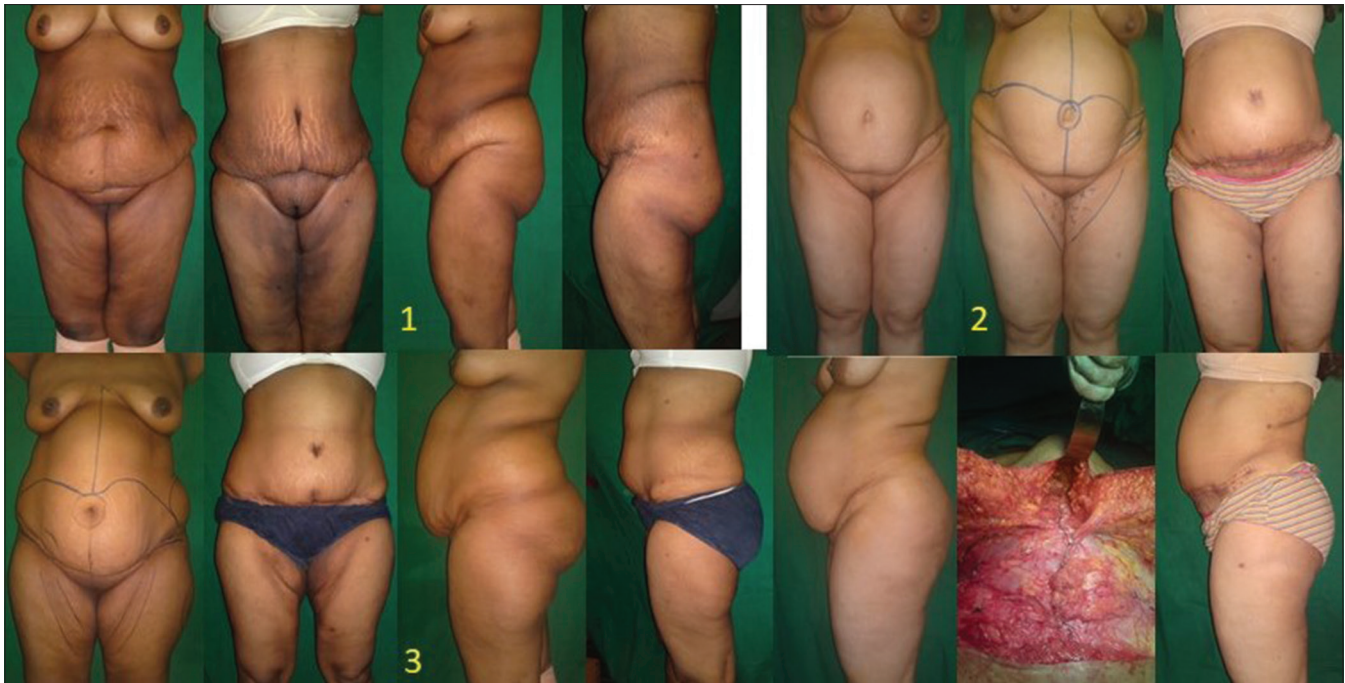


Figure 8: Results of drainless method in moderate deformities. Patient 3 had visceral fat deposits which were responsible for the residual bulge after abdominoplasty. Pre-op counselling was done

The disadvantages of drains have been widely documented as discomfort, pain, difficulty in mobilisation and blockage (which defeats their purpose). Drains may cause irritation of tissues and add to seroma formation, as noted by Koller and Hintringer.^[1]

Issues we had faced with drains before 2006 were as follows:

- a. Ineffective – the drains have tendency to get blocked as shown in Figure 10 – due to clotting of blood inside or due to tissue particles. Attempts to reduce blockage involved use of powerful floor suction three times daily to charge drains, removal of tissue using a stillette or by attaching a 50 cc syringe to create powerful negative force. This would convert a safe closed system to open system with substantial risk of iatrogenic infection; though none occurred in our patients. Beer and Wallner^[2] reported reduction of seroma by immobilising the patient for 48 h in a retrospective study of 60 patients. All these patients had drains, but those who were mobilised within 24 h had seroma rate of 13%, whereas among those mobilised after 48 h had drop in the seromas to 0%. They recommended thromboprophylaxis in all patients. This illustrates inefficacy of drains
- b. Discomfort – every patient who had drain (before or after 2006 when this series began); complained of pain ranging from discomfort to pricking sensation or local

pain. The relief after removal of drain was remarkable, only the dull pain of liposuction remained

- c. Difficulty in mobilisation – with drains in place, mobilisation of the patients was cumbersome. The staff had to manage the drains while the patient turned to one side in bed to get up in post-operative period. Patients were scared of drains getting pulled out and either declined mobilisation or complained of severe pain
- d. Breakage and premature extrusion caused concern
- e. Theoretically, bacterial colonisation could occur, though there is no concrete evidence that drains cause necrotising fasciitis in post-operative patients. We did not face infections in any of our abdominoplasty patients
- f. Increased duration of hospitalisation. However, this by itself is not a major reason to try to avoid drains.

Evidence in favour of use of drains is insufficient. Available studies exist, some in favour and some against use of drains to avoid seromas. Same is true for the question of drains as source of infection; with or without necrotising fasciitis.

The timing of drain removal is arbitrary. It may depend on drop in the output to a certain level or change in colour of fluid from reddish to amber to pale yellow. According to Chim *et al.*^[3] removal at a pre-decided fixed time has some supporting evidence.

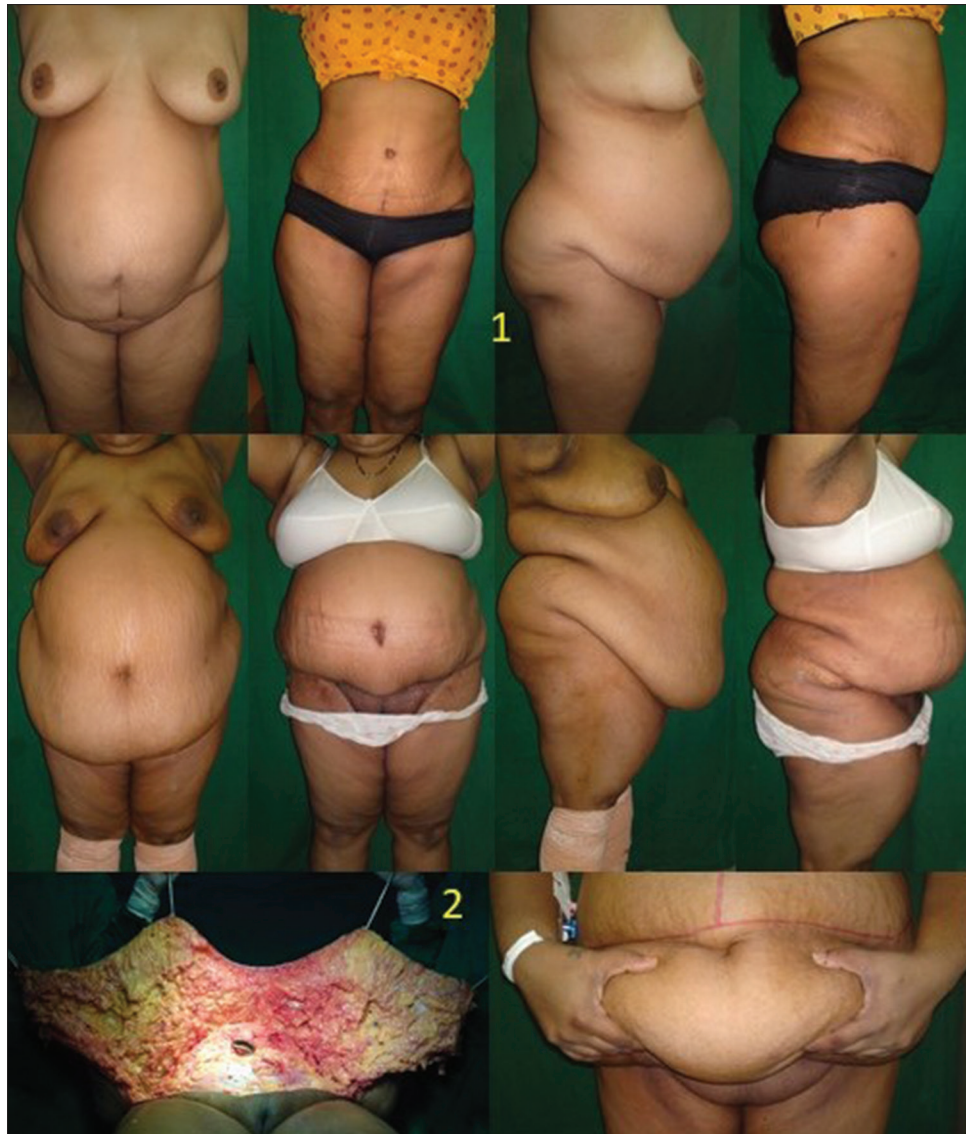

Figure 9: Results in severe deformity patients. Patient-1 had more subcutaneous fat whereas patient-2 had debulking apronectomy only as this patient had large visceral fat deposits. Apronectomy was planned for purpose of hygiene and mobility

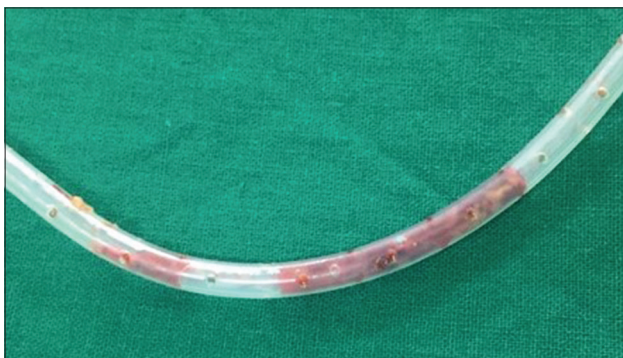

Figure 10: Drains get blocked with blood clots and tissue particles

Rangaswamy^[4] advocates initial synchronous liposuction, flap elevation at Scarpa's fascia level, discontinuous incremental flap dissection, vascular preservation and obliteration of sub-flap suture by multiple sutures for Indian Journal of Plastic Surgery Volume 51 Issue 1 January-April 2018

avoiding complications in abdominoplasty. We had started operating on similar lines from the beginning of our series in 2006.

We considered following aspects while deciding to do away with drains: (This was, in general, our protocol in liposuction patients from the year 2004 onwards – when the incidence of seroma had become nil in our practice).
a. Incidence of seromas and wound dehiscence has been shown to have reduced, *per se*, over the years and reduced further with incorporation of thorough liposuction in abdominoplasty.^[4]

Najera *et al.*^[5] described increase in the incidence of seroma if combined with flank liposuction and in high BMI patients between 2004 and 2007. Later, the reports clearly show reduction in average occurrence

of seromas across the globe. Heller *et al.*^[6] reported that modified transverse abdominoplasty with extensive liposuction was associated with least complications, including seroma formation, in a retrospective review in 2008. They compared four groups of patients, namely, liposuction alone, modified transverse abdominoplasty with and without liposuction and W-pattern abdominoplasty

Stewart *et al.*^[7] studied complications in a series of 278 consecutive abdominoplasties and reported 5% seromas, 3% haematoma and infection and 2.5% fat necrosis despite use of drains in 2006 – probably before the techniques were refined to use small cannulas

- b. Tumescence is not essential for liposuction.^[8] If adequate time out is observed after infiltration, one can get bloodless aspirate and surgical field. Thus, the input fluid was restricted to wet technique. Basically, tumescence was used for office procedures done under local anaesthesia. Abdominoplasty is invariably conducted under regional or general anaesthesia where the purpose of infiltration is mainly to increase turgidity of tissues thus facilitating suction, rather than providing analgesia for the procedure as in office suction. In fact, lower-volume infiltrate is preferred to allow removal of larger volumes without causing fluid overload. This is everyday experience of any plastic surgeon. We feel wet technique reduces the amount of fluid that stays in the raw area post-operatively compared to tumescence
- c. Smaller cannulas have been documented to avert tissue damage and ensuing complications, as shown by Teimourian and Rogers^[9]
- d. Superficial liposculpturing has been shown to create thin flaps that conform to bony contours giving better apposition of raw surfaces by Gasperoni *et al.*^[10,11] Najera *et al.*^[5] has shown increased incidence of seroma when flank liposuction is done in abdominoplasty. We think this happens because of thick flaps resulting from lack of suction of the superficial layers that do not conform to bony contours. The resultant space due to rigidity of the flap fills up with seroma. Zhang *et al.*^[12] mention difference between stiff and areolar superficial layer and deep lamellar layer of fat separated by superficial fascial system
- e. Full dissection as needed for the type of abdomen was done to produce best possible contour. Flaps were elevated at level of Scarpa's fascia leaving a significant amount of loose areolar tissue and some fat on rectus sheath. Najera *et al.*^[5] as well as Koller and Hintringer^[1]

mention similar technique and omitting use of drains. Antonetti and Antonetti^[13] postulated that seromas form when there is no adhesion between flap and the underlying tissues with shearing movements between them, especially when both surfaces are gliding. Our experience is commensurate with this. Baroudi and Ferreira^[14] in their original article indicate that fat-to-fat apposition along with progressive quilting has a role in the prevention of seroma

- f. Progressive quilting, to relieve tension on the incision and to improve apposition of raw areas, averts seromas – as reported by several authors. However, we found quilting to be time-consuming and tedious. Before the current series, a few cases were indeed done with quilting, but those are not included here. Number of studies show efficacy of barbed sutures in the prevention of seroma in controlled trials with and without drains. Mohan *et al.*,^[15] Drury Phillipa,^[16] Nahas *et al.*,^[17] Arantes *et al.*,^[18] Pollock and Pollock,^[19] Marsh *et al.*^[20] and Mohan as well as Liang *et al.*^[21] have shown usefulness of quilting barbed sutures in avoiding drains in abdominal donor areas of flap used in radical mastectomy reconstructions
- g. Another option to reduce the need for drains is fibrin sealant,^[22] but it is clearly shown to have higher incidence of seroma compared to drains and quilting sutures groups as shown by Bercial *al.*^[23] in a triple arm study. Even in the original prospective study by Hunstad *et al.*,^[22] 27.3% of the patients in whom urethane-based sealant was used, needed needle aspiration of fluid. We had similar experience while trying fibrin glue in skin grafting cases where excess sealant was found to form seromas, lifting the graft
- h. Finally, we decided to reduce the quantity of fluid left behind at the end of procedure by undertaking 'toilet liposuction' in addition to rolling the fluid out. The concept of toilet liposuction was born because of observation that if one restarts liposuction in an area that was treated a little while back, a lot of thinner lipo-aspirate can be removed. So to remove the residual fluid, cannula is left in one of the tunnels with suction on. As there is no to-and-fro movement, more fat is not damaged but third space fluid keeps coming. The interlobular septae being semi-permeable, it is possible to empty a large area by this method.

Toilet liposuction in the dependent areas like flanks and non-retractile areas like trochanter is done intermittently all through the procedure, and especially towards end when the suturing starts; for removal of residual

and secreted fluid as well as broken fat. The author recommends use of this new term and technique.

After closure is completed in multiple layers, with deepest layer incorporating the aponeurosis, the residual fluid is encouraged to be reabsorbed by the use of a well-fitting pressure garment.

Klein^[24] has described fluid shifts and post-operative fluid balance and mechanism of absorption of the residual volume. We also close all suction ports with single 6-0 ethilon stitch.

i. Non-removal of garment for 4 days and early mobilisation with garment promotes absorption due to muscle contraction. The timing of reversal of oedema in liposuction is thought to be 4 days.

Teimourian^[8] found 6% incidence of seroma in his own cases despite use of drains. A national survey of complications associated with suction lipectomy reported 1.2% incidence of seroma (935 plastic surgeons with data on 26,562 patients.) The authors, Teimourian and Rogers.^[9] felt that seroma was underreported. In our series, one patient had seroma despite drains, and it responded to multiple aspirations and debridement of small area of necrosed fat. The wound healed without any surgical intervention.

In an interesting paper, Zuelzer *et al.*^[25] have demonstrated lower wound complication rate in patients with BMI above 40. In our series also, high BMI panniculectomies healed well despite the absence of drains. Zuelzer *et al.* have also demonstrated significant reduction in incidence of abdominoplasty complications from 40% in a study in 1999 to 9% in a study from 2003 to 2008; in high BMI patients.

CONCLUSION

In a vast majority of patients undergoing abdominoplasty with liposuction, insertion of drains is unnecessary. Avoidance of drains was not found to be associated with seroma formation or wound-related complications. Although author would put a drain in case of doubt, first priority is to eliminate common reasons for the doubt, namely, excessive infiltration; gliding, thick and rigid flaps; poor haemostasis. Manoeuvres including toilet liposuction, multi-layered suturing with adequate tension relief, early mobilisation and uninterrupted

4-day pressure garment support help eliminate need for the drains without compromising extent of dissection and the final aesthetic result. Heat-based liposuction techniques like Vaser and laser would probably leave too much damaged tissue to be benefited by this policy.

Financial support and sponsorship

Nil.

Conflicts of interest

There are no conflicts of interest.

REFERENCES

1. Koller M, Hintringer T. Scarpa fascia or rectus fascia in abdominoplasty flap elevation: A prospective clinical trial. *Aesthetic Plast Surg* 2012;36:241-3.
2. Beer GM, Wallner H. Prevention of seroma after abdominoplasty. *Aesthet Surg J* 2010;30:414-7.
3. Chim JH, Borsting EA, Thaller SR. Urban myths in plastic surgery: Postoperative management of surgical drains. *Wounds* 2016;28:35-9.
4. Rangaswamy M. Minimising complications in abdominoplasty: An approach based on the root cause analysis and focused preventive steps. *Indian J Plast Surg* 2013;46:365-76.
5. Najera RM, Asheld W, Sayeed SM, Glickman LT. Comparison of seroma formation following abdominoplasty with or without liposuction. *Plast Reconstr Surg* 2011;127:417-22.
6. Heller JB, Teng E, Knoll BI, Persing J. Outcome analysis of combined lipoabdominoplasty versus conventional abdominoplasty. *Plast Reconstr Surg* 2008;121:1821-9.
7. Stewart KJ, Stewart DA, Coghlan B, Harrison DH, Jones BM, Waterhouse N, *et al.* Complications of 278 consecutive abdominoplasties. *J Plast Reconstr Aesthet Surg* 2006;59:1152-5.
8. Teimourian B. Management of seroma in abdominoplasty. *Aesthet Surg J* 2005;25:510-1.
9. Teimourian B, Rogers WB 3rd. A national survey of complications associated with suction lipectomy: A comparative study. *Plast Reconstr Surg* 1989;84:628-31.
10. Gasperoni C, Salgarello M, Emiliozzi P, Gargani G. Subdermal liposuction. *Aesthetic Plast Surg* 1990;14:137-42.
11. Gasperoni C, Gasperoni P. Subdermal liposuction: Long-term experience. *Clin Plast Surg* 2006;33:63-73, vi.
12. Zhang YX, Lazzeri D, Grassetti L, Silvestri A, Trisliana Perdanasari A, Han S, *et al.* Three-dimensional superficial liposculpture of the hips, flank, and thighs. *Plast Reconstr Surg Glob Open* 2015;3:e291.
13. Antonetti JW, Antonetti AR. Reducing seroma in outpatient abdominoplasty: Analysis of 516 consecutive cases. *Aesthet Surg J* 2010;30:418-25.
14. Baroudi R, Ferreira CA. Seroma: How to avoid it and how to treat it. *Aesthet Surg J* 1998;18:439-41.
15. Mohan AT, Charalambos KR, Gaba P, Schupbach J, Goede WJ, Ballman K, *et al.* Modified aesthetic abdominoplasty approach in perforator free flap breast reconstruction: Impact of drain-free donor site on patient outcome. *J Plast Reconstr Aesthet Surg* 2015;68:800-9.
16. Drury Phillippa K. A cost effective modification in progressive barbed suture closure of the abdominal donor site in DIEP

- and MS-TRAM patients; a review of surgical technique J Plast Reconstr Aesthet Surg 2017;70:136-8.
17. Nahas FX, Ferreira LM, Ghelfond C. Does quilting suture prevent seroma in abdominoplasty? Plast Reconstr Surg 2007;119:1060-4.
 18. Arantes HL, Rosique RG, Rosique MJ, Mélega JM. The use of quilting suture in abdominoplasty does not require aspiratory drainage for prevention of seroma. Aesthetic Plast Surg 2010;34:102-4.
 19. Pollock TA, Pollock H. No-drain abdominoplasty with progressive tension sutures. Clin Plast Surg 2010;37:515-24.
 20. Marsh DJ, Fox A, Grobbelaar A, Chana JS. Abdominoplasty and seroma: A randomised prospective study comparing scalpel and handheld electrocautery dissection. J Plast Reconstr Aesthet Surg 2015;68:192-6.
 21. Liang DG, Dusseldorp JR, van Schalkwyk C, Hariswamy S, Wood S, Rose V, *et al.* Running barbed suture quilting reduces abdominal drainage in perforator-based breast reconstruction. J Plast Reconstr Aesthet Surg 2016;69:42-7.
 22. Hunstad JP, Michaels J, Burns AJ, Slezak S, Stevens WG, Clower DM, *et al.* A prospective, randomized, multicenter trial assessing a novel lysine-derived urethane adhesive in a large flap surgical procedure without drains. Aesthetic Plast Surg 2015;39:616-24.
 23. Bercial ME, Sabino Neto M, Calil JA, Rossetto LA, Ferreira LM. Suction drains, quilting sutures, and fibrin sealant in the prevention of seroma formation in abdominoplasty: Which is the best strategy? Aesthetic Plast Surg 2012;36:370-3.
 24. Klein JA. Superwet technique and pulmonary edema. In: Jeffrey A Klein, author. *Tumescent Technique, Tumescent Anesthesia and Microcannular Liposuction*. 1st ed St. Louis, Missouri, Mosby Inc; 2000. p. 61-6.
 25. Zuelzer HB, Ratliff CR, Drake DB. Complications of abdominal contouring surgery in obese patients: Current status. Ann Plast Surg 2010;64:598-604.