

## Case Report

# Unclassified congenital deformities of the external ear

**Madhubari Vathulya**

Department of Burns and Plastic Surgery, AIIMS, Rishikesh, Uttarakhand, India

**Address for correspondence:** Dr. Madhubari Vathulya, 401, Anand Legacy Apartments, Haridwar Road, Shastri Nagar, Dehradun - 248 001, Uttarakhand, India. E-mail: madhubari@yahoo.co.in

### ABSTRACT

Congenital ear deformities are a common entity. They are found in isolation or as a part of syndrome in patients. They may involve the external, middle or inner ear or in any of these combinations. Three patients of different ages presented with deformities including mirror image duplication of the superior auricle, unclassified deformities of ear lobule (wavy lobule) and deformity of superior auricle with unclassified variety of lateral ear pit. This article highlights that there are further cases of ear deformities that are noticed in the general population who come for cosmetic correction, and hence, there is a need for further modifying the classification of ear deformities.

### KEY WORDS

Congenital; external ear deformities; unclassified

### INTRODUCTION

About half the incidence of malformation of the ENT region involves the ear. These malformations can be studied as ones which involve the external ear, middle ear or the inner ear or in any combinations of these. The deformities of the external ear have been described on the embryological basis by Weerda<sup>[1]</sup> which is one of the accepted classifications in today's scenario. However, there are still more malformations and deformities which are being discovered which have not been highlighted even by such elaborate studies. In this article, we introduce three such cases.

### CASE REPORTS

#### Case 1

A 25-year-old male presented in the outpatient department requesting for left ear lobule deformity correction for cosmetic reasons. He had no other functional difficulties including hearing on both sides. There was no positive family history and no significant drug intake by his mother during the conception period as elicited from the history.

On local examination, there was a wavy deformity [Figure 1a] of the lobule in the part that attaches the ear to the side of the face. Rest of the ear

This is an open access journal, and articles are distributed under the terms of the Creative Commons Attribution-NonCommercial-ShareAlike 4.0 License, which allows others to remix, tweak, and build upon the work non-commercially, as long as appropriate credit is given and the new creations are licensed under the identical terms.

**For reprints contact:** reprints@medknow.com

**How to cite this article:** Vathulya M. Unclassified congenital deformities of the external ear. Indian J Plast Surg 2018;51:98-100.

Access this article online	
Quick Response Code:	Website: www.ijps.org
	DOI: 10.4103/ijps.IJPS_163_17

was normal. The surgical planning [Figure 1b] was done. Local flaps raised, hillock remnant excised and correction achieved. The post-operative appearance is as shown in Figure 1c.

### Case 2

A 28-year-old female presented with cup deformity [Figure 2a] (type-IIb deformity of external ear of Weerda classification) of the right external ear with no hearing difficulty. On further examination, she was found to have an occlusion cant to the right with hypoplasia of the mandibular and zygomaticomaxillary complex on the right side, suggesting some mild form of craniofacial microsomia. On further examination of the furled helix, a skin pit was also discovered [Figure 2b]. The surgical planning was done as described [Figure 2c]. The abnormal cartilage strut underlying the skin pit revealed a cyst and was excised [Figure 2c] and a satisfactory ear shape was achieved [Figure 2d and e].

### Case 3

An 8-year-old girl was brought by her mother to the outpatient department for surgical correction of a deformity of her external ear on the right side. The patient was previously reviewed by the otorhinolaryngology department and evaluated for hearing functions. On local examination, the upper part of the auricle was found duplicated in the form of a mirror image [Figure 3a]. The rest of the face on the right side also was less developed compared to the left with an occlusal cant to the right again suggesting mild craniofacial microsomia. No positive family history or drug history was elicited.

After optimising the patient for surgery, the planning was done [Figure 3b] and correction also achieved. A part of the cartilage remnant in the duplicated part was also used to fill the pre-auricular hollow. The follow-up result was as shown in Figure 3c.

## DISCUSSION

Congenital ear deformities often present themselves in plastic surgery and ENT clinics throughout the world. They have an incidence of 1 in every 3800 births.<sup>[2]</sup> The most common representations are deformed external ear with or without hearing difficulties. Embryologically, the external ear develops from six axillary hillocks.<sup>[1]</sup>

They can be genetic (syndromic,<sup>[3]</sup> non-syndromic, positive family history or spontaneous mutations) or acquired in

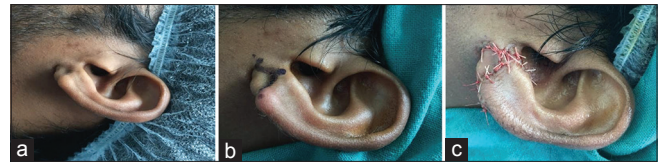

Figure 1: (a) Pre-operative wavy lobule deformity (b) surgical planning (c) post-operative photograph

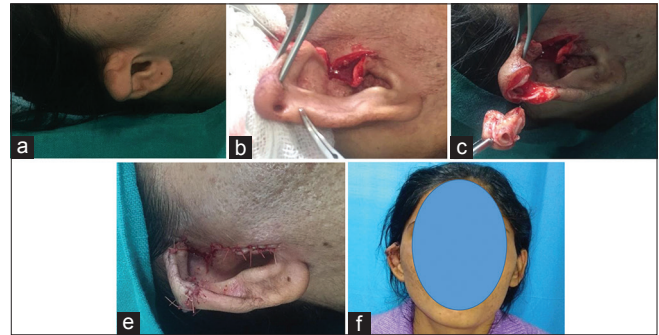

Figure 2: (a) Pre-operative cup deformity (b) sinus with pit (c) excision of cyst and correction of deformity (d) immediate post-operative picture (e) 6-month follow-up

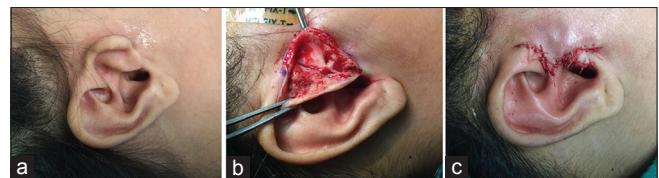


Figure 3: (a) Mirror duplication of the auricle (b) surgical planning (c) post-operative photograph

nature. Numerous classifications have been described for these deformities zone wise. Weerda's<sup>[1]</sup> classification is a well-accepted classification for external ear deformities. Similarly, Kösling *et al.*<sup>[4]</sup> description for middle ear and Jackler *et al.*,<sup>[5]</sup> Marangos<sup>[6]</sup> and Sennaroglu's<sup>[7]</sup> classification for inner ear deformities are well known.

The deformities of the external ear have been described with regard to the involved hillock (Weerda).<sup>[1]</sup> The presence of cysts and pits have also been described in this classification as type 1 and 2 (Weerda).<sup>[1]</sup>

The unusual part of these deformities is that they do not fit into the earlier classifications and documentation of external ear deformity.

The first case which describes as lobule deformity is probably involving the hillock 6 but without any cleft (which is the usual presentation). Unlike the usual right-sided presentation, this case involved the left side as an added unusual feature.

The second case which involves the helical part of the auricle involving the superior part (hillock 3 involvement) also presents with a skin pit ending in the sinus cavity lined by epithelium inside the abnormal cartilage part of the helix. This pit which is in the auricular location unlike in the preauricular area is also an unusual presentation and does not fit into either of the classifications of Weerda<sup>[1]</sup> (type 1 or 2). The pit did not end in the upper part of the sternocleidomastoid as traditionally described. This patient's other external characteristics fits into the mild type of craniofacial microsomia. The side affected in this patient was the right side which along with the unilateral presentation is in consensus with the rest of the descriptions<sup>[8]</sup> about congenital ear deformities.

The third and the final case scenario describing a complete duplication and in fact a mirror image of the superior part of the external auricle (corresponding to 1<sup>st</sup> and 2<sup>nd</sup> axillary hillock) is an extremely rare presentation of external ear deformity. The patient also fitted into the craniofacial microsomia syndrome and again the right side was involved.

Ear tags are mandibular tissue outgrowths on the margins of the first branchial groove. Due to the shifting of the hyoid mandibular border following closure of the first branchial groove, these ear tags come to lie between the ear and the cheek. These cheek ears as in the last case can be regarded as large ear tags according to Otto.<sup>[9,10]</sup>

Whether the first case is a genetic or acquired deformity will be revealed only after the patient is subjected to the genetic analysis. The rest two patients are clearly of genetic aetiology as revealed from the association of craniofacial microsomia features.

## CONCLUSION

Even though these three cases can be viewed as part of the classifications described by previous authors, this article highlights them in view of giving the readers an

opportunity to realise their different ways of presentation and also suggests their possible surgical management.

## Declaration of patient consent

The authors certify that they have obtained all appropriate patient consent forms. In the form the patient(s) has/have given his/her/their consent for his/her/their images and other clinical information to be reported in the journal. The patients understand that their names and initials will not be published and due efforts will be made to conceal their identity, but anonymity cannot be guaranteed.

## Financial support and sponsorship

Nil.

## Conflicts of interest

There are no conflicts of interest.

## REFERENCES

1. Weerda H. Surgery The pinna. Injuries, defects and anomalies. Stuttgart: Thieme; 2004. p. 105-226.
2. Bartel-Friedrich S, Wulke C. Classification and diagnosis of ear malformations. *GMS Curr Top Otorhinolaryngol Head Neck Surg* 2007;6:5.
3. Tewfik TL, Teebi AS, Der Kaloustian VM. Appendix A. Syndromes and conditions associated with congenital anomalies of the ear. In: Tewfik TL, Der Kaloustian VM, editors. *Congenital Anomalies of the Ear, Nose, and Throat*. New York: Oxford University Press; 1997. p. 125-44.
4. Kösling S, Schneider-Möbius C, King E, Master EF. Computed tomography in children and adolescents suspected of a rock leg malformation. *Radiologist* 1997;37:971-6.
5. Jackler RK, Luxford WM, House WF. Congenital malformations of the inner ear: A classification based on embryogenesis. *Laryngoscope* 1987;97:2-14.
6. Marangos N. Dysplasia of the inner ear and inner auditory canal. *ENT* 2002;50:866-81.
7. Sennaroglu L, Saatci I. A new classification for cochleovestibular malformations. *Laryngoscope* 2002;112:2230-41.
8. Wareing MJ, Lalwani AK, Jackler RK. Development of the ear. In: Bailey BJ, editor. *Head and Neck Surgery – Otolaryngology*. Philadelphia: Lippincott Williams and Wilkins; 2001. p. 1609-19.
9. Otto HD. Pathogenesis of the preauricular appendages, melotia, and poliotia (author's transl). *Arch Otorhinolaryngol* 1979;225:45-56.
10. Otto HD. Pathogenesis of branchiogenic excesses. *ENT practice* 1983;8:161-9, 247.