

Original Article

A retrospective analysis of latissimus dorsi–serratus anterior chimeric flap reconstruction in 47 patients with extensive lower extremity trauma

Ravi Kumar Mahajan, Krishnan Srinivasan, Abhishek Bhamre, Mahipal Singh, Prakash Kumar, Ankush Tambotra¹

Department of Plastic and Reconstructive Surgery, ¹Amandeep Hospital and Clinics, GT Road, Model Town, Amritsar 143001, Punjab, India

Address for correspondence: Dr. Krishnan Srinivasan, Department of Plastic and reconstructive Surgery, Amandeep Hospital and Clinics, Gt Road, Model Town, Amritsar - 143 001, Punjab, India. E-mail: s.drkrish@gmail.com

ABSTRACT

Background: Many flaps have been described for reconstruction of lower extremity defects, including, Latissimus Dorsi, Rectus abdominis, Anterolateral thigh perforator flaps, each having advantages and disadvantages. The defect location, size and specific geometric pattern of defect influences the type of flap that can be used. In this case series, we describe the specific situations where the use of chimeric latissimus dorsi–serratus anterior (LD + SA) free flaps are of advantage in providing complete wound cover. **Materials and Methods:** Case records of all patients who underwent LD + SA free flap transfer for lower extremity trauma at Amandeep Hospital, from Feb 2006 to Feb 2017 were reviewed. Patients were categorised based on the anatomical location and size of defect. The method of usage of the chimeric segments, recipient vessels and type of anastomosis were noted. Flap complications, if any were reviewed. **Result:** 47 patients with lower limb defects were included in the study. All cases were post traumatic in nature. Defect size ranged from 180 sq cm to 1050 sq cm. Average defect size was 487.70 sq cm. All patients underwent soft tissue reconstruction with LD + SA flap. Complete wound cover was obtained. **Conclusion:** Latissimus dorsi + Serratus anterior free tissue transfer is an effective, reliable method of providing cover to extensive lower limb traumatic defects with minimal donor site morbidity, with added freedom of inset and flap positioning. Specific use is seen in patients with broad proximal defect, long defect in the leg, defects involving adjacent anatomical areas and in large defect with dead space.

KEY WORDS

Chimeric flap; latissimus dorsi; lower limb reconstruction; serratus anterior; trauma

Access this article online	
Quick Response Code: 	Website: www.ijps.org
	DOI: 10.4103/ijps.IJPS_121_17

This is an open access article distributed under the terms of the Creative Commons Attribution-NonCommercial-ShareAlike 3.0 License, which allows others to remix, tweak, and build upon the work non-commercially, as long as the author is credited and the new creations are licensed under the identical terms.

For reprints contact: reprints@medknow.com

How to cite this article: Mahajan RK, Srinivasan K, Bhamre A, Singh M, Kumar P, Tambotra A. A retrospective analysis of latissimus dorsi–serratus anterior chimeric flap reconstruction in 47 patients with extensive lower extremity trauma. Indian J Plast Surg 2018;51:24-32.

INTRODUCTION

Road traffic accidents are a major cause of disability across the globe. It is estimated that two million people in India suffer from disability related to road traffic accidents (RTA).^[1] Most of these are in the productive age group of 15–44.^[1] Appropriate and complete wound cover for lower limb trauma and fracture form an important aspect which helps in recovery and rehabilitation of trauma patient.

Even with the advent of microvascular-free tissue transfer, management of extensive lower limb defects remains a challenge. Various fasciocutaneous and musculocutaneous flaps such as anterolateral thigh flap,^[2] latissimus dorsi (LD) muscle flap, gracilis muscle flap and rectus abdominis flap have been described for the management of lower extremity reconstruction.^[3] High-velocity trauma at times, produces lower limb defects which cannot be covered with any single flap alone, either due to the sheer size of defect or its geometrical alignment and anatomical location. Defects which are broad, especially at the proximal part, are difficult to be covered even by LD muscle alone as the proximal muscle part of the muscle is narrower.

Inability to provide complete cover could result in the need for amputation.

Although the use of subscapular system-based chimeric flaps has been described for lower extremity reconstruction,^[3] the number of cases in the series is limited.

We present a study of subscapular system-based combined LD+SA chimeric free tissue transfer for reconstruction of extensive defects of the lower limb, in a series of 47 patients. In this article, we highlight the specific anatomical features and geometrical arrangement of post-traumatic defects where the use of LD + SA chimeric flap would be of advantage over other flaps.

MATERIALS AND METHODS

This study was undertaken in conformity with the Declaration of Helsinki.

Case records of all patients who underwent LD + SA free flap transfer for lower extremity reconstruction at Amandeep Hospital, Amritsar, from February 2006 to

February 2017 were reviewed. Patients were categorised based on the anatomical location of the defect and size of defect. The method of usage of the chimeric muscle segments, ischaemia time, recipient vessels and type of anastomosis were noted. Flap complications if any were reviewed.

The wound was divided based on anatomical location into – upper 1/3rd, middle 1/3rd or lower 1/3rd of leg, dorsum or sole of the foot or a combination of the above-mentioned anatomical areas. The maximum dimensions of the wound were measured with a sterile measuring tape. This was used to decide on the dimensions of the flap needed. The surface area was calculated by making a template of defect on a sterile lint cloth and superimposing it on a graph paper and the number of squares calculated.

Use of SA to fill the depth of the wound or to cover large defects was documented.

LD was harvested in the standard method described. Upper three slips of SA were left in place. Lower 4 slips were harvested based on the branch from the thoracodorsal artery.

Complications in terms of immediate partial or complete flap loss, need for re-exploration and delayed complications in the form of unstable scar, non-healing ulcers were documented.

Following flap cover and stabilisation of the flap, further fracture management was done by the orthopaedic team.

Surgical procedure

Pre-operative marking was made with the patient in sitting position^[4]. The anterior border of LD was marked. Tip of the scapula and the midline of back were marked. Iliac crest was marked.

The side of harvest depended on the recipient vessel. In case of anastomosis to the anterior tibial pedicle, the same side muscle was chosen, and in case of posterior tibial pedicle, opposite side was chosen, as access to the recipient vessel was possible without change of position intraoperatively. The two-team approach was made. One team dissected the recipient vessels and also completed the debridement of wound, while the other team harvested the flap. Infiltration with adrenaline–saline solution was made (1 in 200,000) along the incision line. S-shaped

incision along the anterior border of LD was made. Muscle was dissected from overlying subcutaneous tissue and from the underlying muscles. Thoracodorsal pedicle was dissected till the subscapular vessels. The branch to serratus anterior was preserved^[5]. The point of entry of the SA branch of the thoracodorsal artery into the SA muscle was noted, and slips of SA, inferior to that are dissected off the medial border of the scapula and the underlying ribs [Figures 1 and 2].^[6] Thus, upper three slips of SA were preserved and lower four slips harvested along with LD. During flap harvest, after raising the entire LD muscle, the distal perfusion is checked before dividing the flap.^[4]

Once the recipient bed was ready, the flap was divided and anastomosis done using 9/0 nylon sutures. Donor site was closed in layers over suction drain. The flap was skin grafted on the 3rd post-operative day.

RESULTS

A total of 47 patients with lower limb defects were included in the study. All cases were post-traumatic in nature, following road traffic accident. A total of 33 of them had right lower limb involvement and 14 had left lower limb involvement. The mean age of patients was 34.70, with age range of patients being from 7 to 62 years. Four patients were women and 43 were men.

Among the 47 patients, 43 were men and four were women. There was one patient in the 0–10 years group, 7 in the 11–20 years group, 12 in 21–30 years, 12 in 31–40 years, 8 in 41–50 years, 3 in 51–60 years and 3 in 61–70 years.

Among the total of 47 patients, 2 had defects involving knee and upper 1/3rd; 6 had involvement of upper and middle 1/3rd, 2 had involvement of middle and lower 1/3rd, 19 had involvement of lower 1/3rd and foot, out of which, six had involvement of heel pad and dorsum of foot, while 13 had only dorsum of foot involved. Nine patients had involvement of the foot and ankle, out of which, four had involvement of heel along with dorsum and five had involvement of dorsum and ankle region alone, sparing the heel. Six patients had the entire leg involved [Figure 3]. One patient had distal 1/3rd involvement and partial amputation at that level. Two patients had involvement of middle 1/3rd to foot involvement. Defect size ranged from 180 cm² to 1050 cm². Average defect size was 487.70 cm² [Table 1].

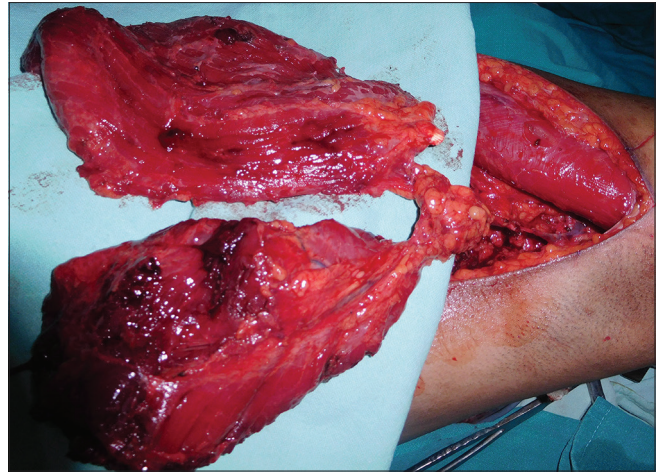


Figure 1: Latissimus dorsi + serratus anterior flap harvest – patient in lateral position. The common thoracodorsal pedicle is shown and the muscles have been completely dissected

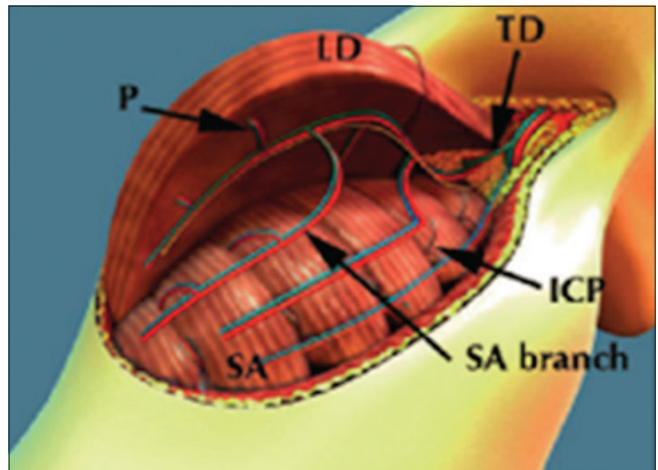


Figure 2: Preservation of upper 3 slips of serratus anterior by raising the flap below the point of entry of the vascular pedicle to serratus anterior

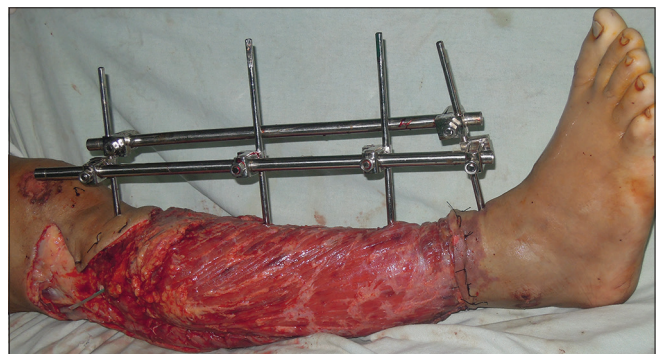


Figure 3: Defect involving the entire leg – covered by latissimus dorsi + serratus anterior flap over the bony part

Patient details are described in Table 2.

All patients underwent radical wound debridement and external fixation of the fracture (by orthopaedic team) initially, followed by LD + SA free tissue transfer within

the next 72 h. All patients underwent debridement as soon as possible and never later than 12 h after injury. Patients who underwent free flap on the 2nd day after injury and debridement have been classified as being operated at 48 h, and ones on the 3rd day after injury as 72 h. In our study, 43 patients underwent flap on day 2 (48 h) following injury, 4 on the 3rd day (72 h following injury).

Twenty-one patients had anastomosis done with the posterior tibial artery, 20 to the anterior tibial artery, 5 to the sural artery and 1 to lateral genicular artery. All anastomosis was performed end to end. The SA was used to fill the wound cavity in 10 patients and for large surface area in 37 patients.

One patient had complete flap necrosis which was managed with negative pressure wound therapy followed by cross-leg flap + skin graft of remaining raw area. Three flaps were re-explored due to venous congestion. Revision anastomosis was done and flap was salvaged. Partial flap necrosis was seen in two flaps which was managed with debridement and skin graft. Donor site morbidity – four patients had seroma formation which subsided with repeated aspirations. Five patients developed hypertrophic scar on the donor site suture line which was managed by triamcinolone injections and silicone gel sheet application.

Winging of the scapula was seen in one patient, though she did not have any complaints. Five patients, who had undergone resurfacing of foot defects, complained of flap being too bulky and underwent debulking procedure. One patient developed wound breakdown at the medial malleolar region at 2-year post-surgery. He was managed with dressings and skin graft.

Case 1

The case is an 18-year-old male with a history of RTA. There was a compound fracture in the tibia and patella

with defect involving the knee and upper 1/3rd of the right leg. Debridement and external fixator application were done [Figure 4a]. On the 2nd post-operative day, LD + SA free flap was done. Anastomosis was done to the lateral genicular artery, in a healthy plane posterior to the zone of trauma [Figure 4b and c]. The two muscles could be inset on either side of anastomosis, hence enabling complete wound cover [Figure 4d].

Case 2

The case was a 35-year-old male with the history of RTA. The defect involved part of the middle 1/3rd and lower 1/3rd of leg as well as ankle, dorsum of foot and heel [Figure 5a]. Muscles of deep posterior and part of anterior compartment were non-viable and were debrided, leaving a large defect needing filling of dead space around the bone. LD flap along with SA was harvested. SA was placed around the muscle in the depth of the wound [Figures 5b, c and d].

Case 3

A 21-year-old female presented with a history of RTA. The left foot involved heel pad avulsion [Figure 6a]. Debridement + LDSA flap was done. SA was used to cover the heel and LD to cover the remaining raw area. Partial overlap of the two flaps at inset was present [Figure 6b, c and d].

She developed winging of scapula. She did not have any shoulder weakness or complaints regarding day-to-day function.

Case 4

A 51-year-old male with a history of RTA sustained injury to the right leg with fracture tibia and degloving of skin over the leg. After debridement, he had a defect involving the upper 1/3rd to lower 1/3rd [Figure 7a]. The defect was broad proximally. SA was used to cover the broad proximal aspect and LD the remaining part of the wound [Figure 7b, c and d].

Table 1: Patient distribution according to the anatomical location of defect

<i>Anatomical location of defect</i>	<i>Number of patients</i>
Knee + upper 1/3 rd	2
Upper + middle 1/3 rd	6
Middle + lower 1/3 rd	2
Lower 1/3 rd + ankle and foot	19
With heel involvement	6
Without heel involvement	13
Ankle + foot	9
With heel involvement	4
Without heel involvement	5
Entire leg	6
Other combination	3

DISCUSSION

Extensive defects of lower extremities still have high rates of amputation because coverage of the defects is difficult even with largest conventional free flaps.^[3] Flaps that can be used for coverage of large lower limb defects with primary donor site closure are the LD muscle/myocutaneous flap, rectus abdominis^[7] muscle flap and occasionally even DIEP flap.^[8] Other options of coverage would be use of multiple flaps.

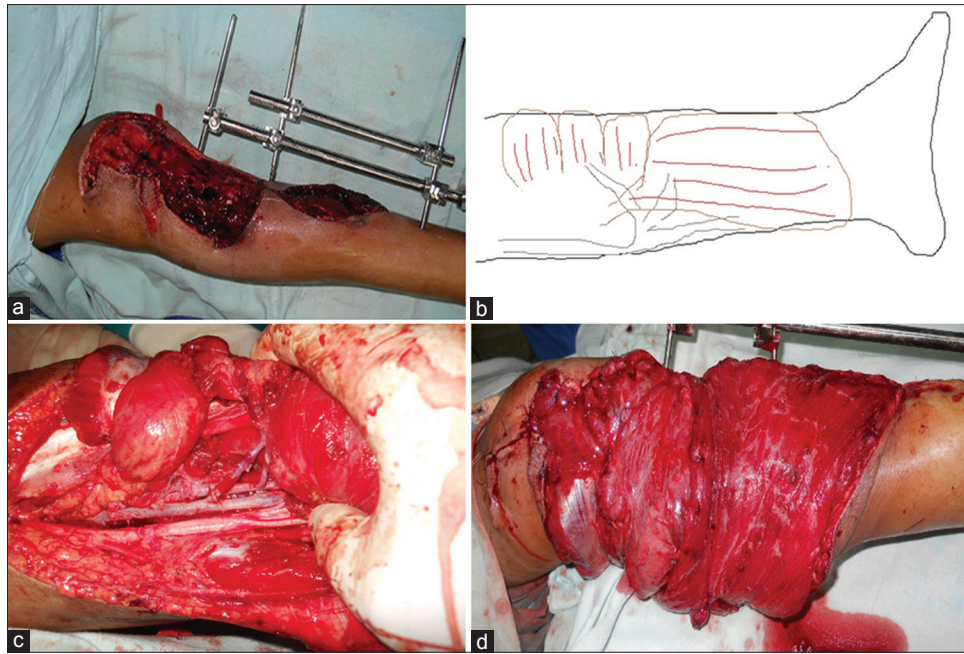


Figure 4: (a) Long defect involving upper and middle 1/3rd of the leg. (b) Line diagram showing the anastomosis in a healthy zone posteriorly with the zone of trauma being in the anterior segment. Serratus anterior and latissimus dorsi are inset on either side of the anastomosis to provide complete wound cover. (c) end-to-end anastomosis of thoracodorsal donor vessels to the lateral genicular recipient vessel posteriorly with anterior zone of trauma. Serratus anterior and latissimus dorsi are inset on either side of anastomosis. (d) Latissimus dorsi and serratus anterior inset on either sides of the anastomosis

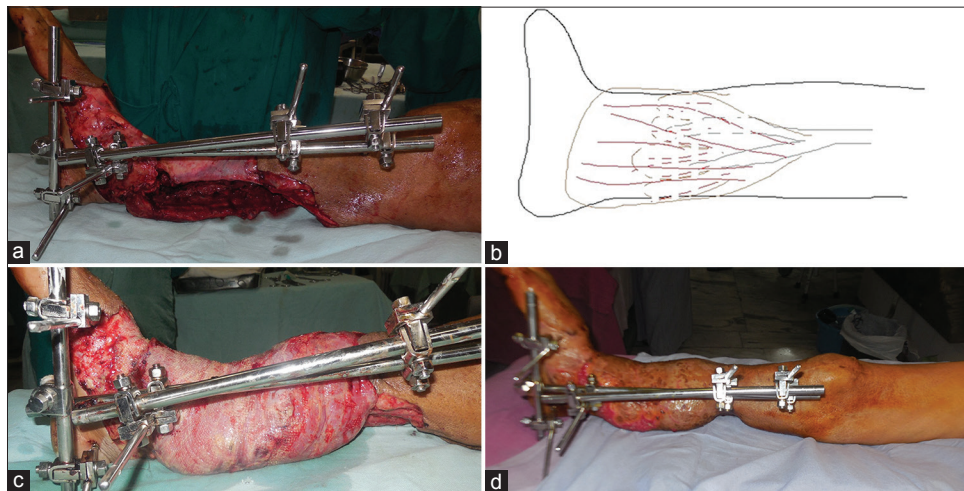


Figure 5: (a) Defect involving part of mid-lower 1/3rd of leg and ankle. Wound cavity in the lower 1/3rd of the leg around the tibia. (b) Line diagram showing serratus anterior used to fill the dead space surrounding the bone and latissimus dorsi used to surface the remainder of defect. (c) Photograph of dead space at lower leg filled by serratus anterior and remainder resurfaced with latissimus dorsi flap. (d) Six-week follow-up

Anterolateral thigh flap with vastus lateralis muscle chimeric flap has been used by Wong *et al.*^[2] Use of large skin flap from ALT region necessitates skin graft and also use of large amount of vastus lateralis may cause weakness in knee extension.^[3]

The use of conjoined flap, in the form of LD myocutaneous flap with parascapular flap, has been described for coverage of large defects.^[9] As the flaps share a common vascular pedicle in the form of subscapular artery, a single anastomosis was needed. As large area of skin is used as

donor flap, skin grafting was needed in most patients to resurface donor defect. In contrast, when LD + SA muscle flap is used, donor site can always be primarily closed.

Use of combined vertical rectus abdominis musculocutaneous (VRAM) and transverse rectus abdominis musculocutaneous flap has been described, as a case report, for coverage of extensive leg defect.^[10] It has the advantage of being able to cover an extensive area. Donor site can also be closed primarily. There can be post-operative hernia development if the fascial layer is not meticulously

Table 2: Patient details

Age	Sex	Side	Site of involvement in leg	Recipient vessel	Anastomosis	Ischaemia time	Defect size (cm ²)
38	Male	Right	L + ankle + D	PT	EE	2 h	180 + DS
17	Male	Left	L + ankle + D	AT	EE	3 h	800
62	Male	Right	L + ankle + D	AT	EE	3 h	225
46	Male	Right	L + ankle + D + P + Heel	PT	EE	2.5 h	1050
38	Male	Right	L + ankle + D	PT	EE	2.5 h	900
46	Male	Left	C + L	PT	EE	2 h	700
32	Male	Right	U + C + L	SA	EE	2.5 h	770
36	Male	Left	Ankle + D	PT	EE	3 h	875
27	Male	Right	Ankle + heel pad + P	PT	EE	3 h	425
52	Male	Right	Ankle + D	PT	EE	2 h	500
47	Male	Left	L + ankle + D	PT	EE	2.5 h	448
26	Female	Right	Knee + U + popliteal	SA	EE	3 h	475 + DS
28	Male	Right	U + C	SA	EE	2.5 h	450
28	Male	Left	L + near total amputation	AT	EE	2.5 h	375 + DS
18	Male	Right	U + C	SA	EE	2.5 h	420
25	Male	Right	L + ankle + D	PT	EE	2 h	625
30	Male	Left	L + ankle	PT	EE	2 h	600 + DS
42	Male	Right	L + ankle + P	PT	EE	2.5 h	400
12	Male	Right	Ankle + D	AT	EE	2 h	320
32	Male	Right	L + ankle + D	AT	EE	1 h	384
34	Male	Left	L + ankle + D	AT	EE	2 h	270 + DS
13	Male	Right	Ankle + D	AT	EE	2 h	400
61	Female	Right	L + ankle + D + heel	PT	EE	1 h	750
30	Male	Right	U + C	AT	EE	2 h	300 + DS
7	Female	Left	L + ankle + D	AT	EE	2 h	420
14	Male	Right	L + ankle + D	AT	EE	1 h	360
62	Male	Right	U + C	AT	EE	2 h	480
52	Male	Right	C + L + ankle	AT	EE	2 h	486 + DS
34	Male	Right	U + C	AT	EE	2 h	252 + DS
28	Male	Right	L + ankle	AT	EE	2.5 h	300
45	Male	Right	U + C	SA	EE	2 h	270 + DS
21	Female	Left	Ankle + heel pad + P	PT	EE	3 h	375
18	Male	Right	L + ankle + D	PT	EE	2 h	420
49	Male	Right	C + L + ankle	PT	EE	2 h	1050
52	Male	Left	L + ankle + D + heel pad	PT	EE	3 h	600
60	Male	Left	L + ankle + D	AT	EE	2 h 30 min	286
24	Male	Right	Ankle + heel + P	AT	EE	3 h	375
45	Male	Left	L + ankle + D + heel	PT	EE	2 h	726
25	Male	Right	Ankle + D + P	PT	EE	2 h	500
50	Male	Right	Ankle + D	AT	EE	2 h	190 + DS
32	Male	Right	U to ankle + D	PT	EE	1 and half	276
38	Male	Right	Entire leg	AT	E to E	2	456
17	Male	Left	C + L	PT	EE	1.5	264
35	Male	Right	knee and U	Lateral genicular artery	EE	2	392
28	Male	Right	U + C + L + D	AT	EE	2.5	960
40	Male	Right	U + C + L	AT	EE	1.5	512
35	Male	Right	U + C + L	AT	EE	2	330

SA: Serratus anterior, PT: Posterior tibial, EE: End to end, AT: Anterior tibial; U – Upper 1/3rd of leg; C- middle 1/3rd of leg; L-lower1/3rd of leg; D-dorsum of foot; P-plantar aspect of foot; Desc genicular art- descending genicular artery. DS- Dead space

repaired. The patient can have difficulty in getting up from lying down position in the initial post-operative period.^[11] Hence, abdominal wall weakness due to loss of rectus abdominis muscle is a drawback of using VRAM flap.

In comparison, the disability (donor site morbidity) following combined harvest of LD and SA is minimal, as there are muscles which compensate for their loss.^[6,12]

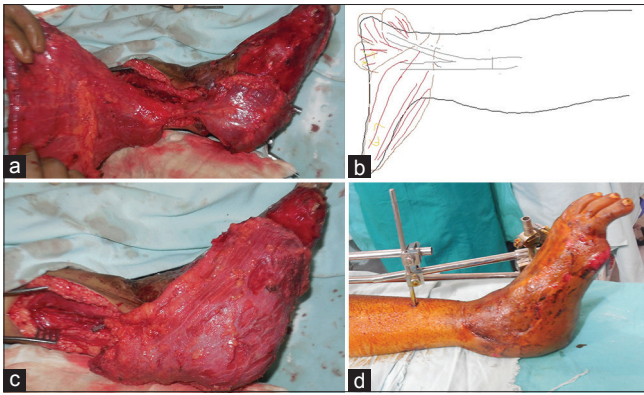


Figure 6: (a) Serratus anterior flap placed on the heel. (b) Line diagram showing use of serratus anterior to surface heel defect and latissimus dorsi for rest of the defect. (c) Heel defect covered by serratus anterior. Rest of the defect was covered by latissimus dorsi. Overlap of latissimus dorsi over serratus anterior was done during inset. (d) One-month post-operative picture

No significantly increased shoulder dysfunction in patients undergoing chimeric LD + SA.^[3,13-15] Even in our case series, we have found that only one patient had winging of scapula, and she did not have any functional disability or complaints either. Only on specific examination was the winging noticed. No other patient had winging or any other deformity related to LD + SA harvest. This finding corresponds with various other studies as referenced above.

Boomerang-extended rectus abdominis myocutaneous flap, described by Koul *et al.*, is a large flap for coverage of extensive lower limb defects. It has been described as the longest possible flap for wound coverage as free flap. Its limitation being the ability to cover long, narrow defects and not broad defects.^[16] In comparison, the LD + SA flap can cover both long defects and wide ones.

Although DIEP provides a large volume of skin and fatty tissue, zone IV has classically been unreliable^[3] and redundant fat tissue makes the flap bulky and less useful for foot coverage^[3,8]

LD flap has a large surface area, is simple to harvest and its loss has minimal functional effect in an otherwise healthy patient.^[4] However, some trauma patients have defects too large for LD and also cavities created by bone and muscle loss that cannot be filled by LD alone.

Even though LD is a large muscle, it is at times difficult to use single muscle to cover an entire defect. Even if the size of the defect is same as LD muscle area, the location and shape of defect determine how the flap can be inset. The shape of LD muscle is such that it is narrower proximally, closer to its pedicle and broader as

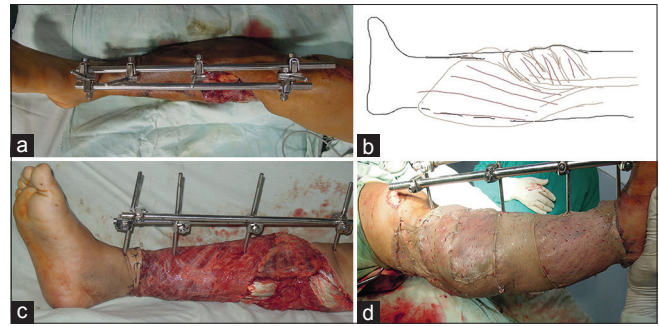


Figure 7: (a) Defect involving upper 1/3rd with degloved non-viable skin till the ankle. Degloved skin was debrided. The defect is broad proximally. (b) Line diagram showing use of serratus anterior to cover broader proximal part of defect. (c) Picture showing serratus anterior covering broad proximal part and remainder covered by latissimus dorsi flap. (d) Flap skin grafted

it progresses distally. Hence, when LD is used to resurface defects in the leg which are broad proximally, the entire defect is not covered by LD. In such situations, the area left out is covered by SA muscle [Figure 7].

Use of chimeric LD + SA flap increases the surface area that can be covered. A chimeric flap is defined as a flap with 2 or more components with separate blood supply connected to a common pedicle.^[17] SA can be used to fill in cavity defects, while LD can be used to surface large wound area [Figure 5], different anatomical locations in the lower limb can be covered by these two muscles [Figure 6]. In a long defect on the leg, anastomosis can be performed in a plane separate from the zone of trauma, in the middle of the defect, instead of going proximal to the defect itself. The two muscle components being on either side of anastomosis can provide complete wound coverage [Figure 4].

The pedicle involved is the same for both LD and SA being the thoracodorsal pedicle from the subscapular artery system. Single anastomosis is required, whereas double anastomosis would be required if two separate flaps were used or if supercharging was to be done in a large flap. By leaving behind upper 3 slips of the SA, winging of scapula is avoided^[4] and hence no donor site deficit occurs. Freedom of inset increases with the use of LD + SA flap as the two muscles can be inset independent of each other.^[18]

Review of literature revealed few case series involving LD + SA for lower limb reconstruction. Kim *et al.* reported a series of 12 patients with the use of thoracodorsal pedicle-based chimeric flaps, out of which SA was used in 3 patients,^[3] to fill dead space.

Chimeric flaps based on the subscapular artery system have also been reported to be used in oral malignancy reconstruction,^[13] and thoracic cavity reconstruction following tumour resection^[19] using similar principle of filling dead space.

Use of combined LD + SA free flap for coverage of ankle defect has been described, with SA being used to fill the dead space and LD to cover the surface defect.^[20] Similar approach has been used by us in 10 defects having dead space.

We have found LD + SA free flap to be a very useful tool in providing cover for extensive lower limb defects. LD is a type V muscle and SA type III.^[21] The chimeric flap is very reliable due to large calibre vessels and long pedicle.^[22] The choice of recipient vessels depends on the location of defect, vascular status of the limb, status of the vessels, presence of backflow.^[23] In case of end-to-side anastomosis, posterior tibial artery is to be preferred.^[24] The arterial anastomosis can be performed either end-to-end or end-to-side to one of the main lower extremity vessels (anterior tibial or posterior tibial).^[25] All or vessel anastomosis were end-to-end.

The possible disadvantage is the bulk of the flap, especially in the ankle and dorsum of foot reconstruction. This can be troublesome in some patients and requires debulking at a later stage. Thinning is done by scraping off the skin graft, debulking and regrafting the flap. It is done if the patient desires the same due to excess bulk. Aesthetically, fasciocutaneous flap is better than muscle flap in the lower limb coverage.^[25]

CONCLUSION

LD + SA free tissue transfer is an effective, reliable method of providing cover to extensive lower limb traumatic defects with minimal donor site morbidity, with added freedom of inset and flap positioning. The specific advantages of LD + SA have been noted in patients having wide proximal defect and patients having dead space that needs to be filled apart from a large surface wound.

Declaration of patient consent

The authors certify that they have obtained all appropriate patient consent forms. In the form the patient(s) has/have given his/her/their consent for his/her/their images and other clinical information to be reported in the journal. The patients understand that their names and initials will

not be published and due efforts will be made to conceal their identity, but anonymity cannot be guaranteed.

Financial support and sponsorship

Nil.

Conflicts of interest

There are no conflicts of interest.

REFERENCES

- Gururaj G. Road traffic deaths, injuries and disabilities in India: Current scenario. *Natl Med J India* 2008;21:14-20.
- Wong CH, Ong YS, Wei FC. The anterolateral thigh – Vastus lateralis conjoint flap for complex defects of the lower limb. *J Plast Reconstr Aesthet Surg* 2012;65:235-9.
- Kim SW, Youn S, Kim JD, Kim JT, Hwang KT, Kim YH, *et al.* Reconstruction of extensive lower limb defects with thoracodorsal axis chimeric flaps. *Plast Reconstr Surg* 2013;132:470-9.
- Serafin D, editor. The latissimus dorsi muscle-musculocutaneous flap. *Atlas of Microsurgical Tissue Transplantation*. 1st ed. United States of America: W.B. Saunders; 1996. p. 205-20.
- Serafin D, editor. The serratus anterior muscle-musculocutaneous flap. In: *Atlas of Microsurgical Tissue Transplantation*. 1st ed. United States of America: W.B. Saunders; 1990. p. 191-204.
- Collini FJ, Wood MB. The use of combined latissimus serratus free flap for soft tissue coverage in hand. *Eur J Plast Surg* 1989;12:179-82.
- Musharrafieh R, Macari G, Hayek S, Elhassan B, Atiyeh B. Rectus abdominis free-tissue transfer in lower extremity reconstruction: Review of 40 cases. *J Reconstr Microsurg* 2000;16:341-5.
- Zeltzer AA, Van Landuyt K. Reconstruction of a massive lower limb soft-tissue defect by giant free DIEAP flap. *J Plast Reconstr Aesthet Surg* 2012;65:e42-5.
- Hallock GG. The combined parascapular fasciocutaneous and latissimus dorsi muscle conjoined free flap. *Plast Reconstr Surg* 2008;121:101-7.
- Chao AH, Coriddi M, Miller MJ. Reconstruction of extensive defects with combined transverse-vertical rectus abdominis (cruciate) myocutaneous flaps. *Plast Reconstr Surg* 2014;133:442e-3e.
- Dinner MI, Labandter H, Dowden RV. Rectus abdominis musculocutaneous flap. In: Strauch B, Vasconez L, Hall-Findlay EJ, Lee BT, editors. *Grabb's Encyclopedia of Flaps*. 1st ed. Boston Toronto London: Little, Brown and Company; 1990. p. 1370-2.
- Podrecca S, Tomic O, Salvatori P, Riggio E. Free composite osseomyocutaneous flap of latissimus dorsi, serratus anterior and rib for oromandibular recon. *Eur J Plast Surg* 2000;23:316-20.
- Girod A, Nadaud F, Mosseri V, Jouffroy T, Rodriguez J. Use of chimeric subscapular artery system free flaps for soft-tissue reconstruction of the oral cavity and oropharynx: Advantages and donor-site morbidity. *Plast Reconstr Surg* 2009;124:445e-6e.
- Harii K, Yamada A, Ishihara K, Miki Y, Itoh M. A free transfer of both latissimus dorsi and serratus anterior flaps with thoracodorsal vessel anastomosis. *Plast Reconstr Surg* 1982;70:620-9.
- Takayanagi S, Ohtsuka M, Tsukie T. Use of the latissimus dorsi and the serratus anterior muscles as a combined flap. *Ann Plast Surg* 1988;20:333-9.
- Koul AR, Nahar S, Prabhu J, Kale SM, Kumar PH. Free

- Boomerang-Shaped Extended Rectus Abdominis Myocutaneous flap: The longest possible skin/myocutaneous free flap for soft tissue reconstruction of extremities. *Indian J Plast Surg* 2011;44:396-404.
17. Hallock GG. The complete nomenclature for combined perforator flaps. *Plast Reconstr Surg* 2011;127:1720-9.
 18. Rausky J, Binder JP, Mazouz-Dorval S, Hamou C, Revol M. Perforator-based chimaeric thoracodorsal flap for foot reconstruction. *J Plast Reconstr Aesthet Surg* 2013;66:1798-800.
 19. Hussain ON, Sabbagh MD, Carlsen BT. Complex microsurgical reconstruction after tumor resection in the trunk and extremities. *Clin Plast Surg* 2017;44:299-311.
 20. Kiyokawa K, Tanaka S, Kiduka Y, Inoue Y, Yamauchi T, Tai Y, *et al.* Reconstruction of the form and function of lateral malleolus and ankle joint. *J Reconstr Microsurg* 2005;21:371-6.
 21. Mathes SJ, Hansen SL. Flap classification and its application. In: Mathes SJ, Hentz VR, editors. *Plastic Surgery*. 2nd ed., Vol. 1. United States of America: Saunders; 2006. p. 373-5.
 22. Germann G, Bickert B, Steinau HU, Wagner H, Sauerbier M. Versatility and reliability of combined flaps of the subscapular system. *Plast Reconstr Surg* 1999;103:1386-99.
 23. Park S, Han SH, Lee TJ. Algorithm for recipient vessel selection in free tissue transfer to the lower extremity. *Plast Reconstr Surg* 1999;103:1937-48.
 24. Karşıdağ S, Akçal A, Turgut G, Uğurlu K, Baş L. Lower extremity soft tissue reconstruction with free flap based on subscapular artery. *Acta Orthop Traumatol Turc* 2011;45:100-8.
 25. Soltanian H, Garcia RM, Hollenbeck ST. Current concepts in lower extremity reconstruction. *Plast Reconstr Surg* 2015;136:815e-29e.