

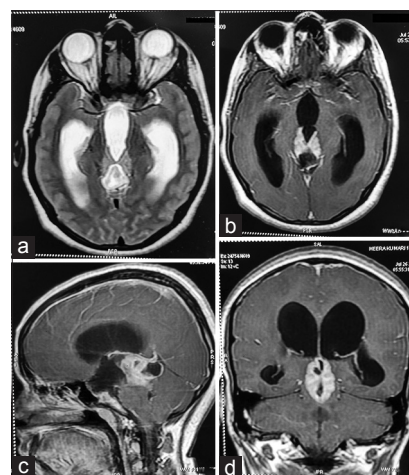
## Papillary Tumor of the Pineal Region in an Adolescent

Sir,

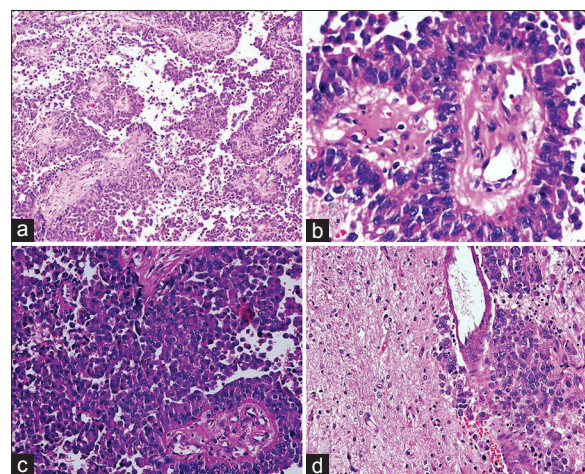
Primary papillary tumors of the central nervous system and particularly the pineal region are rare. Papillary tumor of the pineal region (PTPR) was initially described by Jouvét *et al.* in 2003.<sup>[1]</sup> This entity was introduced in the World Health Organization (WHO) classification of brain tumors in 2007, following which it is being diagnosed more frequently.<sup>[2]</sup> Less than hundred cases of PTPR have been reported in the literature so far.<sup>[3]</sup> The natural history of this tumor is not well understood due to the limited information and its rarity. Here, we present a case of PTPR in a 15-year-old adolescent.

A 15-year-old girl, with no comorbidities, had complaints of headache, nausea, vomiting, and progressive loss of vision in both eyes for 8 months. Clinical examination revealed bilateral upgaze paresis, bilateral papilledema, and bilateral visual acuity of 6/24. Systemic examination was noncontributory. Contrast-enhanced magnetic resonance imaging revealed an enhancing soft-tissue mass (1.9 cm × 2.1 cm × 2.5 cm) in posterior aspect of the third ventricle extending into the cerebral aqueduct bulging into the roof of the fourth ventricle leading to obstructive hydrocephalus [Figure 1]. Then, she underwent near total excision of mass with placement of ventriculoperitoneal shunt. Histopathology suggested papillary tumor of the pineal region (the WHO Grade II/III) [Figure 2]. Tumor cells were immunopositive for chromogranin (diffuse), focally for synaptophysin, and showed faint immunoreactivity for cytokeratin while negative for epithelial membrane antigen (EMA), glial fibrillary acidic protein, and neurofilament. MIB-1 labeling index was low [Figure 3]. She was then administered adjuvant radiation dose of 50.4 Gy in 28 fractions over 5 weeks and 3 days to residual tumor.

PTPR is a rare tumor with limited available information on it. As its name implies, PTPR does not arise from the pineal gland itself. The cell of origin is thought to be the specialized ependymocytes of the subcommissural organ.<sup>[4]</sup> The evolution in the classification of pineal tumors has led to the emergence of PTPR. Based on a series of six tumors with identical histological features, PTPR was first described as a distinct entity in 2003.<sup>[1]</sup> The WHO 2007 definition of PTPR is as follows: "A rare neuroepithelial tumor of the pineal region in adults, characterized by papillary architecture and epithelial cytology, immunopositivity for cytokeratin, and ultrastructural features suggesting ependymal differentiation."<sup>[2]</sup> To date, there are <100 cases reported in the literature.<sup>[3]</sup> PTPR generally presents with symptoms of obstructive hydrocephalus secondary to compression of cerebral aqueduct such as headache,

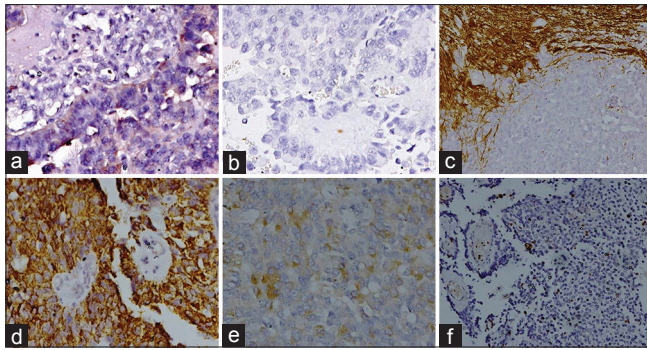


**Figure 1:** Magnetic resonance imaging brain showing hypertense tumor in (a) T2 axial view, (b) T1 axial view, (c) T1 sagittal view, and (d) T1 coronal view at posterior aspect of the third ventricle with obstructive hydrocephalus



**Figure 2:** Moderately cellular tumor displaying neoplastic papillae (a) (H and E, ×100). Nuclei round-to-oval, stippled chromatin, and mild-to-moderate degree of nuclear atypia (b) (H and E, ×400). Sheet-like areas and vessels showing pseudoangiomatous morphology (c) (H and E, ×200). Tumor infiltrating adjacent brain parenchyma (d) (H and E, ×200)

vomiting, and visual disturbances.<sup>[1]</sup> Similarly, in this case, she presented with features of raised intracranial tension. No specific imaging features are pathognomonic for PTPR. However, intrinsic T1 hyperintensity has been reported as a potentially characteristic feature of this neoplasm.<sup>[5]</sup> The subcommissural organ is involved in the secretion of glycopeptides and is located below the posterior commissure at the level of the cerebral aqueduct, just anterior to the pineal gland. It is the glycopeptide content that is thought to be the source of intrinsic T1 hyperintensity commonly reported in PTPR.<sup>[5]</sup> Neuroimaging usually displays a large (2–4 cm),



**Figure 3:** Immunohistochemistry showing faint immunopositivity for cytokeratin (a) ( $\times 400$ ). Immunonegative for epithelial membrane antigen (b) ( $\times 400$ ). Immunonegative for glial fibrillary acidic protein while adjacent brain parenchyma showing immunopositivity for glial fibrillary acidic protein (c) ( $\times 400$ ). Strongly immunopositive for chromogranin (d) ( $\times 400$ ). Faint immunopositivity for synaptophysin (e) ( $\times 400$ ). Low MIB-1 LI ( $<4\%$ ) (f) ( $\times 400$ )

well-circumscribed contrast-enhancing tumor, which occasionally has cystic elements.<sup>[4]</sup> The limited MR imaging reports of PTPRs in the literature have described a heterogeneously enhancing mass in the pineal region.<sup>[1]</sup> The present case shows similar features to cases in the literature. Histopathologically, PTPR is characterized by an epithelial-like growth pattern in which the vessels are covered with multiple layers of tumor cells forming perivascular pseudorosettes, similar to our case.<sup>[6]</sup> Immunoreactivity for cytokeratin in the papillary structures is most distinctive feature and absent dot-like EMA staining in these tumors rules out ependymomas. Faint and focal reactivity for neuroendocrine markers are described, however, in the present case, we found diffuse immunoreactivity for chromogranin and focally for synaptophysin.<sup>[7]</sup> The prognosis of PTPR is uncertain. These tumors are characterized by frequent local recurrence, and thus, the literature currently suggests they may be graded either II or III but complete criteria for grading are not yet formulated.<sup>[7]</sup> In a series of 31 cases reviewed by Fèvre-Montange *et al.*, progression was identified in 72% of cases, with 5-year estimates of overall and progression-free survival set at 73% and 27%, respectively. Incomplete resection and a mitotic index higher than five per 10 high-power fields were correlated with decreased survival and increased recurrence. Gross total resection was the only clinical factor strongly associated with overall survival and recurrence, but the results were not statistically significant.<sup>[8]</sup> Due to the few reported cases of PTPR, there are no current standard treatment options beyond gross total resection, although complete resection is not possible in most of the times, hence, surgical resection followed by radiotherapy is the preferred treatment.<sup>[9]</sup>

Although PTPR is a rare tumor, it is being recognized more commonly nowadays due to the awareness of neuropathologists and should be considered in the differential diagnoses of tumors of the pineal region.

More studies with larger patient population are required to determine the prognosis and standard treatment protocol of this rare entity. As of now, maximal safe resection followed by adjuvant radiation should be considered owing to high recurrence rate.

### Declaration of patient consent

The authors certify that they have obtained all appropriate patient consent forms. In the form the patient(s) has/have given his/her/their consent for his/her/their images and other clinical information to be reported in the journal. The patients understand that their names and initials will not be published and due efforts will be made to conceal their identity, but anonymity cannot be guaranteed.

### Financial support and sponsorship

Nil.

### Conflicts of interest

There are no conflicts of interest.

**Rituparna Biswas, Kalpana Kumari<sup>1</sup>,  
K P Hareesh, Subhash Gupta, Anirban Halder<sup>2</sup>,  
G K Rath**

Department of Radiation Oncology, Dr. B. R. A. IRCH, All India Institute of Medical Sciences, <sup>1</sup>Department of Pathology, All India Institute of Medical Sciences, <sup>2</sup>Department of Radiation Oncology, VMHC and Safdarjung Hospital, New Delhi, India

### Address for correspondence:

Dr. Subhash Gupta,  
Department of Radiation Oncology, Dr. B. R. A. IRCH,  
All India Institute of Medical Sciences, New Delhi, India.  
E-mail: drsubhash\_oncologist@yahoo.in

### References

- Jouvet A, Fauchon F, Liberski P, Saint-Pierre G, Didier-Bazes M, Heitzmann A, *et al.* Papillary tumor of the pineal region. *Am J Surg Pathol* 2003;27:505-12.
- Louis DN, Ohgaki H, Wiestler OD, Cavenee WK, Burger PC, Jouvet A, *et al.* The 2007 WHO classification of tumours of the central nervous system. *Acta Neuropathol* 2007;114:97-109.
- Patil M, Karandikar M. Papillary tumor of pineal region: A rare entity. *Asian J Neurosurg* 2016;11:453.
- Chang AH, Fuller GN, Debnam JM, Karis JP, Coons SW, Ross JS, *et al.* MR imaging of papillary tumor of the pineal region. *AJNR Am J Neuroradiol* 2008;29:187-9.
- Kim YH, Kim JW, Park CK, Kim DG, Sohn CH, Chang KH, *et al.* Papillary tumor of pineal region presenting with leptomeningeal seeding. *Neuropathology* 2010;30:654-60.
- Kawahara I, Tokunaga Y, Yagi N, Iseki M, Abe K, Hayashi T, *et al.* Papillary tumor of the pineal region. *Neurol Med Chir (Tokyo)* 2007;47:568-71.
- Jouvet A, Nakazato Y, Scheithauer BW, Paulus W. Papillary tumour of the pineal region. In: Louis D, Ohgaki H, Wiestler O, Cavenee W, editors. *World Health Organization Classification of Tumours of the Central Nervous System*. Geneva, Switzerland: International Agency for Research on Cancer; 2007. p. 128-9.
- Fèvre-Montange M, Hasselblatt M, Figarella-Branger D, Chauveinc L, Champier J, Saint-Pierre G, *et al.* Prognosis and histopathologic features in papillary tumors of the pineal region:

A retrospective multicenter study of 31 cases. J Neuropathol Exp Neurol 2006;65:1004-11.

9. Kaloshi G, Rroji A, Lame A, Leka L, Haxhihyseni E, Vreto G, *et al.* Natural history of papillary tumor of the pineal region: New insights on biological explanation. J Neurooncol 2010;100:487-8.

This is an open access journal, and articles are distributed under the terms of the Creative Commons Attribution-NonCommercial-ShareAlike 4.0 License, which allows others to remix, tweak, and build upon the work non-commercially, as long as appropriate credit is given and the new creations are licensed under the identical terms.

Access this article online	
<b>Quick Response Code:</b> 	<b>Website:</b> <a href="http://www.ijmpo.org">www.ijmpo.org</a>
	<b>DOI:</b> 10.4103/ijmpo.ijmpo_251_17

**How to cite this article:** Biswas R, Kumari K, Haresh KP, Gupta S, Halder A, Rath GK. Papillary tumor of the pineal region in an adolescent. Indian J Med Paediatr Oncol 2019;40:S199-201.

© 2019 Indian Journal of Medical and Paediatric Oncology | Published by Wolters Kluwer - Medknow