

## Case Report

## Angiomatous Granuloma Mimicking Verruciform lesion

## Abstract

Angiomatous granuloma also called as pyogenic granuloma (PG) is a benign soft-tissue tumor of the skin and mucous membrane arising in response to various stimuli such as local irritation, traumatic injury, or hormonal factors. PGs show a striking predilection for the gingiva. Extragingivally, it can be seen in areas of frequent trauma. It predominantly occurs in the second decade of life and is more common in females than males due to vascular effects of female hormones; here, we present a unique case in a 4-year-old female patient with a gingival growth mimicking a verrucous hyperplasia which is very rare in that age.

**Keywords:** Angiomatous, granuloma, lobular capillary hemangioma, pyogenic

## Introduction

Pyogenic granuloma (PG), also known as granuloma pyogenicum, is a common tumor like growth of oral cavity or skin that is considered to be nonneoplastic in nature. The term PG or granuloma pyogenicum was introduced by Hartzell in 1904. In the oral cavity, PGs show a striking predilection for the gingiva, with interdental papillae being the most common site in 70% of the cases.<sup>[1]</sup>

There are two kinds of PG, namely, lobular capillary hemangioma (LCH) and non-LCH.<sup>[2]</sup> They are more common in the maxillary anterior area than any other area in the mouth.<sup>[3]</sup> Poor oral hygiene, dental plaque and calculus, dental appliances, or overhanging restorations may be the precipitating factors in many cases. Extragingivally, it can be seen in areas of frequent trauma such as the lower lip, tongue, and palate.<sup>[4]</sup> Surgical excision is the treatment of choice for PG.<sup>[5]</sup>

## Case Report

A 4-year-old female patient came with a complaint of growth in the lower back tooth region of lower jaw for 1 week. Parents of the patient noticed the growth a week back which was smaller in size initially which increased suddenly to the present size. Growth was not associated with pain or any other symptoms initially but later developed discomfort while eating

associated with mild pain. The patient was given anti-inflammatory medication for the relief of pain and swelling for about 3 days, but there was no reduction in size of the growth. Medical and family histories were noncontributory. On extraoral examination, fullness is seen on the left lower third of face. A solitary left submandibular lymph node enlargement is felt, which is freely movable and tender. Intraorally, an exophytic growth was seen arising from gingiva in relation to 73, 74, and 75 tooth region [Figure 1] measured approximately around size 2 cm × 3 cm, slight pale in color with pinpoint erythematous areas. This appeared to be covered by keratotic surface and seemed to have papillary projections. On palpation, the lesion was pedunculated fibrous inconsistency, nontender, and slight bleeding on provocation, and diascopy test was negative. Considering the patient's history and clinical examination, a provisional differential diagnosis was arrived which is as follows PG, verrucous hyperplasia, hemangioma, peripheral giant-cell granuloma, peripheral ossifying fibroma, fibroma, and peripheral odontogenic fibroma. The following sets of radiographs were advised to rule out any bony involvement. Intraoral periapical radiograph (IOPA) and occlusal radiographs showed soft-tissue shadow with respect to 73, 74, and 75 [Figures 2 and 3]. Later, complete blood picture was done which did not show any variations from the normal limits. The lesion was subjected for

**Harsha Bhayya,**  
**Avinash Tejasvi,**  
**Pavani Donempudi<sup>1</sup>,**  
**Geetha**  
**Paramkusam,**  
**Swetha Kardalkar<sup>2</sup>**

*Department of Oral Medicine and Radiology, Kamineni*

*Institute of Dental Sciences, Nalgonda, Telangana,*

<sup>1</sup>*Department of Oral Medicine and Radiology, Shri. Yashwanth Rao Chavan Memorial Medical and Rural Development Foundation's Dental College, Ahmednagar, Maharashtra,*

<sup>2</sup>*Department of Dentistry, Belagavi Institute of Medical Sciences, Belgaum, Karnataka, India*

## Address for correspondence:

Dr. Harsha Bhayya,  
Department of Oral Medicine and Radiology, Kamineni Institute of Dental Sciences, Nalgonda, Telangana, India.  
E-mail: dr.sbhayya@gmail.com

## Access this article online

Website: [www.ijmpo.org](http://www.ijmpo.org)

DOI: 10.4103/ijmpo.ijmpo\_198\_17

## Quick Response Code:



**How to cite this article:** Bhayya H, Tejasvi A, Donempudi P, Paramkusam G, Kardalkar S. Angiomatous granuloma mimicking verruciform lesion. Indian J Med Paediatr Oncol 2019;40:S145-7.

This is an open access journal, and articles are distributed under the terms of the Creative Commons Attribution-NonCommercial-ShareAlike 4.0 License, which allows others to remix, tweak, and build upon the work non-commercially, as long as appropriate credit is given and the new creations are licensed under the identical terms.

For reprints contact: [reprints@medknow.com](mailto:reprints@medknow.com)

excisional biopsy under local anesthesia [Figures 4 and 5] and subjected to histopathological examination which revealed to be angiomatous granuloma [Figures 6 and 7]. The patient was followed up for 1 year after surgery and there was no evidence of recurrence.

## Discussion

Hullihen's description in 1844 was most likely the first PG reported in English literature, but the term “pyogenic granuloma” or “granuloma pyogenicum” was introduced by Hartzell in 1904.<sup>[6]</sup> The incidence of PG is 19.76%–25% of all reactive lesions.<sup>[7]</sup> Although it has been reported in all age groups, higher frequency of PG is observed in the second decade of life, especially among women, probably because of the vascular effects of female hormones.<sup>[8]</sup> In the pediatric age group, this tumor occurs most frequently in early childhood. The present case was in a 4-year-old female patient in early childhood, where at this age group, PG is very rare and makes the report unique. PG of the gingiva develops in up to 5% of pregnancies. Clinically, PGs usually present as painless, soft in consistency, pedunculated or sessile, smooth, or lobulated surface red-to-purple masses.

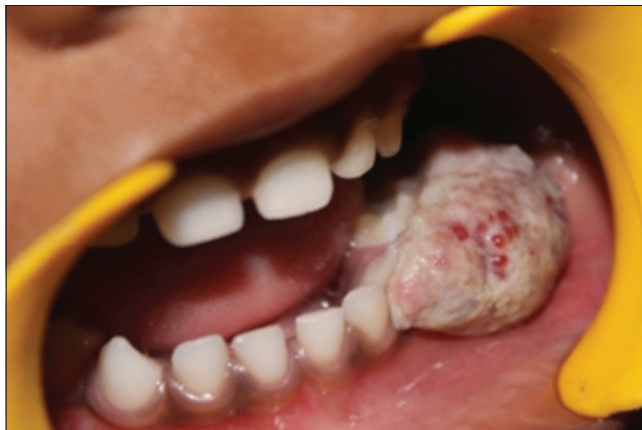

Figure 1: Exophytic growth was seen arising from gingiva in relation to 73, 74, and 75 tooth region

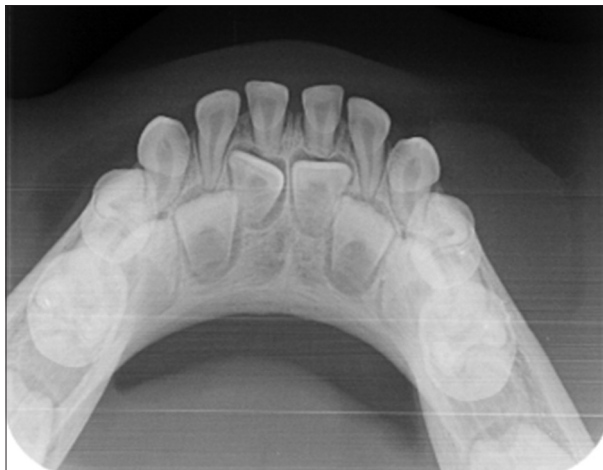

Figure 3: Occlusal radiograph showing soft-tissue shadow in relation to 73, 74, and 75

LCH most commonly appears as sessile lesion whereas non-LCH PG appears as pedunculated lesions. The lesion commonly ulcerates and bleeds profusely. It varies in size from a few millimeters to several centimeters and rarely exceeds 2.5 cm. The consistency of the lesion gets firmer both with aging of the lesion and removal of its etiological factors. Surgical excision is the treatment of choice for PG. Although these are reactive hyperplasias, they have a relatively high recurrence rate of 16% after simple excision, whereas recurrences after surgery of extrajingival PGs are, however, uncommon. Elimination of the causative agent is required. Radiographic findings are absent in PG. However, Angelopoulos AP in his review observed that localized alveolar bone resorption in rare instances of large and long-standing gingival tumors can be seen,<sup>[9]</sup> but in our reported case, mild interdental vertical bone loss was observed and associated with a soft-tissue shadows of the gingival overgrowth on IOPA and occlusal radiographs on the affected side.

Vilman *et al.* observed that gingival cases show a much higher recurrence rate than lesions from other oral mucosal sites.<sup>[10]</sup> Sapp *et al.* stated that oral PGs have a relatively high rate of recurrence after simple excision. If the patient is pregnant, recurrence is common. Recurrence after surgery in extrajingival sites is uncommon.<sup>[11]</sup> The present reported case was followed up for 1 year with no incidence of recurrence.

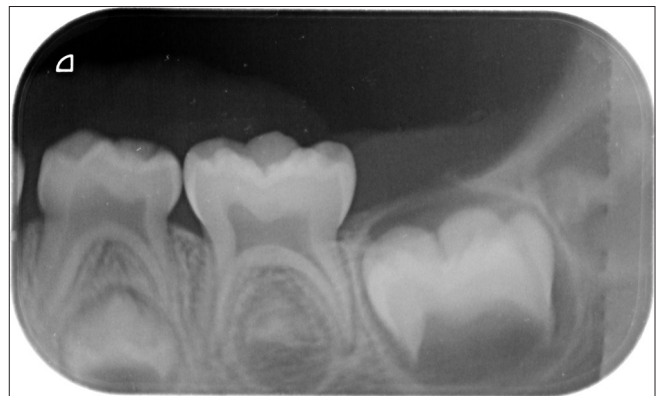

Figure 2: Intraoral periapical radiograph showing soft-tissue shadow in relation to 74 and 75

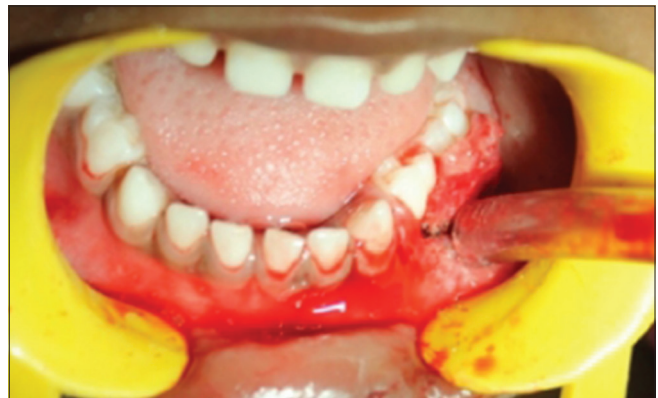

Figure 4: Postoperative surgical excision site



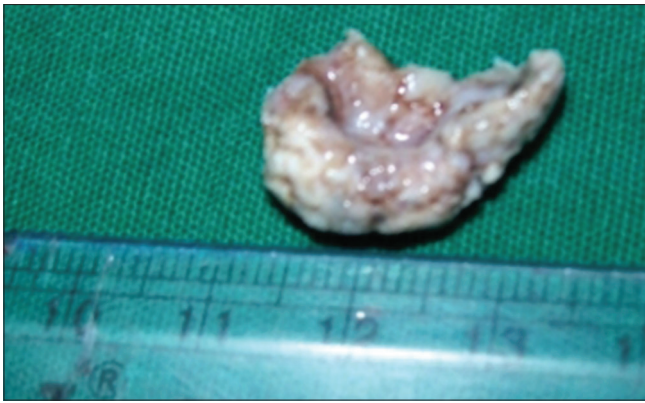

Figure 5: Excised surgical specimen

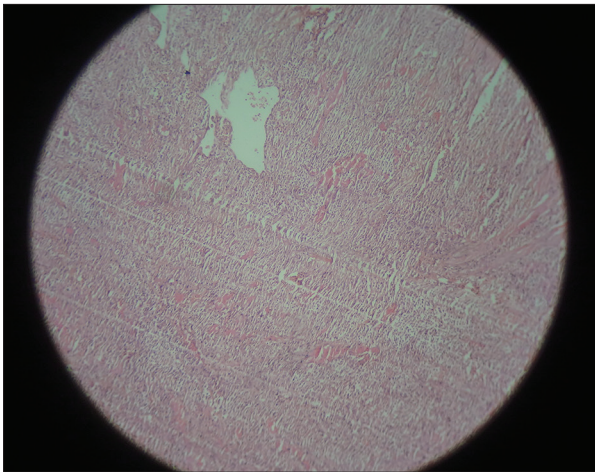


Figure 6: Low-power (×10) histopathological section showing numerous hemorrhagic areas and blood vessels in the connective tissue

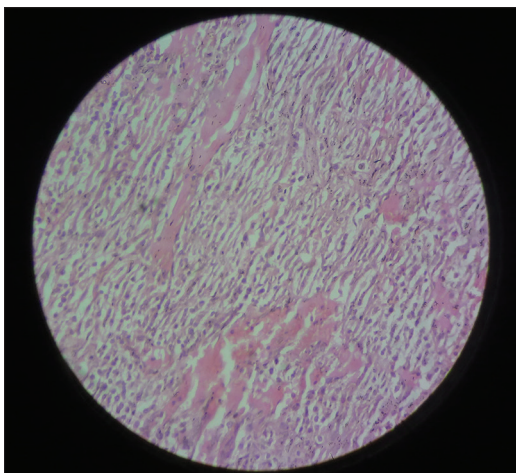


Figure 7: High-power (×40) histopathological section showing hemorrhagic areas in the connective tissue

Differential diagnosis of PG includes peripheral giant-cell granuloma, peripheral ossifying fibroma, fibroma, peripheral odontogenic fibroma, hemangioma, conventional granulation tissue, hyperplastic gingival inflammation, Kaposi's sarcoma, bacillary angiomatosis, angiosarcoma, and non-Hodgkin's lymphoma.<sup>[12]</sup>

## Conclusion

Peripheral gingival growth on the gingival areas presents a diagnostic challenge to the oral physician due to the diverse group of pathologies. Gingival growths may represent a variation of normal anatomic structures, inflammation, cysts, developmental anomalies, and neoplasm. Within these lesions angiomatous granulomas, a histopathological variant of PG should always be kept in mind as a differential for reddish lesions affecting oral cavity.

## Declaration of patient consent

The authors certify that they have obtained all appropriate patient consent forms. In the form the patient(s) has/have given his/her/their consent for his/her/their images and other clinical information to be reported in the journal. The patients understand that their names and initials will not be published and due efforts will be made to conceal their identity, but anonymity cannot be guaranteed.

## Financial support and sponsorship

Nil.

## Conflicts of interest

There are no conflicts of interest.

## References

1. Amirchaghmaghi M, Falaki F, Mohtasham N, Mozafari PM. Extralingival pyogenic granuloma: A case report. *Cases J* 2008;1:371.
2. Epivatianos A, Antoniadis D, Zaraboukas T, Zairi E, Pouloupoulos A, Kiziridou A, *et al.* Pyogenic granuloma of the oral cavity: Comparative study of its clinicopathological and immunohistochemical features. *Pathol Int* 2005;55:391-7.
3. Patil K, Mahima VG, Lahari K. Extralingival pyogenic granuloma. *Indian J Dent Res* 2006;17:199-202.
4. Das UM, Azher U. Peripheral ossifying fibroma. *J Indian Soc Pedod Prev Dent* 2009;27:49-51.
5. Eversole LR. Benign tumours of the oral cavity. In: Greenberg MS, Glick M, editors. *Burket's Oral Medicine Diagnosis and treatment*. 10<sup>th</sup> ed. India: BC. Decker Inc., Elsevier; 2003. p. 141-2.
6. Jafarzadeh H, Sanatkhan M, Mohtasham N. Oral pyogenic granuloma: A review. *J Oral Sci* 2006;48:167-75.
7. Zhang W, Chen Y, An Z, Geng N, Bao D. Reactive gingival lesions: A retrospective study of 2,439 cases. *Quintessence Int* 2007;38:103-10.
8. Gonçalves ES, Damante JH, Fischer Rubira CM, Taveira LA. Pyogenic granuloma on the upper lip: An unusual location. *J Appl Oral Sci* 2010;18:538-41.
9. Angelopoulos AP. Pyogenic granuloma of the oral cavity: Statistical analysis of its clinical features. *J Oral Surg* 1971;29:840-7.
10. Vilmann A, Vilmann P, Vilmann H. Pyogenic granuloma: Evaluation of oral conditions. *Br J Oral Maxillofac Surg* 1986;24:376-82.
11. Sapp JP, Eversole LR, Wyoski GP. *Contemporary Oral and Maxillofacial Pathology*. 2<sup>nd</sup> ed. Missouri: Mosby; 1997. p. 318-22.
12. Wood NK, Goaz PW. *Differential Diagnosis of Oral and Maxillofacial Lesions*. 5<sup>th</sup> ed. Missouri: Mosby; 1998. p. 129.