

Peculiarities of Yolk Sac Tumor in Head and Neck: A Case Report and Literature Review

Abstract

Yolk sac tumor (YST) is the most common malignant germ cell tumor of head and neck region, constituting around 1% of all malignant germ cells. The rarity of the tumor has led to a relatively sparse collective description of clinical and prognostic factors of such a tumor affecting head and neck region. In this case report with review of the literature, we have highlighted certain peculiar features of YSTs affecting the head and neck region. They seem to commonly affect female children. These tumors seem to fare poorly in children of <1 year of age. Multimodality of treatment consisting of combination chemotherapy with the cisplatin-based regimen and surgery and/or radiotherapy helps in achieving long-term disease-free survival in those affected.

Keywords: Head and neck, malignant germ cell tumor, yolk sac tumor

**K Devaraja,
Kapil Sikka¹,
Pankaj Kumar
Singh²**

Department of
Otorhinolaryngology, Kasturba
Medical College, Manipal,
Karnataka, Departments of
¹Otorhinolaryngology and
²Neurosurgery, All India
Institute of Medical Sciences,
New Delhi, India

Introduction

Yolk sac tumor (YST) also known as “endodermal sinus tumor” is the most common malignant germ cell tumor involving gonads. Although rare, these tumors are also known to arise from an extragonadal site including the head and neck region. While sharing a report of a large YST of temporal region in a 3-year-old boy, we are highlighting certain peculiarities of YST in the head and neck region.

Case Report

A 3-year-old boy presented with a painless, progressive swelling in the right temporal region for the past 1 year. The swelling of 15 cm × 10 cm was involving temporal region, infratemporal fossa, and parotid region, giving the appearance of a conjoint second head as shown radiologically in Figure 1. Open biopsy from the lesion showed mixed germ cell tumor consisting of teratoma and YST. Whole-body positron emission tomography ruled out metastasis. He was given five cycles of cisplatin, bleomycin, and etoposide combination chemotherapy, for which tumor responded significantly with 90% reduction in volume as shown radiologically in Figure 2. Although the residual tumor was excised, the pathological examination of surgical

specimen did not show any residual tumor. The patient was kept under close follow-up, and he is disease free at 2 years postsurgery with serum alpha-fetoprotein levels of 0.88 ng/ml (normal range: 0.89–8.78 ng/ml) and beta-hCG levels of 1.20 mIU/ml (normal range: <5 m IU/ml).

Discussion

As per the MAKEI (Maligne Keimzelltumoren) group, the largest group to have prospectively studied the germ cell tumors of head and neck region, the YST in head and neck constitutes 1% of malignant germ cell tumors of the body.^[1] Table 1 depicts the most of the reported cases of YSTs involving head and neck region in the past 20 years.

YSTs of the head and neck appear to have a female predilection [Table 1], in contrast to the gonadal germ cell tumors which frequently involve males. With respect to the laterality, YSTs in the head and neck region frequently seems to arise on the right side similar to the gonadal germ cell tumors. From Table 1, it is clear that the YST in head and neck region is the disease of childhood. According to the MAKEI group, among all those children with head and neck germ cell tumor, there is a statistically higher chance of having malignant component (of YST) in those over the age of 1 year, as compared to those

Address for correspondence:

Dr. K Devaraja,
Department of
Otorhinolaryngology,
Kasturba Medical College,
Manipal, Karnataka, India.
E-mail: deardr@gmail.com

Access this article online

Website: www.ijmpo.org

DOI: 10.4103/ijmpo.ijmpo_135_17

Quick Response Code:



How to cite this article: Devaraja K, Sikka K, Singh PK. Peculiarities of yolk sac tumor in head and neck: A case report and literature review. Indian J Med Paediatr Oncol 2018;39:260-2.

This is an open access article distributed under the terms of the Creative Commons Attribution-NonCommercial-ShareAlike 3.0 License, which allows others to remix, tweak, and build upon the work non-commercially, as long as the author is credited and the new creations are licensed under the identical terms.

For reprints contact: reprints@medknow.com

Table 1: Reported cases of yolk sac tumors in head and neck region over the last 20 years

Author	Year	Age (years)	Sex	Site	Side	Treatment	Prognosis
Kusumakumari <i>et al.</i> ^[2]	1997	6 mn	Female	Orbit	Left	S	Progression
		1.5	Male	Palate	NA	S	NA
		1	Female	Skull base	Right	CT	Progression
Bresters <i>et al.</i> ^[3]	2003	3	Female	Sino-orbital	Right	CT + S + RT	Progression
Mishra <i>et al.</i> ^[4]	2007	59	Male	Sinonasal	Right	CT + S + RT	DF at 1 year
Kiratli <i>et al.</i> ^[5]	2008	2yr 5mn	Female	Orbit	Left	S + CT	DF at 9 years
Fujino <i>et al.</i> ^[6]	2009	4	Male	Orbit	Right	CT + S	DF at 1.5 year
Furtado <i>et al.</i> ^[7]	2011	10	Female	Thyroid	Right	CT	DF*
Zhang <i>et al.</i> ^[8]	2013	1yr 4mn	Female	Floor of mouth	Bilateral	S	Progression
Hauser <i>et al.</i> ^[9]	2013	2	Female	PPS	Left	CT + S	DF at 1 year
Arumugam <i>et al.</i> ^[10]	2016	3	Female	Skull base	Bilateral	S + CT	DF*

*Duration not available. NA – Not available; PPS – Parapharyngeal space; S – Surgical excision; CT – Chemotherapy; RT – Radiotherapy; DF – Disease-free

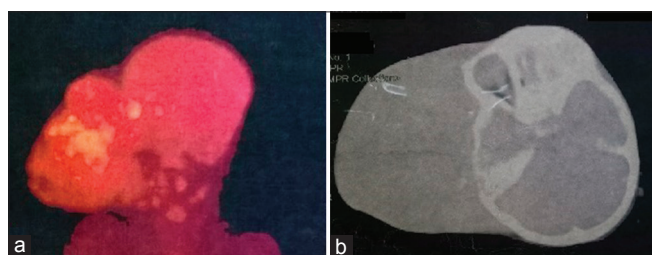


Figure 1: Pretreatment radiological images: (a) positron emission tomography and (b) plain computer tomography, both showing huge tumor giving the appearance of conjoint head

diagnosed in infancy.^[1] This peculiar observation seems to hold good even for the index case and for the majority listed in Table 1.

In general, the YSTs in head and neck are commonly found to involve sino-nasal and orbital regions [Table 1]. However, it was seen in the soft tissue of the temporal and infratemporal fossae in our case. Similar involvement of soft tissue areas like parapharyngeal space and skull base has also been described rarely in the literature.^[9,10]

In the MAKEI study group, all patients with YST except one had a favorable outcome with multimodal therapy. It is interesting to find that all children with YST in the group were over the age of 1 year, suggesting an improved survival with age. Similarly, cases in Table 1 also seem to follow the same trend. Among the three cases described by Kusumakumari, two patients who had treatment failure were actually of age <1 year.^[2] It seems that the age of diagnosis of YST influences the overall prognosis in those affected. However, this fact needs to be verified by a systematic review or meta-analysis.

Another important factor which seems to have a direct bearing on survival in YSTs of head and neck is the therapeutic regimen. Unlike for benign germ cell tumors, mere excision of the YSTs may not be adequate in achieving the cure. In fact, as it is evident from Table 1, any treatment modality for YST, which is less than multimodality

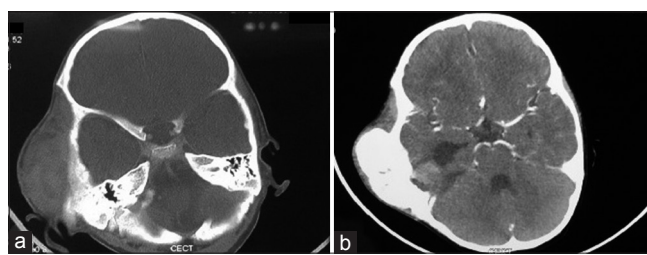


Figure 2: Postchemotherapy radiological images: (a) plain computer tomography, (b) contrast enhanced computer tomography, both demonstrating significant reduction of tumor bulk following chemotherapy

regimen, has resulted in the unfavorable outcome. The combination chemotherapy based on high-dose cisplatin along with surgical excision and/or radiotherapy seems to be the optimal treatment regimen for treating YSTs, and this has contributed to the betterment of disease-free survival rates in recent times [Table 1]. However, radiotherapy is known to be deleterious in children and might hamper their overall growth. Thus, surgery is the preferred modality in children along with combination chemotherapy consisting of cisplatin, etoposide/ifosfamide, and bleomycin.^[1] In our case, although the excised specimen did not show any residual tumor tissue, we believe that the surgical excision has helped in achieving a complete cure, by eradicating the microscopic and molecularly altered tissue. Similar results of favorable outcome have been reported in the past by excising the pathologically tumor-free primary site, after the significant remission with chemotherapy.^[9] Furthermore, there are reports of recurrence at the unattended primary sites even after dramatic response to the chemotherapy.^[3]

In summary, the YST of head and neck commonly involve children over the age of 1 year. However, it seems to be more aggressive if diagnosed in children of <1 year age. It has a predilection toward the female child, and if extra-axially located, it is commonly seen on the right side. These YSTs can be treated favorably with multimodality therapy consisting of cisplatin-based combination chemotherapy with surgery and/or radiotherapy. However, surgical excision with chemotherapy seems to be the ideal

regimen in improving survival as the radiotherapy has adverse effects on growing child, and the surgery eradicates the genetically altered tissue at the tumor bed.

Declaration of patient consent

The authors certify that they have obtained all appropriate patient consent forms. In the form the patient(s) has/have given his/her/their consent for his/her/their images and other clinical information to be reported in the journal. The patients understand that their names and initials will not be published and due efforts will be made to conceal their identity, but anonymity cannot be guaranteed.

Financial support and sponsorship

Nil.

Conflicts of interest

There are no conflicts of interest.

References

1. Bernbeck B, Schneider DT, Bernbeck B, Koch S, Teske C, Lentrod J, *et al.* Germ cell tumors of the head and neck: Report from the MAKEI study group. *Pediatr Blood Cancer* 2009;52:223-6.
2. Kusumakumari P, Geetha N, Chellam VG, Nair MK. Endodermal sinus tumors in the head and neck region. *Med Pediatr Oncol* 1997;29:303-7.
3. Bresters D, Zwaan CM, Veerman AJ, Leemans CR, Westerveld GJ, van der Linden JC, *et al.* A three-year-old girl with a yolk sac tumor in the orbit/maxillary sinus. *Med Pediatr Oncol* 2003;40:70-1.
4. Mishra A, El-Naggar AK, DeMonte F, Hanna EY. Endodermal sinus tumor of the paranasal sinuses. *Head Neck* 2008;30:539-43.
5. Kiratli H, Erkan Balci K, Güler G. Primary orbital endodermal sinus tumor (yolk sac tumor). *J AAPOS* 2008;12:623-5.
6. Fujino T, Okamura A, Hatsukawa Y, Nakayama K, Inoue M, Nakayama M, *et al.* A case of intraocular yolk sac tumor in a child and its pathogenesis. *J AAPOS* 2009;13:613-5.
7. Furtado LV, Leventaki V, Layfield LJ, Lowichik A, Muntz HR, Pysher TJ, *et al.* Yolk sac tumor of the thyroid gland: A case report. *Pediatr Dev Pathol* 2011;14:475-9.
8. Zhang Q, Huang Y, Bao CY, Li LJ. Yolk sac tumour involving floor of mouth: Case report. *Br J Oral Maxillofac Surg* 2013;51:e67-9.
9. Hauser LJ, Chiang T, Ramakrishnan VR, Lovell MA, Kelley PE. Parapharyngeal and skull base yolk sac tumor: A case report with lessons in diagnosis and management. *Int J Pediatr Otorhinolaryngol* 2014;78:2003-6.
10. Arumugam D, Thandavarayan P, Chidambaram L, Boj S, Marudasalam S. Primary nasopharyngeal yolk sac tumor: A Case report. *J Clin Diagn Res* 2016;10:ED06-7.