

## Late Recurrence of Malignant Choroidal Melanoma Mimicking Hepatocellular Carcinoma

### Abstract

Late recurrence (after more than 10 years) of choroidal melanoma, though infrequent, has been documented well in Western countries. In India, however, this disease being uncommon, there is no data regarding its late recurrence. Here, we report a case of late metastatic manifestation of choroidal melanoma in the form of liver metastases in a 45-year-old man who presented with abdominal pain; metastases to liver occurred 10 years after enucleation of the right eye.

**Keywords:** *Choroidal melanoma, India, late recurrence*

**Saphalta Baghmar,  
Dipanjan Panda,  
Chhagan Bihari,  
Shalini Thapar**

*Department of Oncology, ILBS,  
New Delhi, India*

### Introduction

Choroidal Melanoma is the most common primary intraocular malignant tumor in western countries but is rare in India. Malignant melanomas are known for their late recurrences. Most common site of recurrence is liver. But being a rare tumor, late recurrence with metastasis to liver has not been reported from India.

### Case Report

A 45-year-old man presented to us with complaints of pain in the abdomen with heaviness at right hypochondrium. Examination revealed hepatomegaly extending up to 5 cm below the right costal margin. On palpation, the liver was hard and nontender.

Ultrasonography (USG) and computed tomography scan revealed enlarged liver which measured approximately 25 cm in craniocaudal span. Multiple arterial phase enhancing heterogeneous nodular lesions showing venous washout were scattered in both lobes. Largest of these measures approximately 13 cm × 11 cm × 10 cm involving segment VIII and shows internal calcific foci. Subtle left lobar intrahepatic biliary radical prominence is noted with a simple 11 mm cyst in segment II. Furthermore, few enlarged heterogeneously enhancing periportal lymph nodes were seen. These appear to

be extrinsically compressing the common hepatic duct [Figure 1]. In view of arterial enhancement, of hypervascular metastases from occult primary, neuroendocrine tumor (NET) with liver secondaries or multifocal hepatocellular carcinoma (HCC) was the suggested differential diagnosis.

Serum tumor markers (AFP, CEA, and CA19.9) were normal. USG-guided biopsy of the lesion revealed tumor cells arranged in nodules separated by fibro-collagenous stroma. The tumor cells were round to spindle shaped and showed coarse nuclear chromatin, prominent eosinophilic nucleoli, and moderate amount of cytoplasm containing coarse granular black melanin pigment suggestive of melanoma [Figure 2].

A detailed history retrospectively revealed a history of choroidal melanoma for which enucleation was done 10 years prior.

### Discussion

Choroidal melanoma is rare in dark pigmented races and has been reported infrequently in Indian population. Its incidence was reported <0.5% in India.<sup>[1]</sup> It causes death, almost always secondary to distant metastases. Principal target organ for metastasis is liver, with almost 50% of the patients developing liver metastases up to 15 years after diagnosis.<sup>[2]</sup>

The reason behind this target organ is likely due to increased expression of c-Met, IGF-IR, and CXCR4 in Uveal

This is an open access article distributed under the terms of the Creative Commons Attribution-NonCommercial-ShareAlike 3.0 License, which allows others to remix, tweak, and build upon the work non-commercially, as long as the author is credited and the new creations are licensed under the identical terms.

For reprints contact: reprints@medknow.com

**How to cite this article:** Baghmar S, Panda D, Bihari C, Thapar S. Late recurrence of malignant choroidal melanoma mimicking hepatocellular carcinoma. *Indian J Med Paediatr Oncol* 2018;39:109-10.

**Address for correspondence:**  
Dr. Saphalta Baghmar,  
Department of Oncology,  
ILBS, Vasant Kunj,  
New Delhi - 110 070, India.  
E-mail: drsaphalta@gmail.com

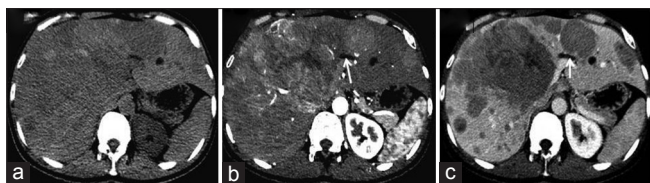Access this article online

Website: www.ijmpo.org

DOI: 10.4103/ijmpo.ijmpo\_12\_16

Quick Response Code:

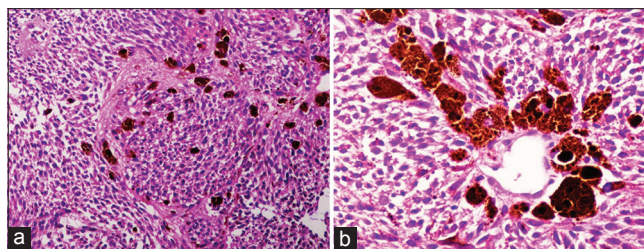




**Figure 1:** Axial images of multiphase computed tomography scan of the upper abdomen revealed multiple hypodense lesions of variable size involving both lobe of the liver (a), Which shows hyperenhancement in hepatic arterial phase (b) and washout in subsequent portal venous phase (c). One of the large central mass is having central nonenhancing area suggestive of necrosis and also causing mild dilatation of the left hepatic duct (white arrows)

Melanoma cells as compared to normal melanocytes. The liver is the only organ that highly expresses the corresponding ligands of these receptors (HGF, IGF, and CXCL12), indicating that these pathways may be highly involved in the liver-specific metastases in Uveal melanoma.<sup>[2]</sup>

As melanoma is uncommon tumor; very few late recurrences have been reported from India.<sup>[3-5]</sup> In fact, it is a lost history about previous ophthalmic intervention due to its rarity; which is why, the differential diagnosis on radiology were kept as hypervascular metastasis from unknown primary, NET or HCC; more common entities than melanoma. Choroidal melanoma is rare and masquerading that it is easily misdiagnosed. On his first visit, the patient gave a history of ophthalmic surgery, 10 years back and he was not aware of the cause and did not have histopathological report at that time. We asked for the previous histopathology report after the present biopsy suggestive of melanoma. Here, the relevance of history comes which signifies its late recurrence and thereby its prognosis. This case also highlights the requirement of long-term follow-up in melanoma patients, as the incidence of late recurrence in melanoma is 6.8% according to western literature.<sup>[6]</sup>



**Figure 2:** (a) Malignant pleomorphic cells with brownish black intracytoplasmic melanin pigment H and E, ×200. (b) Tumor cells with brownish black melanin pigment H and E, ×400

## Conclusion

This is first case report from India, highlighting a choroidal melanoma presenting with liver metastases after 10 years of enucleation.

## Financial support and sponsorship

Nil.

## Conflicts of interest

There are no conflicts of interest.

## References

1. Boyle P, Maisonneuve P, Doré JF. Epidemiology of malignant melanoma. *Br Med Bull* 1995;51:523-47.
2. Bakalian S, Marshall JC, Logan P, Faingold D, Maloney S, Di Cesare S, *et al.* Molecular pathways mediating liver metastasis in patients with uveal melanoma. *Clin Cancer Res* 2008;14:951-6.
3. Agarwal SR, Bhattacharya I, Patil YV, Amrapurkar AD. Choroidal melanoma metastasizing to the biliary system: A diagnostic dilemma. *Indian J Med Paediatr Oncol* 2009;30:138-40.
4. Gowrinath K, Geetha V. Late recurrence of malignant melanoma presenting with hemoptysis. *Lung India* 2010;27:178-80.
5. Singh P, Singh A. Choroidal melanoma. *Oman J Ophthalmol* 2012;5:3-9.
6. Faries MB, Steen S, Ye X, Sim M, Morton DL. Late recurrence in melanoma: Clinical implications of lost dormancy. *J Am Coll Surg* 2013;217:27-34.