

Comparison of International Caries Detection and Assessment System and Digital Radiographs for Detecting Occlusal Dental Caries: An *In vivo* Study

Jayachandra Reddy Bhumireddy, Ramasubbareddy Challa, Sreekanth Kumar Mallineni, Sivakumar Nuvvula

Department of Pedodontics and Preventive Dentistry, Narayana Dental College and Hospital, Nellore, Andhra Pradesh, India

Abstract

Aim: The aim of the present study was to evaluate the accuracy in the diagnosis of occlusal caries lesion using International Caries Detection and Assessment System II (ICDAS II) and digital radiographs in the primary molars. **Materials and Methods:** A total of 35 children was selected randomly and recruited for visual ICDAS II and digital bitewing radiographic examination by two independent trained examiners. A total of 249 teeth were examined at D1 (enamel caries lesions) and D3 (dentine caries lesions) thresholds. **Results:** Sensitivity at D1 for ICDAS II were 95%, and 22.97% for digital radiographs While specificity was 100% for the both tools. At D3, threshold sensitivity of ICDAS II was 94.%, whereas it was 69% for digital radiographs, while specificity was almost the same for both methods and both D1 and D3 thresholds. Excellent inter- and intra-examiner reliabilities were evident. **Conclusions:** ICDAS II is better than digital radiographs in detecting carious lesions confined to enamel, and both are equally effective in the detection of dentinal carious lesions.

Keywords: Digital radiographs, International Caries Detection and Assessment System II, occlusal caries, sensitivity, specificity

INTRODUCTION

Dental caries is a dynamic microbial disease that presents a challenge to a dentist in the initial diagnosis. Prime importance should be given to early caries detection as prior diagnosis helps in early prevention.^[1] There are various methods for caries detection which include visual, visuotactile, radiographic, fluorescence-based, and electrical conductance-based methods.^[2] More often, a dental clinician uses visuotactile and radiographic methods for caries detection in daily practice. Among visuotactile methods, conventionally, dmft/dmfs (decayed, missing and filled teeth/decayed, missing, and filled surfaces) are used to identify carious lesions, but the main limitation of dmft/dmfs index is that it detects caries only after obvious cavitation.^[3] In recent times, a new paradigm International Caries Detection and Assessment System II (ICDAS II) came into force showing promising results in early detection of caries and its activity.^[4]

Among the radiographic methods, conventional and digital radiographs are commonly employed for caries detection,^[5] but both of them have their own shortcomings. Other methods

which are useful in early caries detection do not fit into routine clinical practice since they are expensive. Nevertheless, much research is needed to support commonly used caries detection methods. Much of existing research is carried out on the permanent teeth for detecting caries by various methods, but there are few caries detection studies on primary dentition.^[2] There is an immediate need for further research in the field of caries diagnosis on primary dentition because less mineral content and thickness of enamel and dentin lead to faster caries progression.^[6] Dental caries in the primary teeth poses potential risk to its successors^[3] and also developing future space problems in the permanent dentition. A statement of fact on oral health by the WHO says that 60%–90% of schoolchildren are affected with dental caries leading to pain and discomfort.

Address for correspondence: Dr. Sreekanth Kumar Mallineni,
Department of Pedodontics and Preventive Dentistry,
Narayana Dental College and Hospital, Nellore, Andhra Pradesh, India.
E-mail: drmallineni@gmail.com

This is an open access journal, and articles are distributed under the terms of the Creative Commons Attribution-NonCommercial-ShareAlike 4.0 License, which allows others to remix, tweak, and build upon the work non-commercially, as long as appropriate credit is given and the new creations are licensed under the identical terms.

For reprints contact: reprints@medknow.com

How to cite this article: Bhumireddy JR, Challa R, Mallineni SK, Nuvvula S. Comparison of International Caries Detection and Assessment System and digital radiographs for detecting occlusal dental caries: An *In vivo* Study. *Eur J Gen Dent* 2018;7:61-5.

Access this article online

Quick Response Code:



Website:
www.ejgd.org

DOI:
10.4103/ejgd.ejgd_88_18

Occlusal caries detection and determination of lesion extension are crucial for appropriate treatment. The change in caries pattern with the use of fluorides has presented challenges in diagnosing the extension of lesion.^[7] Very few studies performed on comparison among ICDAS II and digital radiographs, and superiority of these two methods in detecting caries has not been established. Furthermore, to give a best possible evidence that could guide the students and the practitioners in the detection of carious lesions and its extension, to plan for early prevention and/or appropriate treatment and interception of disease process. Therefore, the aims and objectives of the present study were to determine the clinical performance and accuracy of ICDAS II versus digital bitewing radiography in the detection of occlusal caries in the primary teeth.

MATERIALS AND METHODS

Approval was obtained from the institutional ethics committee of Narayana Dental College and Hospital. Before proceeding to the visual examination, examiner 1 has attended an e-learning program (audio-visual aid) at <https://www.iccms-web.com>, and then, the examiner was trained according to training recommendations of the ICDAS committee.^[8] After achieving a consistent reproducibility (verified by a senior examiner 2 who was previously trained in ICDAS II), examiner 1 has carried out the study.

Selection of sample

Children who attend the outpatient section of Department of Paedodontics and Preventive Dentistry and children who attend community-based school dental health program of age 5–10 years were randomly selected for the study.

Inclusion criteria

1. Children aged 5–10 years with full set of primary dentition or mixed dentition
2. Children with increased caries risk
3. Children requiring diagnostic radiographs.

Exclusion criteria

Children aged <3years; children with permanent dentition, compromised systemic health, and uncooperative behavior; those with special health care needs, dental emergencies, and developmental anomalies of teeth; and children of parents who do not give consent were not included in the study.

Visual examination

Selected children were examined by examiner 1 followed by examiner 2 to eliminate intraexaminer bias. Type 2 examination was done as per the classification of methods of oral examination suggested by the ADA in 1970 (Examination is carried out using a plain mouth mirror and round end probe [Community Periodontal Index Treatment Needs Probe] under good illumination). Occlusal surfaces of the maxillary and mandibular primary molars were examined after thorough prophylaxis was carried out and the area to be examined is dried for 5 s.^[8,9] Then, visual ICDAS II scorings [Table 1] were recorded.

Radiographic process

For patients who require radiographic examination, informed consent was obtained from their parents. Patients for radiographic examination were selected based on the guidelines of ADA (Council on Dental Benefit Programs and Council on Scientific Affairs) and U.S. Department of Health and Human Services (Public Health Service and Food and Drug Administration) revised in 2004.

Digital bitewing radiographs were obtained with FLOW (digital sensor holder) bitewing instrument. The obtained radiographic digital images were examined on a 14-inch monitor screen (Dell Computer Corporation, Austin, TX, USA). The whole examination was carried out by two calibrated examiners in the semi-dark room and scored according to the radiographic criteria^[10] [Table 2].

Radiation protection

Both child and operator were covered with lead apron and additional protection of child with thyroid collar.

Equipment

1. X-ray machine-SATELAC X-MIND X-RAY SYSTEM (SATELAC INDIA PVT. LTD, Mumbai, India) with beam-limiting device of 31 cm long and 6 cm diameter
2. Sopro digital sensor (CCD receptor) size-1 was used to take digital bitewing radiographs

Table 1: Description of International Caries Detection and Assessment System II visual criteria

Code	Clinical criteria description
0	Sound tooth surface: no evidence of caries after prolonged air drying (5 s)
1	First visual change in enamel: opacity or discoloration (white or brown) is visible at the entrance to the pit or fissure after prolonged air drying, which is not or hardly seen on a wet surface
2	Distinct visual change in enamel: opacity or discoloration distinctly visible at the entrance to the pit and fissure when wet, lesion must still be visible when dry
3	Localized enamel breakdown due to caries with no visible dentin or underlying shadow: opacity or discoloration wider than the natural fissure/fossa when wet and after prolonged air drying
4	Underlying dark shadow from dentin=localized enamel breakdown
5	Distinct cavity with visible dentin: visual evidence of demineralization and dentin exposed
6	Extensive distinct cavity with visible dentin and more than half of the surface involved

Table 2: Radiographic criteria

Score	Radiographic criteria description
0	No radiolucency
1	Radiolucency confined to the enamel
2	Radiolucency in the outer third of the dentine
3	Radiolucency in the middle third of the dentine
4	Radiolucency reaching the pulpal third of the dentine

- Software version of digital imaging system is Sopro imaging version 1.30.113 (SOPRO® and de Gotzen, Olgiate Olona, Italy).

Exposure recommendations

The exposure recommendations were tube voltage 70 kVp, current 8 mA, and exposure time of 0.12 s for digital bitewings

Gold standard

Validation of the findings was done by examination of pit and fissure after opening fissures as a part of restorative procedure.^[11] The pit and fissure opening was carried out by a trained independent dentist who is not involved in the previous examinations. A fine carbide bur (Fissurotomy Micro NTF; SS White, Lakewood, NJ, USA) was used and looked for signs of caries, using codes given by Heinrich-Weltzien et al.^[12] Depending on the depth and extent of the cavity after careful caries removal, the examiner restored the tooth with glass ionomer cement (Fuji Type IX). Fissure opening codes are as follows:

- B0 - No caries seen
- B1 - Caries detected, confined to enamel
- B2 - Caries detected, extended into dentin.

Statistical methods

Intraclass correlation coefficient (ICC) with 95% confidence interval was used to determine the interexaminer reproducibility initially by considering all scores of ICDAS and radiographic methods. The interexaminer reliability was calculated using Cohen's kappa test. All analyses were carried out using statistical software SPSS statistics version 20 (IBM, Armonk, New York), and the level of significance was $P < 0.05$.

Diagnostic performance of each method was evaluated using parameters such as sensitivity, specificity, negative predictive value, positive predictive value, and accuracy at two different thresholds, D1 (all caries lesions) and D3 (dentine caries lesions). Accuracy was defined as the percentage of correct diagnosis in all samples (sound and decayed surfaces). For ICDAS and radiographic methods, Score 1 represented the cut-off point for all lesions (D1 threshold) and Score 2 for lesions in dentine (D3 threshold). The McNemar test was employed to compare sensitivity, specificity, and accuracy values of the different methods. The level of significance for the McNemar test was $P < 0.05$. The study design has been shown in flowchart [Figure 1].

RESULTS

Of 40 children selected for study, 35 were finally included. The mean age of the children was 9.05 years. A total of 31 teeth were excluded from study due to the following reasons: grossly decayed, root stumps, missing due to extraction, and early loss of primary with successor present. Finally, 249 teeth are available for the analysis. At D1 threshold (lesions limited to enamel), the ICDAS II showed significantly higher sensitivity (95%) and accuracy than the digital radiographic method (22%), while no significant differences were found in specificity [Table 3]. The results were statistically significant ($P < 0.05$). At D3 threshold (dental caries), no significant

differences were found for specificity when comparing ICDAS II and radiographic evaluation [Table 4], but ICDAS II showed higher sensitivity (94%) while 69% for digital radiographs ($P < 0.05$). The specificity scores for both ICDAS II and digital radiographs were almost the same and the results were statistically significant ($P < 0.05$). Kappa and ICC values were similar for all methods of caries diagnosis and inter- and intra-examiner reliabilities excellent scores [Table 5].

DISCUSSION

Visual and radiographic methods are still commonly employed for caries detection clinically. Although various new methods such as laser fluorescence and electric conductance have received paramount importance in research, their use in clinical practice has not received much attention, especially in developing countries due to high cost. Digital radiographic methods have been introduced as an adjuvant tool for dental caries detection with some advantages over conventional radiography.^[7] However, in the pediatric dentistry, this method has not been fully employed for caries detection despite the advantages this method could offer.^[2] Apart from lesion detection, knowing the extension of lesion in dental tissues is critical for the selection of restorative material and success of treatment performed. All the current methods are tested *in vitro* but not *in vivo*, which

Table 3: Diagnostic accuracy at D1 threshold (enamel) for International Caries Detection and Assessment System II and digital radiographs

Criteria	ICDAS II (n=249)	Digital radiograph (n=249)
True positive	46	11
False positive	0	0
True negative	201	201
False negative	2	37
Sensitivity (%)	95.83	22.92
Specificity (%)	100.0	100.0
Positive predictive value (%)	100.0	100.0
Negative predictive value (%)	99.01	84.45
Accuracy (%)	99.19	85.14

ICDAS – International Caries Detection and Assessment System

Table 4: Diagnostic accuracy at D3 threshold (dentin) for International Caries Detection and Assessment System II and digital radiographs

Criteria	ICDAS (n=249)	Digital radiograph (n=249)
True positive	49	36
False positive	5	2
True negative	192	195
False negative	3	16
Sensitivity (%)	94.23	69.23
Specificity (%)	97.46	98.98
Positive predictive value (%)	90.74	94.74
Negative predictive value (%)	98.46	92.42
Accuracy (%)	96.79	92.77

ICDAS – International Caries Detection and Assessment System

is crucial for generalizability of research findings.^[7] Moreover, the available literature regarding occlusal caries detection in primary teeth is limited.^[2] Hence, we evaluated the accuracy of direct digital radiography compared to ICDAS to uncover the extension of occlusal carious lesions in primary molars.

Considering the sensitivity and specificity, this study showed that the direct digital radiography has a considerable accuracy in caries detection. ICDAS was more accurate than digital radiographic method for enamel occlusal carious lesions in the primary molars. This finding may be biased because of operative reference standard, but still the roughness/cavitation of enamel surface perceived by tactile sensation of two examiners with CPI probe, good sample from our population, and exclusion of lesions coded 1 or 2 are considered as factors that reduce bias significantly. For dentinal caries lesions, digital radiography had less sensitivity and good specificity compared to visual inspection. Hence, digital bitewing radiographs form good adjuncts to visual ICDAS II.

Although radiovisiography used in this study proved its accuracy in dentinal caries detection, the rigid sensor posed problems in positioning, especially in the anterior region of oral cavity. This has resulted in exclusion of some children from sample and missing of mandibular canine/its distal surface in the image. Such errors may lead to reexposure and ultimately increase in radiation dose^[13] to young children. Hence, the future studies should test the acceptance and image acquisition by various sensor sizes and other digital systems in children of various age groups as children are dynamic in the perspective of growth and development, i.e., size of oral cavity varies with age, position of dentoalveolar apparatus, size of tongue, and depth of palatal vault. The reference standard used in this study is operative evaluation, which is not a gold standard such as histological sectioning and observation of sections with transverse microradiography or polarized light microscope or stereomicroscope. All these methods are suitable only *in vitro* and not *in vivo*. True validation of caries detection methods measuring lesion extent or stage should be done clinically where the real disease occurs.^[14] Such validation may be tested with an operating microscope or surgical loupes as they can provide fine details of dental tissues. The distribution of the disease in the sample should reflect the distribution in the population in which the diagnostic method will be used.^[15] If it does not, calculated values for sensitivity and specificity may be either underestimated or overestimated in the target population. Underestimation falls out when the sample contains too many “borderline” cases and overestimation when too many “obvious” cases are included.^[16,17] The distribution of enamel and dentin lesions in our sample is 48 and 52, respectively, of 249 teeth evaluated. Hence, the disease distribution in our sample represents the real nature unlike the extracted teeth sampled in *in vitro* studies which may contain more obvious lesions.

It is already known that general dental practitioners worldwide have switched from conventional film radiography to digital imaging.^[13] Theoretically, the main advantages of digital

Table 5: Cohen’s kappa value of inter- and intra-examiner repeatability for both diagnostic methods (95% confidence interval)

Method	Interexaminer	Intraexaminer A	Intraexaminer B
ICDAS II	0.892	0.971	0.942
Digital radiograph	0.982	0.931	0.944

ICDAS – International Caries Detection and Assessment System; *P*<0.01; Significant

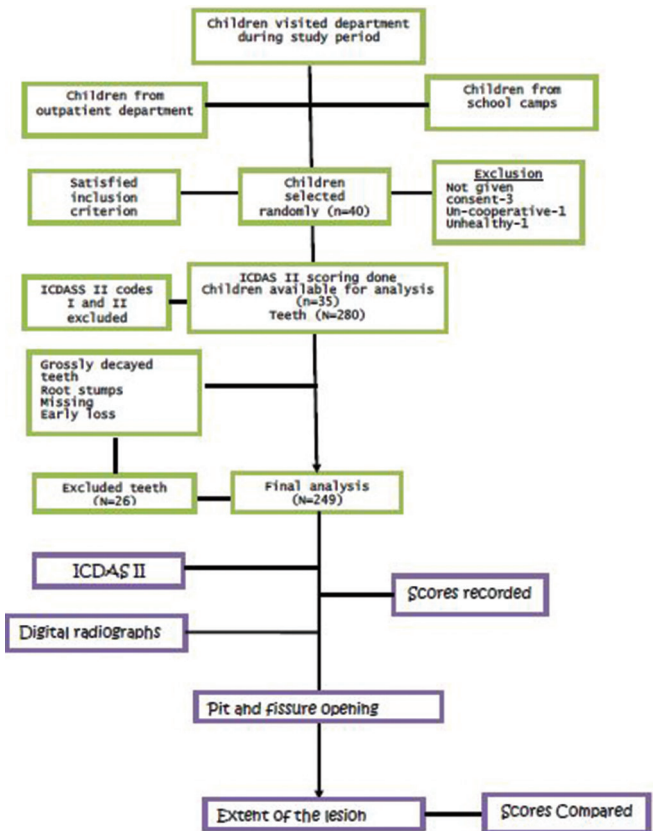


Figure 1: Flowchart of study design

intraoral radiography systems are fewer errors in the image and fewer environmental problems since there is no use of chemicals. They also save time and reduce dose to the patient because the receptors are more sensitive to radiation.^[18] These advantages are noteworthy when dealing with children, especially working with a dynamic digital image in impatient children.^[6] Although the dynamics of digital imaging appear to be appreciated by dentists and dental students, only a tiny part of the image enhancement facilities are actually used.^[13] Most recently, Nuvvula *et al.*^[19] stated that it is very important to perform *in vivo* studies to know accuracy of diagnostic methods in detection of carious lesions. Prior studies looked at the effect of image enhancement on diagnostic accuracy.^[19-23] Some enhancement procedures resulted in higher accuracy in the processed rather than the original images.^[19,20] On the other hand, others reported no effect on diagnostic accuracy^[21,22] or a negative effect^[23] (lower accuracy) for the detection of dentinal lesions. Based on this controversy,

we decided to work with unmodified digital images in the present study. Moreover, prior study by Babu *et al.*^[24] found that 65% of prevalence of dental caries in their study population from the same area that of the present study was performed. Therefore, the present study results may improve diagnostic accuracy and the importance of ICDAS II and the role of digital radiographs in diagnosis and treatment options. Nevertheless, the accuracy of the prevalence of dental caries in prior study is uncertain. Hence, the authors opine that the use of ICDAS II in prevalence studies play a vital role and prevalence studies recommended. Additional studies are needed to investigate the differences that can be observed when examining digital image enhancement in the primary teeth radiographs.

CONCLUSIONS

ICDAS II is as effective as digital radiography for the detection of occlusal caries involving dentin. ICDAS II is better at detecting initial enamel caries lesions than radiographic methods. Whenever possible, digital radiography should be considered for the detection of carious lesions in primary teeth in the light of environmental concerns and dose reduction.

Financial support and sponsorship

Nil.

Conflicts of interest

There are no conflicts of interest.

REFERENCES

- Gomez J, Tellez M, Pretty IA, Ellwood RP, Ismail AI. Non-cavitated carious lesions detection methods: A systematic review. *Community Dent Oral Epidemiol* 2013;41:54-66.
- Bader JD, Shugars DA, Bonito AJ. Systematic reviews of selected dental caries diagnostic and management methods. *J Dent Educ* 2001;65:960-8.
- Honkala E, Runnel R, Honkala S, Olak J, Vahlberg T, Saag M, *et al.* Measuring dental caries in the mixed dentition by ICDAS. *Int J Dent* 2011;2011:150424.
- Shivakumar K, Prasad S, Chandu G. International caries detection and assessment system: A new paradigm in detection of dental caries. *J Conserv Dent* 2009;12:10-6.
- Jablonski-Momeni A, Stucke J, Steinberg T, Heinzel-Gutenbrunner M. Use of ICDAS-II, fluorescence-based methods, and radiography in detection and treatment decision of occlusal caries lesions: An *in vitro* study. *Int J Dent* 2012;2012:371595.
- Dias da Silva PR, Martins Marques M, Steagall W Jr., Medeiros Mendes F, Lascala CA. Accuracy of direct digital radiography for detecting occlusal caries in primary teeth compared with conventional radiography and visual inspection: An *in vitro* study. *Dentomaxillofac Radiol* 2010;39:362-7.
- Pretty IA. Caries detection and diagnosis: Novel technologies. *J Dent* 2006;34:727-39.
- International Caries Detection and Assessment System. Coordinating Committee, Appendix, Criteria Manual. International Caries Detection and Assessment System; 12-14 March, 2005.
- Ismail AI, Sohn W, Tellez M, Amaya A, Sen A, Hasson H, *et al.* The international caries detection and assessment system (ICDAS): An integrated system for measuring dental caries. *Community Dent Oral Epidemiol* 2007;35:170-8.
- Dunkley S, Ashley P. Use of a ranked scoring system to detect occlusal caries in primary molars. *Int J Paediatr Dent* 2007;17:267-73.
- Chu CH, Lo EC, You DS. Clinical diagnosis of fissure caries with conventional and laser-induced fluorescence techniques. *Lasers Med Sci* 2010;25:355-62.
- Heinrich-Weltzien R, Weerheijm KL, Kühnisch J, Oehme T, Stösser L. Clinical evaluation of visual, radiographic, and laser fluorescence methods for detection of occlusal caries. *ASDC J Dent Child* 2002;69:127-32, 123.
- Wenzel A. A review of dentists' use of digital radiography and caries diagnosis with digital systems. *Dentomaxillofac Radiol* 2006;35:307-14.
- Huysmans MC, Longbottom C. The challenges of validating diagnostic methods and selecting appropriate gold standards. *J Dent Res* 2004;83:C48-52.
- ten Bosch JJ, Angmar-Månsson B. Characterization and validation of diagnostic methods. *Monogr Oral Sci* 2000;17:174-89.
- Lussi A. Impact of including or excluding cavitated lesions when evaluating methods for the diagnosis of occlusal caries. *Caries Res* 1996;30:389-93.
- Vaarkamp J, ten Bosch JJ, Verdonschot EH, Bronkhorst EM. The real performance of bitewing radiography and fiber-optic transillumination in approximal caries diagnosis. *J Dent Res* 2000;79:1747-51.
- van der Stelt PF. Better imaging: The advantages of digital radiography. *J Am Dent Assoc* 2008;139:7S-13S.
- Nuvvula S, Bhumireddy JR, Kamatham R, Mallineni SK. Diagnostic accuracy of direct digital radiography and conventional radiography for proximal caries detection in primary teeth: A systematic review. *J Indian Soc Pedod Prev Dent* 2016;34:300-5.
- Li G, Yoshiura K, Welander U, Shi XQ, McDavid WD. Detection of approximal caries in digital radiographs before and after correction for attenuation and visual response. An *in vitro* study. *Dentomaxillofac Radiol* 2002;31:113-6.
- Møystad A, Svanaes DB, van der Stelt PF, Grondahl HG, Wenzel A, van Ginkel FC, *et al.* Comparison of standard and task-specific enhancement of Digora storage phosphor images for approximal caries diagnosis. *Dentomaxillofac Radiol* 2003;32:390-6.
- Kositbowornchai S, Basiw M, Promwang Y, Moragorn H, Sooksuntisakoonchai N. Accuracy of diagnosing occlusal caries using enhanced digital images. *Dentomaxillofac Radiol* 2004;33:236-40.
- Koob A, Sanden E, Hassfeld S, Staehle HJ, Eickholz P. Effect of digital filtering on the measurement of the depth of proximal caries under different exposure conditions. *Am J Dent* 2004;17:388-93.
- Babu MS, Nirmala SV, Sivakumar N. Oral hygiene status of 7-12-year-old school children in rural and urban population of Nellore district. *J Indian Assoc Public Health Dent* 2011;18:1075-80.

Staying in touch with the journal

1) Table of Contents (TOC) email alert

Receive an email alert containing the TOC when a new complete issue of the journal is made available online. To register for TOC alerts go to www.ejgd.org/signup.asp.

2) RSS feeds

Really Simple Syndication (RSS) helps you to get alerts on new publication right on your desktop without going to the journal's website. You need a software (e.g. RSSReader, Feed Demon, FeedReader, My Yahoo!, NewsGator and NewzCrawler) to get advantage of this tool. RSS feeds can also be read through FireFox or Microsoft Outlook 2007. Once any of these small (and mostly free) software is installed, add www.ejgd.org/rssfeed.asp as one of the feeds.