

# Assessment of Root Canal Morphology of Mandibular Incisors Using Cone-Beam Computed Tomography among Residents of Al-Madinah Al-Munawara Region, Saudi Arabia

Hani M. Ghabbani, Asma A. Marghalani, Hala R. Alabiri<sup>1</sup>

Department of Restorative Dentistry, College of Dentistry, Taibah University, Madinah, <sup>1</sup>Department of Endodontics, Faculty of Dentistry, King AbdulAziz University, Jeddah, Saudi Arabia

## Abstract

**Objectives:** This study investigates the root configuration and prevalence of multiple canals in mandibular incisors among a Saudi subpopulation in the Al-Madinah Al-Munawara region using cone-beam computed tomography (CBCT). **Materials and Methods:** The study included imaging data from 929 CBCT scans. All scans were obtained using a CBCT device (Carestream SM 749, Rochester, NY, USA). Each scan was analyzed in two orthogonal planes (axial and sagittal) to explore information regarding tooth identification, the number of roots, and the internal morphology of the mandibular incisors. Vertucci's classification was used to categorize the canal configuration of the mandibular incisors. **Statistical Analysis:** Data interpretation was performed using SPSS software. Chi-square and one-way analysis of variance tests were applied for data analysis ( $P < 0.05$ ). **Results:** Five hundred and twenty-three CBCT scans were excluded according to the set criteria. A total of 1624 mandibular incisors were inspected from 406 CBCT scans. In females, 275 (64.8%) teeth showed Type I configurations, and 125 (29.4%) showed Type III configurations. In males, 563 (46.9%) teeth showed Type III configurations, and 543 (45.2%) showed Type I configurations. In terms of the number of roots, all samples showed single-rooted mandibular incisors. **Conclusion:** All participants' mandibular incisors had single roots with a high incidence of single-canal configurations. The root canal configuration of the majority of lower incisors showed bilateral symmetry.

**Keywords:** Anatomical variation, mandibular incisors, Vertucci's classification

## INTRODUCTION

A fundamental understanding of internal anatomy, common variations in teeth, and visibility during treatment are essential for successful endodontic treatment.<sup>[1-3]</sup> A lack of basic knowledge may lead to various procedural errors, such as missed canals, inadequate cleaning and shaping, and improper obturation, ultimately resulting in endodontic treatment failure.<sup>[4,5]</sup>

In 1984, Vertucci investigated the complexity of the internal canal system and suggested eight pulp space configurations.<sup>[6]</sup> Various techniques have been explored to inspect the internal anatomy of teeth, such as the teeth staining and clearing technique,<sup>[7-12]</sup> radiograph,<sup>[1]</sup> and computed tomography.<sup>[13-15]</sup>

However, each technique has its own limitations. For instance, the gold standard staining and clearing technique and the transverse cross-section technique are invasive and can only

be used for *in vitro* studies.<sup>[2,16]</sup> While conventional periapical radiographs are considered to have beneficial diagnostic value in the detection of internal canal anatomy in clinical situations, this method can cause distortion and superimposition of the root by adjacent structures due to its use of two-dimensional (2D) projections of 3D objects.<sup>[2,17]</sup> With advances in technology, cone-beam computed tomography (CBCT) provides a 3D image of the teeth and surrounding structure in three orthogonal

**Address for correspondence:** Dr. Hani M. Ghabbani, Department of Restorative Dentistry, College of Dentistry, Taibah University, P. O. Box 344, Al-Madinah Al-Munawara, Saudi Arabia. E-mail: hghabbani@taibahu.edu.sa

This is an open access journal, and articles are distributed under the terms of the Creative Commons Attribution-NonCommercial-ShareAlike 4.0 License, which allows others to remix, tweak, and build upon the work non-commercially, as long as appropriate credit is given and the new creations are licensed under the identical terms.

**For reprints contact:** reprints@medknow.com

**How to cite this article:** Ghabbani HM, Marghalani AA, Alabiri HR. Assessment of root canal morphology of mandibular incisors using cone-beam computed tomography among residents of Al-Madinah Al-Munawara Region, Saudi Arabia. *Eur J Gen Dent* 2020;9:40-4.

**Received:** 03<sup>rd</sup> September, 2019 **Revision:** 04<sup>th</sup> October, 2019

**Accepted:** 05<sup>th</sup> November, 2019 **Publication:** 02<sup>nd</sup> January, 2020

### Access this article online

Quick Response Code:



Website:  
www.ejgd.org

DOI:  
10.4103/ejgd.ejgd\_141\_19

planes: axial, coronal, and sagittal. CBCT is considered to be as accurate as the modified teeth staining and clearing technique in the investigation of root canal configurations.<sup>[16]</sup> The main advantages of CBCT are that it produces less radiation, noninvasive, and provides high-quality images, and provides high-quality images.<sup>[2,18]</sup>

Vertucci reported the occurrence of a single canal with one apex in 70% of lower central incisors and 75% of lower lateral incisors,<sup>[6]</sup> and Miyashita *et al.* found that 87.6% of lower incisors had a single canal extended from the pulp chamber to the apical foramen.<sup>[10]</sup> Green also found that 79% of 500 mandibular incisors had a single canal with one apical foramen.<sup>[19]</sup> Previous studies have suggested a broad range of variations in the canal configuration of mandibular incisors among various populations. Previously, Al-Fouzan *et al.* used the teeth staining and clearing technique to investigate the prevalence of two or more canals in lower incisors among a Saudi subpopulation from the Riyadh community.<sup>[20]</sup> However, there are no published articles reporting the canal configuration of mandibular incisors among the residents of the Al-Madinah Al-Munawara region in Saudi Arabia. Therefore, the aim of this study is to investigate the root canal morphology and prevalence of multiple canals in mandibular incisors among residents of this region. In addition, we used Vertucci's classification to determine the configuration of the root canals in the mandibular incisors.

## MATERIALS AND METHODS

This cross-sectional study analyzed the CBCT data of residents of Al-Madinah Al-Munawara, Saudi Arabia. This study was approved by the Institutional Research Ethics Committee at the College of Dentistry, Taibah University (Ref# 20171206). The present study included the retrospective CBCT data of 929 patients (628 males, 301 females) who attended the Taibah University College of Dentistry between January 2013 and December 2017. The patients' ages ranged from 20 to 80 years. Mandibular incisors were selected for further examination based on the following criteria: fully developed roots with closed apices, no signs of calcification, root resorption, and periapical lesions. Patients with missing mandibular incisors, endodontically treated incisors, or restored incisors were excluded from the study.

The present study obtained CBCT data using the CS 9300 PREMIUM 3D (Carestream, Rochester, NY, USA), operated

at set parameters of 73 KV and 12 mA and exposure times ranging from 8 to 20 s according to the segment taken, with a voxel size of 0.3 mm. Two experienced dentists reviewed the CBCT imaging data independently using Blue Sky Plan<sup>®</sup> computer software for viewing images version 4.3.7 (64 bit). In case of any disagreement, the third researcher (an endodontist) was consulted to reach the final consensus. CBCT data were examined in two orthogonal planes (axial and sagittal) to determine the number of roots and the canal configuration types using Vertucci's classification, as shown in Figure 1.<sup>[6,21]</sup> After the data collection and completion of the investigation, Chi-square and one-way analysis of variance tests were applied using the Statistical Package for the Social Sciences (IBM<sup>®</sup>, Chicago, USA), with  $P < 0.05$ .

## RESULTS

Based on the selection criteria, 523 CBCT scans were excluded, as several CBCTs focused on the implant site or the lesion area or were poor in quality. Furthermore, several cases had some of the four lower incisor teeth missing, which are crucial to measuring the symmetry between the right and left sides. From CBCT data of 406 patients, a total of 1624 mandibular incisors were further investigated to detect the canal configurations using Vertucci's classification, as shown in Table 1. Overall, Type I was the most frequent configuration, followed by Type III, as shown in Figures 2 and 3. In the lower central incisors, Type I was found in 401 (24.6%) teeth, followed by Type III in 351 (21.5%) teeth. In the lower lateral incisors, Type I was found in 417 (25.6%) teeth and Type III was found in 337 (20.6%) teeth. Forty (2.4%) lower central incisors and 47 (7.1%) lower lateral incisors showed Type V, as shown in Figure 4. Types IV and VII were found less frequently in the current study. Other types of Vertucci's classifications (II, VI, and VIII) were not detected in the mandibular incisors.

The CBCTs included 300 males and 106 females; Types I and III were observed in 275 (64.8%) and 125 (29.4%) teeth, respectively, among females. In male patients, 563 (46.9%) mandibular incisors showed Type III configurations, followed by 543 (45.2%) showing Type I, as shown in Table 2. This diversity could be attributed to the difference in the male (73.9%)-to-female (26.1%) ratio in the sample. In terms of ethnicity, Type I was the most common type detected in Saudi and non-Saudi populations, followed by Types

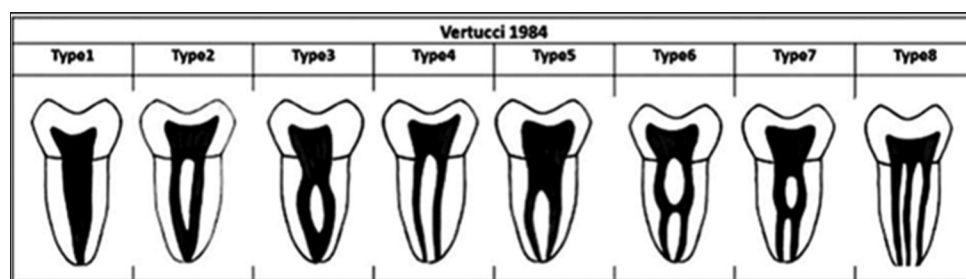
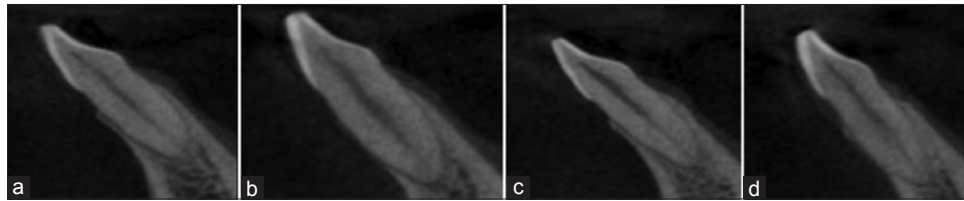
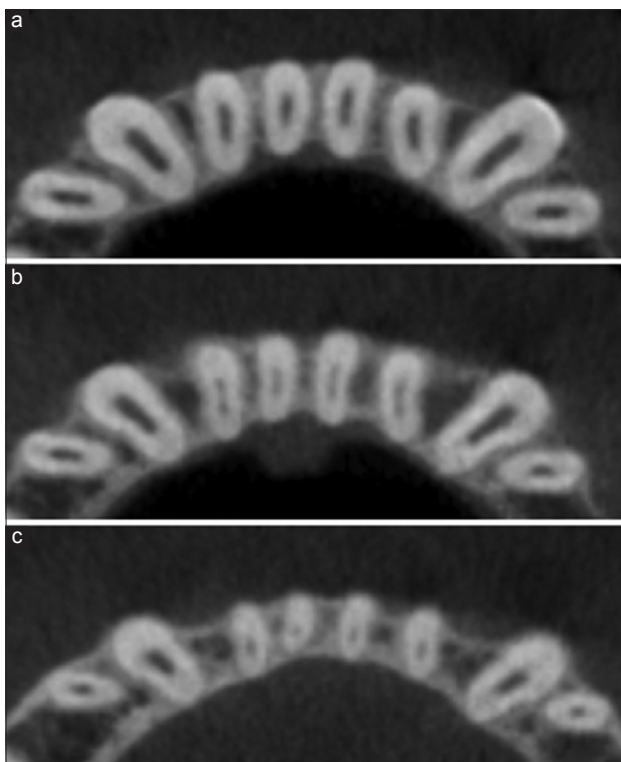


Figure 1: Vertucci's Classifications of root canal morphology

**Table 1: Types of root canal configurations of mandibular incisors according to Vertucci's classification**

Type	Left mandibular lateral incisor (32), n (%)	Left mandibular central incisor (31), n (%)	Right mandibular central incisor (41), n (%)	Right mandibular lateral incisor (42), n (%)	Total, n (%)
I	210 (12.9)	199 (12.2)	202 (12.4)	207 (12.7)	818 (50.3)
II	0	0	0	0	0
III	167 (10.2)	177 (10.8)	174 (10.7)	170 (10.4)	688 (42.3)
IV	1 (0.06)	1 (0.06)	1 (0.06)	1 (0.06)	4 (0.2)
V	23 (5.7)	20 (1.2)	20 (1.2)	24 (1.4)	87 (5.3)
VI	0	0	0	0	0
VII	5 (1.4)	9 (0.5)	9 (0.5)	4 (0.2)	27 (1.6)
VIII	0	0	0	0	0

**Figure 2:** Represents Type I canal configuration (one canal extends from the pulp chamber to the apex) (a: 32, b: 31, c: 41, d: 42)**Figure 3:** Type III canal configuration (one canal extends from the pulp chamber then separate into two canals then join and end as one canal at the apex) (a-c: Sequence of pictures coronally to apically, respectively)

III, V, and VII. Type IV was found less often in non-Saudi residents compared to Saudi nationals, but the difference was insignificant, as shown in Table 3. In terms of the number of roots, all mandibular incisors (100%) were single rooted with variable internal root canal morphologies. When comparing the right and left mandibular incisors, most patients (98.8%) showed symmetrical and identical root canal morphologies,

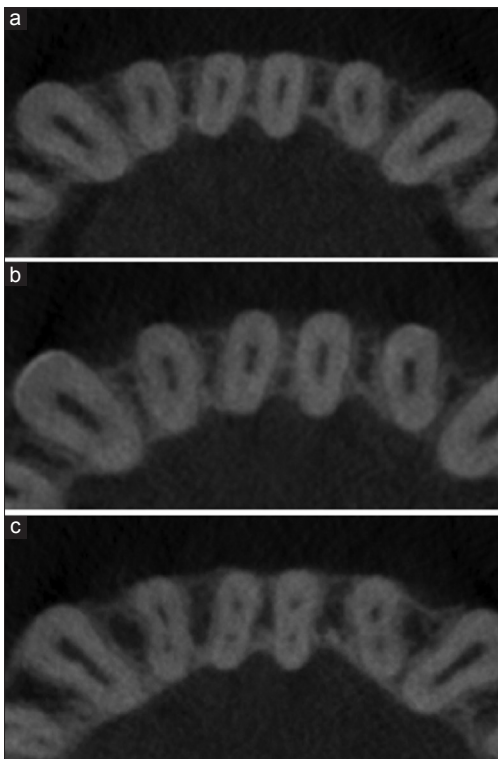
with only five (1.2%) CBCT images showing differences in the type of canal morphology between the right and left mandibular incisors.

## DISCUSSION

The present study investigated root morphology and used Vertucci's classification to report the incidence of various root canal morphologies in mandibular incisors among residents of the Al-Madinah Al-Munawara region in Saudi Arabia. We analyzed the retrospective CBCT imaging data of patients attending the Outpatient and Diagnostic Department at Taibah University Dental Hospital (TUDH) in Al-Madinah Al-Munawara. TUDH is one of the leading dental centers in the Western province that provides CBCT scans for patients in Al-Madinah Al-Munawara and the surrounding areas. In addition, several private dental centers use referral services to request CBCT scans of their patients for diagnostic and treatment planning purposes. CBCT is more precise than conventional radiography for identifying root canals<sup>[22]</sup> and has been widely used to identify the canals' morphologies in various populations.<sup>[17,21,23]</sup>

We observed the incidence of multiple canals in 806 (49.4%) mandibular incisors and 510 (31.2%), of which were of Saudi nationals and 296 (18.2%) of which were of non-Saudi residents. Such differences are attributed to ethnic and racial factors and diversity in the sample size between the Saudi and non-Saudi populations. According to the Vertucci's classification, the present study reported Type I as the most frequent configuration among central incisors (47.3%) and lateral incisors (50.2%), followed by Type III in central incisors (45.7%) and lateral incisors (42.5%), with Types V, VII, and IV being reported least frequently. These results are in agreement with Al-Fouzan *et al.*, who examined 40 central

and 40 lateral incisors using the teeth staining and clearing technique and reported a similar finding within the Saudi community in Riyadh.<sup>[20]</sup> Furthermore, similar findings have been reported in various populations, including Chinese,<sup>[23]</sup> Changqing,<sup>[2]</sup> and Israeli populations.<sup>[24]</sup> Thota *et al.* used the teeth staining and clearing technique in a Nellore population and reported a similar finding regarding central incisors.<sup>[25]</sup> Singh and Pawar<sup>[26]</sup> and Kamtane and Ghodke<sup>[27]</sup> investigated lower incisors' morphologies among Indian populations using the teeth staining and clearing technique and CBCT, respectively. Both studies agreed that Types I, II, and III were the most common morphologies in lower incisors.



**Figure 4:** Type V canal configuration (one canal extends from the pulp chamber then separate into two canals and end as two canals at the apex) (a-c: sequence of pictures coronally to apically, respectively)

In terms of the number of roots, all mandibular incisors (100%) exhibited a single-rooted configuration in the present study. These findings affirmed previous studies conducted on various populations.<sup>[20,23,26,27]</sup> Controversially, Zhengyan *et al.* reported the occurrence of two roots (0.3%) of the mandibular lateral incisors among residents of Changqing, China.<sup>[2]</sup> These findings suggest that the occurrence of mandibular incisors with two or more roots is rare. However, root canal morphologies may be widely variable, and endodontists must look for additional canals in mandibular incisors.

When it comes to symmetrical root canal configurations between the right and left mandibular incisors, the present study reported diversity in only (1.2%) of mandibular incisors. Similarly, a study performed by Zhengyan *et al.* concluded that there was no significant variation in terms of bilateral symmetry when comparing both sides.<sup>[2]</sup> These findings suggest that the root canal anatomy of mandibular incisors may predict the configuration of corresponding teeth on the contralateral side. The present study is the first to report the mandibular incisors' morphology and canal configuration among Al-Madinah Al-Munawara residents. The main strengths of this study were its large sample size and its inclusion of all mandibular incisors to assess the bilateral symmetry.

## CONCLUSION

The current study reported that the permanent mandibular incisors' root anatomy displayed bilateral symmetry among the residents of Al-Madinah Al-Munawara. In addition, the majority of teeth were single rooted, with a remarkable occurrence of single-canal morphology. In terms of Saudi nationals and non-Saudi residents, there were no significant differences in root anatomy or canal configuration.

## Financial support and sponsorship

Nil.

## Conflicts of interest

There are no conflicts of interest.

**Table 2: Vertucci's root canal configurations of mandibular incisors by gender**

Type	Left mandibular lateral incisor (#32)		Left mandibular central incisor (#31)		Right mandibular central incisor (#41)		Right mandibular lateral incisor (#42)		Total	
	Male, n (%)	Female, n (%)	Male, n (%)	Female, n (%)	Male, n (%)	Female, n (%)	Male, n (%)	Female, n (%)	Male, n (%)	Female, n (%)
I	142 (11.8)	68 (16)	131 (10.9)	68 (16)	132 (11)	70 (16.5)	138 (11.5)	69 (16.2)	543 (45.2)	275 (64.8)
II	0	0	0	0	0	0	0	0	0	0
III	136 (11.3)	31 (7.3)	144 (12)	33 (7.7)	143 (11.9)	31 (7.3)	140 (11.6)	30 (7)	563 (46.9)	125 (29.4)
IV	0	1 (0.2)	0	1 (0.2)	0	1 (0.2)	0	1 (0.2)	0	4 (0.9)
V	18 (1.5)	5 (1.1)	18 (1.5)	2 (0.4)	18 (1.5)	2 (0.4)	19 (1.5)	5 (1.1)	73 (6)	14 (3.3)
VI	0	0	0	0	0	0	0	0	0	0
VII	4 (0.3)	1 (0.2)	7 (0.5)	2 (0.4)	7 (0.5)	2 (0.4)	3 (0.2)	1 (0.2)	21 (1.7)	6 (1.4)
VIII	0	0	0	0	0	0	0	0	0	0

**Table 3: Vertucci's root canal configurations of mandibular incisors by nationality**

Type	Left mandibular lateral incisor (#32)		Left mandibular central incisor (#31)		Right mandibular central incisor (#41)		Right mandibular lateral incisor (#42)		Total	
	Saudi, n (%)	Non-Saudi, n (%)	Saudi, n (%)	Non-Saudi, n (%)	Saudi, n (%)	Non-Saudi, n (%)	Saudi, n (%)	Non-Saudi, n (%)	Saudi, n (%)	Non-Saudi, n (%)
I	125 (12.5)	85 (13.5)	117 (11.7)	82 (13)	119 (11.9)	83 (13.2)	125 (12.5)	82 (13)	486 (48.7)	332 (52.8)
II	0	0	0	0	0	0	0	0	0	0
III	106 (10.6)	61 (9.7)	115 (11.5)	62 (9.8)	113 (11.3)	61 (9.7)	106 (10.6)	64 (10.1)	440 (44.1)	248 (39.4)
IV	0	1 (0.1)	0	1 (0.1)	0	1 (0.1)	0	1 (0.1)	0	4 (0.6)
V	14 (1.4)	9 (1.4)	12 (1.2)	8 (1.2)	12 (1.2)	8 (1.2)	15 (1.5)	9 (1.4)	53 (5.3)	34 (5.4)
VI	0	0	0	0	0	0	0	0	0	0
VII	4 (0.4)	1 (0.1)	5 (0.5)	4 (0.6)	5 (0.5)	4 (0.6)	3 (0.3)	1 (0.1)	17 (1.7)	10 (1.5)
VIII	0	0	0	0	0	0	0	0	0	0

## REFERENCES

- Benjamin KA, Dowson J. Incidence of two root canals in human mandibular incisor teeth. *Oral Surg Oral Med Oral Pathol* 1974;38:122-6.
- Zhengyan Y, Keke L, Fei W, Yueheng L, Zhi Z. Cone-beam computed tomography study of the root and canal morphology of mandibular permanent anterior teeth in a chongqing population. *Ther Clin Risk Manag* 2016;12:19-25.
- Aminsobhani M, Sadegh M, Meraji N, Razmi H, Kharazifard MJ. Evaluation of the root and canal morphology of mandibular permanent anterior teeth in an Iranian population by cone-beam computed tomography. *J Dent (Tehran)* 2013;10:358-66.
- Akhtar S, Siddiqui F, Sheikh A, Rashid S, Khurshid Z, Najeeb S, *et al.* Frequency of procedural errors during root canal treatment performed by interns. *British Biotechnol J* 2016;12:1-8.
- Leoni GB, Versiani MA, Pécora JD, Damião de Sousa-Neto M. Micro-computed tomographic analysis of the root canal morphology of mandibular incisors. *J Endod* 2014;40:710-6.
- Vertucci FJ. Root canal anatomy of the human permanent teeth. *Oral Surg Oral Med Oral Pathol* 1984;58:589-99.
- Vertucci FJ. Root canal morphology and its relationship to endodontic procedures. *Endodontic Topics* 2005;10:3-29.
- Kartal N, Yanikoğlu FC. Root canal morphology of mandibular incisors. *J Endod* 1992;18:562-4.
- Çalışkan MK, Pehlivan Y, Sepetçioğlu F, Türkün M, Tuncer SS. Root canal morphology of human permanent teeth in a Turkish population. *J Endod* 1995;21:200-4.
- Miyashita M, Kasahara E, Yasuda E, Yamamoto A, Sekizawa T. Root canal system of the mandibular incisor. *J Endod* 1997;23:479-84.
- Al-Qudah AA, Awawdeh LA. Root canal morphology of mandibular incisors in a Jordanian population. *Int Endod J* 2006;39:873-7.
- Sert S, Aslanalp V, Tanalp J. Investigation of the root canal configurations of mandibular permanent teeth in the Turkish population. *Int Endod J* 2004;37:494-9.
- Plotino G, Grande NM, Pecci R, Bedini R, Pameijer CH, Somma F. Three-dimensional imaging using microcomputed tomography for studying tooth macromorphology. *J Am Dent Assoc* 2006;137:1555-61.
- Fan B, Yang J, Gutmann JL, Fan M. Root canal systems in mandibular first premolars with C-shaped root configurations. Part I: Microcomputed tomography mapping of the radicular groove and associated root canal cross-sections. *J Endod* 2008;34:1337-41.
- Sberna MT, Rizzo G, Zacchi E, Capparè P, Rubinacci A. A preliminary study of the use of peripheral quantitative computed tomography for investigating root canal anatomy. *Int Endod J* 2009;42:66-75.
- Neelakantan P, Subbarao C, Subbarao CV. Comparative evaluation of modified canal staining and clearing technique, cone-beam computed tomography, peripheral quantitative computed tomography, spiral computed tomography, and plain and contrast medium-enhanced digital radiography in studying root canal morphology. *J Endod* 2010;36:1547-51.
- Paes da Silva Ramos Fernandes LM, Rice D, Ordinola-Zapata R, Alvares Capelozza AL, Bramante CM, Jaramillo D, *et al.* Detection of various anatomic patterns of root canals in mandibular incisors using digital periapical radiography, 3 cone-beam computed tomographic scanners, and micro-computed tomographic imaging. *J Endod* 2014;40:42-5.
- Patel S, Durack C, Abella F, Shemesh H, Roig M, Lemberg K. Cone beam computed tomography in endodontics – A review. *Int Endod J* 2015;48:3-15.
- Green D. Double canals in single roots. *Oral Surg Oral Med Oral Pathol* 1973;35:689-96.
- Al-Fouzan K, Al-Rejaie M, AlManee A, Jan J, Al-Rejaie M. Incidence of two canals in extracted mandibular incisors teeth of Saudi Arabian samples. *Saudi Endod J* 2012;2:65-9.
- Alrahabi M, Zafar M. Evaluation of root canal morphology of maxillary molars using cone beam computed tomography. *Pak J Med Sci* 2015;31:426-30.
- Zafar M, Alrahabi M. Cone beam computed tomography for exploring morphology of mandibular first molar. *Br J Med Med Res* 2015;6:514-21.
- Han T, Ma Y, Yang L, Chen X, Zhang X, Wang Y. A study of the root canal morphology of mandibular anterior teeth using cone-beam computed tomography in a Chinese subpopulation. *J Endod* 2014;40:1309-14.
- Shemesh A, Kavalierchik E, Levin A, Ben Itzhak J, Levinson O, Lvovsky A, *et al.* Root canal morphology evaluation of central and lateral mandibular incisors using cone-beam computed tomography in an Israeli Population. *J Endod* 2018;44:51-5.
- Thota LB, Gunaranjan T, Krishna VN, Sridhar M, Reddy AE, Madhusudhana K. Root canal morphology of mandibular central incisors in Nellore population. *Int J Oral Care Res* 2016;4:8-10.
- Singh S, Pawar M. Root and canal morphology of mandibular incisors and canines in South Asian Indian population by canal staining and tooth clearing technique. *Endodontology* 2016;28:148-53.
- Kamtane S, Ghodke M. Morphology of mandibular incisors: A study on CBCT. *Pol J Radiol* 2016;81:15-6.