

# Malpositioned canine treatment with autotransplantation and laser

Serap Keskin Tunc<sup>1</sup>, Mehmet Savas Kayasan<sup>2</sup>, Esmâ Ozeroglu<sup>3</sup>, Cennet Neslihan Eroglu<sup>1</sup>

**Correspondence:** Dr. Serap Keskin Tunc  
Email: serapkeskin0165@hotmail.com

<sup>1</sup>Department of Oral and Maxillofacial Surgery, Yuzuncu Yil University, Van, Turkiye,  
<sup>2</sup>Department of Orthodontics, Yuzuncu Yil University, Van, Turkiye,  
<sup>3</sup>Department of Endodontics, Yuzuncu Yil University, Van, Turkiye

## ABSTRACT

Children and young adults often have tooth loss due to congenital tooth deficiency, trauma, or caries. Autotransplantation has many benefits. The transplanted tooth can be moved orthodontically, maintains alveolar bone growth potential during eruption, and functional periodontal ligament function also permits tooth eruption, allows the defected areas to be filled with the bones; gingival contour is much more successful than the one obtained with prosthesis. In this paper, treatment steps and follow-up results of autotransplantation case supported with biostimulation are mentioned. A 14-year-old female patient was admitted to the clinic with a complaint of decayed tooth 53 and malposed tooth 13. Mobile primary tooth was pulled out, and the socket was shaped with surgical drills. By performing transplantation of ectopic canine, splint was applied with steel wire and composite. Diode laser was used to provide deep disinfection of canals. The patient underwent low-dose laser therapy for biostimulation immediately after these procedures. We did not encounter any ankylosis, root resorption, periodontal, or functional problems in our evaluation with computed tomography after 3 years follow-up of the patient.

**Key words:** Autotransplantation, biostimulation, diode laser, erbium, chromium:yttrium-scandium-gallium-garnet

## INTRODUCTION

Children and young adults often have tooth loss due to congenital tooth deficiency, trauma, or caries. Treatment options include bridges, implants, removable dentures, and attachments.<sup>[1]</sup> Dental implants are contraindicated in cases where growth and development still persist.<sup>[2]</sup> In addition to these, autotransplantation is a neglected alternative treatment that moves one tooth to another tooth in the mouth.<sup>[3]</sup> Autotransplantation has many benefits. The transplanted tooth can be moved orthodontically, maintains alveolar bone growth potential during eruption, and functional periodontal ligament

function also permits tooth eruption, allows the defected areas to be filled with the bones; gingival contour is much more successful than the one obtained with prosthesis.<sup>[3]</sup>

Slagsvold and Bjercke have published transplantation indications, surgical procedures and follow-up protocols at the University of Oslo. The success rate of the method is 90% and it was observed in the long-term studies that there were no differences from normal teeth after 2–4 years.<sup>[4]</sup>

This is an open access article distributed under the terms of the Creative Commons Attribution-NonCommercial-ShareAlike 3.0 License, which allows others to remix, tweak, and build upon the work non-commercially, as long as the author is credited and the new creations are licensed under the identical terms.

**For reprints contact:** reprints@medknow.com

**How to cite this article:** Tunc SK, Kayasan MS, Ozeroglu E, Eroglu CN. Malpositioned canine treatment with autotransplantation and laser. *Eur J Dent* 2017;11:395-7.

**DOI:** 10.4103/ejd.ejd\_355\_16

Access this article online	
<p>Quick Response Code:</p> 	<p>Website: www.eurjdent.com</p>

Biostimulation is described as a photochemical reaction of tissue and light. Photodynamic therapy has been actively used in all areas of dentistry in the recent years. This reaction can cause various biostimulator effects; it was used to improve wound healing, tissue repair and regeneration (intra canal disinfection), reducing dental sensitivity, and reducing pain in the postoperative process in orthodontic treatment.<sup>[5]</sup>

In this paper, treatment steps and follow-up results of autotransplantation case supported with biostimulation are mentioned.

## CASE REPORT

A 14-year-old female patient was admitted to the clinic with a complaint of decayed tooth 53 and malposed tooth 13. Tooth number 13 was positioned on palatal of tooth number 15. Relation of the patient's molar teeth was in class 1 bite occlusion, and no problems were observed in the occlusion. The patient did not accept orthodontic treatment. Due to the age of the patient, implant therapy or prosthetic treatment was not favored.

In the patient with the right and left molar relationship was class 1, it was measured that overjet was 2 mm, overbite was 2.5 mm, and centric occlusion was 2 mm left to the center line. Mobility dependent to root resorption was observed in the right maxillary persistent primary tooth of the patient, and the prognosis was evaluated as poor. The right maxillary canine tooth was found to be proceeded from the palatal of the right second premolar tooth [Figure 1].

As a result of intraoral and radiographic evaluations, it was determined that sufficient space of the ectopic canine which was present in the recipient area. Mobile primary tooth was pulled out, and the socket

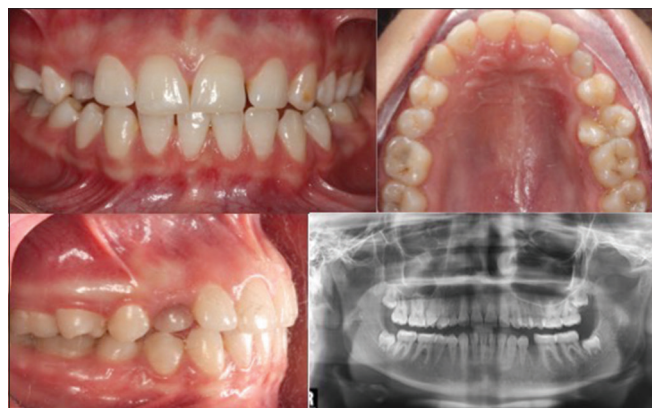

Figure 1: Preoperative image

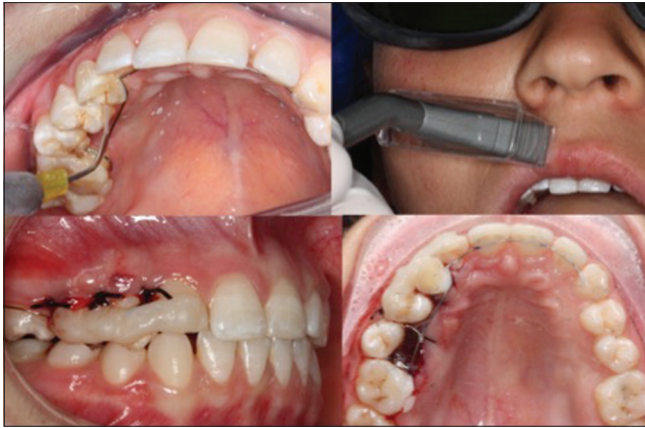was shaped with surgical drills. By performing transplantation of ectopic canine, splint was applied with steel wire and composite (2 weeks). With a diamond round bur, the endodontic access cavity was opened to the tooth immobilized by splint Working height was determined with K-type stainless steel canal file. Canal mouth was shaped 3 mm with Gates Glidden drill. The canal shaping process was carried out with X-Smart Plus (Dentsply), endodontic motor at 300 rpm and 200–520 gcm torque with a slight pressure toward the apical and brushing motion with WaveOne Primary (Dentsply) (25 mm, 0.08 taper) file. Before shaping, canal was washed with 17% ethylenediaminetetraacetic acid. Canal was washed with 5% NaOCl before and after shaping process. After shaping process and washing, while there was 5% NaOCl in the canal, the canal was dried by applying to only 1/3 coronal of the canal with erbium, chromium:yttrium-scandium-gallium-garnet (Er, Cr:YSGG) laser (Waterlase MD, Biolase) at 2.78  $\mu\text{m}$  wavelength with 16.99 J/cm<sup>2</sup> power at 1.0 W on repeat mode with 30 Hz RFT2 tip. Diode laser was used to provide deep disinfection of canals (Ezlase, Biolase, USA). Diode laser was applied at 940  $\mu\text{m}$  wavelength with 1 W output power in continuous mode using endo tip with circular movements in the apical-coronal direction in a way to stay in canal for 10 s by repeating 4 times. After completion of the disinfection process, the canal was filled with cold lateral compaction method using canal gutta-percha and AH Plus root canal sealer.

The patient underwent low-dose laser therapy for biostimulation immediately after these procedures. Using a diode laser, it was applied to the area where the tooth was placed by passing from top to bottom at 940  $\mu\text{m}$  wavelength, 0.5 W output power for 20 s in continuous mode, and this process was repeated 3 times. This process was continued on day 1, day 2, day 3, day 7, and day 10 [Figure 2]. After 2 weeks, the splint was removed and the patient was followed up.

We did not encounter any ankylosis, root resorption, periodontal, or functional problems in our evaluation with computed tomography after 3 years follow-up of the patient [Figure 3].

## DISCUSSION

Even if the transplanted tooth will be resorbed in the future, autotransplantation is an advantageous treatment option due to maintaining the existing bone preservation and vertical bone growth within



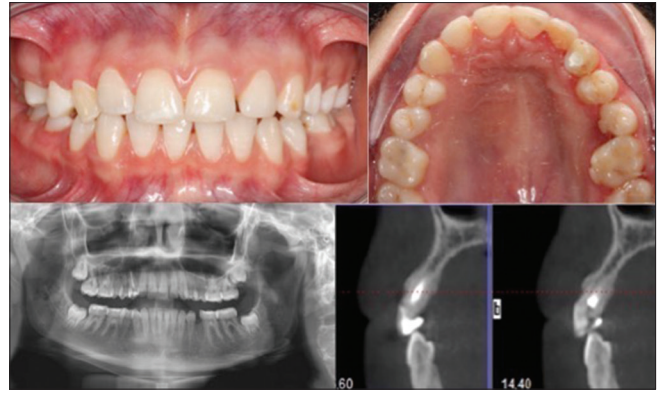
**Figure 2:** Intraoperative image

the observed time.<sup>[6]</sup> Because of this advantage, it is aimed to protect the bone for implant therapy even if resorption will be observed in the future.

Success is achieved with accurate indications and careful atraumatic surgical technique. During donor tooth extraction, vessel nerve bundles are totally torn and are treated with related dental canal treatment during treatment. Apical healing depends on the atraumatic extraction and the proper placement on the recipient site.<sup>[7]</sup> The incidence of internal and external root resorption also depends on the intrapulpal exposition and the mechanical trauma on the root surface. The success of healing is high in children and young adults because of this reason. The success of autotransplantation can be evaluated at the end of the 1<sup>st</sup> year follow-up.<sup>[3]</sup> In the presented case, follow-up was performed for 3 years and clinical success was observed.

New technologies examine root canal disinfection without damaging healthy tissues. Diode lasers in this field are implemented in four different wavelengths 810–830, 940, 980, and 1064 nm.<sup>[8]</sup> In a study of Jhingan *et al.*, the application of intracanal disinfection with 980 nm wavelength laser with conventional endodontic treatment showed successful results compared to control groups.<sup>[9]</sup> In this case, 940 μm wavelength diode laser was used in canal disinfection.

Biostimulation has been found useful during wound healing and orthodontic treatment.<sup>[10]</sup> Diode laser was used to improve the wound healing after orthotransplantation and the orthodontic force applied by the splint to the tooth in the positive direction, and diode and Er, Cr:YSGG lasers were used for canal applications.



**Figure 3:** Postoperative image

As a result, we observed the positive effects of laser on the treatment steps to be performed after autotransplantation. It is possible to perform a successful application by utilizing the diode laser biostimulator effect during the healing period by the use of diode and Er, Cr:YSGG lasers in the root canal treatment stages utilizing the diode laser biostimulator effect also in the improvement period of surgical procedure with use of diode and Er, Cr:YSGG lasers during the root canal treatment.

#### Financial support and sponsorship

Nil.

#### Conflicts of interest

There are no conflicts of interest.

#### REFERENCES

- Schmidt SK, Cleverly DG. Tooth autotransplantation: An overview and case study. *Northwest Dent* 2012;91:29-33.
- Harzer W, Rürger D, Tausche E. Autotransplantation of first premolar to replace a maxillary incisor-3D-volume tomography for evaluation of the periodontal space. *Dent Traumatol* 2009;25:233-7.
- Machado LA, do Nascimento RR, Ferreira DM, Mattos CT, Vilella OV. Long-term prognosis of tooth autotransplantation: A systematic review and meta-analysis. *Int J Oral Maxillofac Surg* 2016;45:610-7.
- Slagsvold O, Bjercke B. Autotransplantation of premolars with partly formed roots. A radiographic study of root growth. *Am J Orthod* 1974;66:355-66.
- Doshi-Mehta G, Bhad-Patil WA. Efficacy of low-intensity laser therapy in reducing treatment time and orthodontic pain: A clinical investigation. *Am J Orthod Dentofacial Orthop* 2012;141:289-97.
- Cunha DL, Masioli MA, Intra JB, Roldi A, Dardengo Cde S, Miguel JA. Premolar transplantation to replace a missing central incisor. *Am J Orthod Dentofacial Orthop* 2015;147:394-401.
- Chwaja-Pawelec K. Tissue healing after autologous tooth transplantation. *Dent Med Probl* 2010;47:359-64.
- Miserendino L, Robert PM. *Lasers in Dentistry*. Hanover Park, IL: Quintessence Publishing; 1995.
- Jhingan P, Sandhu M, Jindal G, Goel D, Sachdev V. An *in-vitro* evaluation of the effect of 980 nm diode laser irradiation on intra-canal dentin surface and dentinal tubule openings after biomechanical preparation: Scanning electron microscopic study. *Indian J Dent* 2015;6:85-90.
- Chung SE, Tompson B, Gong SG. The effect of light emitting diode phototherapy on rate of orthodontic tooth movement: A split mouth, controlled clinical trial. *J Orthod* 2015;42:274-83.