

# Linear Cephalometric Analysis of Pharynx at the Level of Epiglottis among Snorers and Nonsnorers: A Cross-Sectional Study

## Abstract

**Background and Aim:** Snoring, which falls within the spectrum of sleep-related breathing disorders, is considered to be one of the common symptoms of airway obstruction. Lateral cephalometric analysis is an effective way of diagnosing airway obstruction by evaluating skeletal and soft-tissue abnormalities in patients with sleep-disordered breathing. The present study was planned to analyze the pharyngeal space among snorers and nonsnorers in retroglossal region and in the region of the hypopharynx at the level of epiglottis. **Materials and Methods:** The present cross-sectional study included a total of 60 individuals who were grouped into snorers and nonsnorers based on their answers for the study questionnaire related to snoring. Digital lateral cephalograms were taken for all maintaining the exposure parameters, whereas Digora software was used for measurements related to the soft-tissue parameters. The two significant soft-tissue parameters analyzed were the distance of epiglottis from the tip of the soft palate, the retroglossal length and the distance of posterior pharynx from the tip of the epiglottis, the pharyngeal space. **Statistical Analysis Used:** The statistical analysis was done using the Statistical Package for the Social Sciences (SPSS) version 17.0 (SPSS Inc., Chicago, IL, USA), whereas paired *t*-test was used for inter-group analysis. *P* < 0.05 was considered statistically significant. **Results:** The mean retroglossal length was found to be 25.52 mm among the snorers and 23.70 mm among the nonsnorers. In the case of pharyngeal space, a mean of 8.54 mm was recorded among the snorers, whereas among the nonsnorers, the respective mean value of 10.16 mm was observed. **Conclusion:** In the present study, pharyngeal space was found to be less at the level of the tip of epiglottis among the snorers compared to nonsnorers which can be attributed to be one of the significant reasons behind snoring and obstructive sleep apnea syndrome.

**Keywords:** Cephalometric analysis, epiglottis, epiglottis closure, pharynx, sleep endoscopy, snorers

## Introduction

Snoring which falls within the spectrum of sleep-related breathing disorders is considered to be one of the common symptoms of airway obstruction. Snorers can also be divided into occasional snorers and habitual snorers, the ones who snore always, almost every night or, at least for a minimum of 3–4 times a week. Snoring in the pediatric population is increasing and has been identified as a primary health concern by the American Academy of Pediatrics. This increase has been associated with a rise in comorbid disease processes such as asthma and allergies, lifestyle changes, and increased risk of obesity in the pediatric population. Sleep-disordered breathing (SDB) is a collective clinical term encompassing primary snoring, upper airway resistance syndrome, and obstructive

sleep apnea syndrome (OSAS).<sup>[1]</sup> These syndromes currently are regarded to fall along a spectrum of severity concerning the same pathophysiological condition which is caused by vibrating tissues accompanied by increased collapsibility and incomplete pharyngeal obstruction or narrowing of the pharyngeal airway.<sup>[2]</sup> Snoring has, also, been considered to be an inevitable symptom of OSAS which, further, has been shown to be associated with an increased risk for hypertension and angina pectoris.<sup>[3]</sup> Over the years, lateral cephalometric radiography has emerged as one of the standard diagnostic tools to evaluate skeletal and soft-tissue abnormalities. Lateral cephalometric analysis has, also, been found to be an effective way of diagnosing skeletal and soft-tissue abnormalities contributing to these types of anatomic obstructions and to

Ravi Rathod,  
Vimal Joseph  
Devadoss<sup>1</sup>,  
Baliram Jadav,  
Reshmi Leila Ninan<sup>2</sup>,  
B. Kanagasabapathy<sup>2</sup>,  
A. R. Ramshad<sup>3</sup>,  
J. Suresh Babu<sup>4</sup>,  
C. Swarnalatha<sup>4</sup>,  
Abhishek Singh  
Nayyar<sup>5</sup>

Department of Orthodontics and Dentofacial Orthopaedics, Meghna Institute of Dental Sciences, Nizamabad, Telangana,

<sup>1</sup>Department of Oral and Maxillofacial Surgery, Rajas Dental College and Hospital, Tirunelveli, <sup>2</sup>Department of

Orthodontics and Dentofacial Orthopaedics, CSI College of Dental Sciences and Research, Madurai, Tamil Nadu, <sup>3</sup>Consultant

Orthodontist, Kuttichira, Kollam, Kerala, <sup>5</sup>Department of Oral Medicine and Radiology, Saraswati Dhanwantari Dental College and Hospital and Post-Graduate Research Institute,

Parbhani, Maharashtra, India, <sup>4</sup>Department of Preventive Dental Sciences, Division of Periodontology, College of Dentistry, University of Ha'il, Ha'il, Kingdom of Saudi Arabia

### Address for correspondence:

Dr. Abhishek Singh Nayyar,  
Department of Oral Medicine and Radiology, Saraswati Dhanwantari Dental College and Hospital and Post-graduate Research Institute, Parbhani, Maharashtra, India.  
E-mail: singhabhishekndls@gmail.com

### Access this article online

Website: www.asianjns.org

DOI: 10.4103/ajns.ajns\_315\_21

### Quick Response Code:



This is an open access journal, and articles are distributed under the terms of the Creative Commons Attribution-NonCommercial-ShareAlike 4.0 License, which allows others to remix, tweak, and build upon the work non-commercially, as long as appropriate credit is given and the new creations are licensed under the identical terms.

For reprints contact: WKHLRPMedknow\_reprints@wolterskluwer.com

**How to cite this article:** Rathod R, Devadoss VJ, Jadav B, Ninan RL, Kanagasabapathy B, Ramshad AR, et al. Linear cephalometric analysis of pharynx at the level of epiglottis among snorers and nonsnorers: A cross-sectional study. Asian J Neurosurg 2021;16:817-20.

Submitted: 02-Sep-2021

Revised: 17-Sep-2021

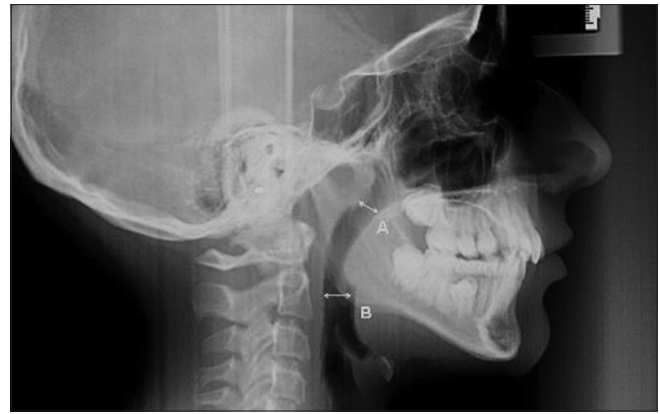Accepted: 27-Sep-2021

Published: 18-Dec-2021

evaluate patients with SDB. Radiograms of the head and neck with special focus on several bony and soft-tissue landmarks are involved in this traditional method. Furthermore, numerous 2D and 3D studies have, also, been conducted on understanding the pharyngeal space in the retropalatal region.<sup>[1]</sup> There is a relative dearth of studies which have attempted to evaluate the airway space related to the epiglottis. The present study was planned with a similar intent to analyze the pharyngeal space among snorers and nonsnorers in the retroglossal region and in the region of hypopharynx at the level of epiglottis as well as its association with the height and weight of the individuals.

## Materials and Methods

The present cross-sectional study was conducted in the department of oral medicine and radiology over the duration of 1 year wherein the study participants included volunteers among the students and outpatients in an age range of 18–30 years. A written consent form was signed by all the volunteers before their inclusion into the study whereas ethical clearance was obtained from the institutional ethics committee before the start of the study. The study included a total of 60 individuals who were grouped into snorers and nonsnorers with 30 individuals in each category based on their answers for the study questionnaire related to snoring. The patients with a positive history of snoring for a minimum of 3–4 times a week were categorized as habitual snorers, whereas patients with no positive known history of snoring were categorized as nonsnorers. Patients who were not willing to participate in the study, those who were with previous history of trauma or, environmental factors known to cause craniofacial deformity, patients who were undergoing or, previously had orthodontic/orthognathic surgeries, those who presented with gross facial asymmetry, history of surgical intervention involving craniofacial skeleton and soft tissue surgery in head and neck region were excluded from the present study. Patients with history and/or, clinical features suggestive of endocrine disturbances, neuromuscular disorder (this was the reason why elderly patients were excluded), hereditary, nutritional, developmental or, any other prolonged illness affecting the oropharynx as well as pregnant and lactating females were, also, excluded from the study. Digital lateral cephalograms were taken for all the patients, maintaining the exposure parameters, with all radiation safety measures. Radiographs with optimum contrast and less noise were considered for the study. All images were stored digitally, and the image quality was optimized separately for soft-tissue and hard-tissue landmarks using the inbuilt software (Digora for Windows) used for measurements related to the soft-tissue parameters. The two significant soft-tissue parameters analyzed were the distance of epiglottis from the tip of the soft palate, the retroglossal length and the distance of posterior pharynx from the tip of the epiglottis, the pharyngeal space [Figures 1 and 2]. The height and weight



**Figure 1:** Digital lateral cephalogram showing distance of epiglottis from the tip of the soft palate (a) and distance of posterior pharynx from the tip of the epiglottis (b)

of the patients were, also, recorded at the time of eliciting the history whereas the resultant body mass indices were correlated with the parameters analyzed.

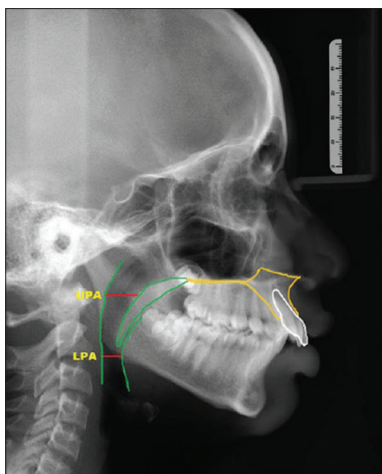
## Statistical analysis used

The statistical analysis was performed using the Statistical Package for the Social Sciences (SPSS) version 17.0 (SPSS Inc., Chicago, IL, USA), whereas paired *t*-test was used for inter-group analysis.  $P < 0.05$  was considered statistically significant.

## Results

Distance of epiglottis from the tip of the soft palate, the retroglossal length: in case of the retroglossal length, among the snorers, the minimum and maximum distance recorded were 13.92 mm and 38.87 mm, respectively, with a mean of 25.52 mm, whereas among the nonsnorers, the respective values were found to be 15.76 mm and 38.64 mm, respectively, with a mean value of 23.70 mm. The above observations revealed the retroglossal length to be slightly more (mean = +1.82 mm) among the snorers as compared to the nonsnorers ( $P > 0.05$ ) [Table 1]. The distance of epiglottis from the tip of the soft palate was, also, compared with the height of the individual wherein a direct correlation was observed between the two, the results, though, were found to be statistically insignificant.

Distance of posterior pharynx from the tip of the epiglottis, the pharyngeal space: in case of pharyngeal space, among the snorers, the minimum and maximum distance recorded were 5.53 mm and 17.61 mm, respectively, with a mean of 8.54 mm, whereas among the nonsnorers, the respective values were found to be 7.39 mm and 12.87 mm, respectively, with a mean value of 10.16 mm. The above observations revealed the pharyngeal space to be slightly less (mean = -1.62 mm) among the snorers as compared to the nonsnorers ( $P < 0.05$ ) [Table 1]. The distance of posterior pharynx from the tip of the epiglottis was also compared with the weight of the individual wherein a



**Figure 2: Lateral cephalometric analysis showing distance of epiglottis from the tip of the soft palate (UPA) and distance of posterior pharynx from the tip of the epiglottis (LPA)**

direct correlation was observed between the two in 37 of the individuals whereas in rest of the 23 individuals, this distance was found to be with high variations without any correlation.

## Discussion

Snoring and OSAS are potentially serious disorders affecting millions of people attributed to nasal obstruction such as nasal polyps, deviated nasal septum, hypertrophic inferior turbinates, and oropharyngeal obstruction wherein soft palate, tonsils, and pharynx show discordance in their normal physiological functioning.<sup>[4]</sup> Surgical treatment, uvulopalatopharyngoplasty, initially described by Fujita *et al.*,<sup>[5]</sup> is the only mode of treatment used to correct these disorders by removing obstruction at the oropharyngeal level by modification of uvula, removal of redundant pharyngeal and palatal tissues, and primary closure of the anterior and posterior faucial pillars to enlarge the retropalatal airway. Quinn *et al.*<sup>[6]</sup> performed sleep nasoendoscopy on 54 adult snorers in their study of whom obstructive sleep apnea had been excluded by an overnight sleep study. This was successfully achieved in 50 of the 54 snorers, whereas 35 out of 50 (70%) of the individuals had palatal flutter snoring only. In a further 20% of the individuals, palatal flutter snoring was combined with evidence of noise generation at another site with this second site being supraglottic in 10%, tonsillar in 8%, and tongue base in 2% of the said individuals. The tongue base was also the sole site of noise generation in 8%, whereas the epiglottis, the sole site in 2% of the individuals studied. Another study conducted by Horner *et al.*<sup>[7]</sup> revealed large deposits of fat in the posterolateral to oropharyngeal airspaces at the level of the soft palate on magnetic resonance imaging findings, whereas a linear correlation was suggested between obesity and obstructive sleep apnea in patients where fat deposits were held responsible for the narrowing of the upper respiratory tract. The relationship between obstructive

**Table 1: Soft-tissue parameters analyzed by lateral cephalometry**

Parameter	Group	n	Mean	SD	t	P
Distance of epiglottis from the tip of the soft palate	Snorer	30	25.52	5.34	1.35	0.179
	Nonsnorer	30	23.70	5.05		
Distance of posterior pharynx from the tip of the epiglottis	Snorer	30	8.54	2.41	-2.73	0.008*
	Nonsnorer	30	10.16	2.18		

\* $P < 0.05$  - Statistically significant. SD – Standard deviation

sleep apnea and obesity was proven in yet another study, too, conducted by Jehan *et al.*<sup>[8]</sup> discussing its impact on public health. The present study, also, revealed a direct correlation between pharyngeal space and obesity in 62% of the individuals studied at the level of epiglottis and the results were found to be statistically significant ( $P < 0.05$ ). Another study conducted by Azarbarzin *et al.*<sup>[9]</sup> on 23 OSAS patients who underwent sleep endoscopy scored a total of 1232 breaths as epiglottic/nonepiglottic collapse and revealed that epiglottic collapse was characterized by a rapid fall (s) in the inspiratory flow, more variable inspiratory and expiratory flow, and reduced tidal volume. The cross-validated accuracy in the said study was calculated to be around 84% while it was shown that a characteristic anteroposterior movement of epiglottis produced a sharp and severe reduction in airflow and the epiglottis was observed to be an unstable structure that would sometimes reopen/close repeatedly during inspiration causing a “jagged” flow of air. It was also observed in the said study that in addition to producing unique flow features, epiglottic collapse may also generate characteristic sounds that may be different than the nonepiglottic snoring sounds. Surgical intervention in the form of epiglottis stiffening operation has been successfully employed to treat epiglottic collapse in OSAS patients.<sup>[10]</sup> Previous studies have, also, argued that the posterior movement of the tongue could cause the epiglottis to collapse.<sup>[11]</sup> The present study, thus, aimed at evaluating the linear measurement changes in the retroglottal region among the snorers, wherein it was observed that the retroglottal length was slightly more (mean = +1.82 mm) among the snorers as compared to the nonsnorers which can be interpreted as more of the posterior surface area of the tongue being available leading the tongue to fall back causing epiglottic collapse. A cone-beam computed tomography study conducted by Buchanan *et al.*<sup>[12]</sup> had, also, made similar observations wherein they had shown that OSAS patients had a significantly smaller average airway area, average airway volume, total airway volume, and mean airway width. Furthermore, it was observed that OSAS patients, on the contrary, had a significantly larger airway length measurement. Very few studies have been conducted so far on analyzing the pharyngeal space with respect to the epiglottis and its related structures, thus, highlighting the significance and clinical implications the present study had. Although, the present study had its own set of clinical implications, the findings made in the present

study had certain limitations in the form of inclusion of the study participants which was done purely on the basis of their answers for the study questionnaire related to snoring while no confirmatory tests such as polysomnography or, nasoendoscopy were performed. Also, the present study did not include any known cases of OSAS selectively. The present study, though, had a serious merit since it used lateral cephalometric analysis, a technique which is easy to understand and which provides an objective assessment of the pharyngeal obstruction at the level of epiglottis based on soft and hard tissue landmarks and subsequent, measurements related to the soft tissue parameters. Lateral cephalometry, also, is an easily available and cost-effective radiological procedure. The present study, thus, paves way for further research in this regard, wherein highly objective linear measurement and volumetric studies can be conducted with a relatively larger sample size and adequate representation for individuals suffering from snoring and OSAS with newly introduced and advanced 3D modes of imaging with respect to the pharyngeal space in the region of hypopharynx.

### Conclusion

In the present study, retroglossal length was found to be more among the snorers compared to nonsnorers whereas the pharyngeal space was found to be less at the level of the tip of the epiglottis. The present study, thus, paves way for further research in this regard, wherein newly introduced and advanced 3D modes of imaging can be used to obtain objective anatomic details behind snoring and OSAS with respect to the pharyngeal space in the region of the hypopharynx.

### Acknowledgment

To all the patients who contributed in the study without whom this study would not have been feasible.

### Financial support and sponsorship

Nil.

### Conflicts of interest

There are no conflicts of interest.

### References

1. Lefebvre E, Moreau R. Snoring Causes, Diagnosis and Treatment. New York: Nova Science Publishers; 2010.
2. Moses AJ. Protocol for primary treatment of snoring by dentists. *Sleep Diagn Ther* 2008;3:21-2.
3. Counter P, Wilson JA. The management of simple snoring. *Sleep Med Rev* 2004;8:433-41.
4. Ephros HD, Madani M, Yalamanchili SC. Surgical treatment of snoring and obstructive sleep apnoea. *Indian J Med Res* 2010;131:267-76.
5. Fujita S, Conway W, Zorick F, Roth T. Surgical correction of anatomic abnormalities in obstructive sleep apnea syndrome: Uvulopalatopharyngoplasty. *Otolaryngol Head Neck Surg* 1981;89:923-34.
6. Quinn SJ, Daly N, Ellis PD. Observation of the mechanism of snoring using sleep nasendoscopy. *Clin Otolaryngol Allied Sci* 1995;20:360-4.
7. Horner RL, Mohiaddin RH, Lowell DG, Shea SA, Burman ED, Longmore DB, *et al.* Sites and sizes of fat deposits around the pharynx in obese patients with obstructive sleep apnoea and weight matched controls. *Eur Respir J* 1989;2:613-22.
8. Jehan S, Zizi F, Pandi-Perumal SR, Wall S, Auguste E, Myers AK, *et al.* Obstructive sleep apnea and obesity: Implications for public health. *Sleep Med Disord* 2017;1:00019. Epub 2017 Dec 12. PMID: 29517065; PMCID: PMC5836788.
9. Azarbarzin A, Marques M, Sands SA, Op de Beeck S, Genta PR, Taranto-Montemurro L, *et al.* Predicting epiglottic collapse in patients with obstructive sleep apnoea. *Eur Respir J* 2017;50:1700345.
10. Salamanca F, Leone F, Bianchi A, Bellotto RG, Costantini F, Salvatori P. Surgical treatment of epiglottis collapse in obstructive sleep apnoea syndrome: Epiglottis stiffening operation. *Acta Otorhinolaryngol Ital* 2019;39:404-8.
11. Lin HS, Rowley JA, Badr MS, Folbe AJ, Yoo GH, Victor L, *et al.* Transoral robotic surgery for treatment of obstructive sleep apnea-hypopnea syndrome. *Laryngoscope* 2013;123:1811-6.
12. Buchanan A, Cohen R, Looney S, Kalathingal S, De Rossi S. Cone-beam CT analysis of patients with obstructive sleep apnea compared to normal controls. *Imaging Sci Dent* 2016;46:9-16.