

Organized Chronic Subdural Hematomas Treated by Large Craniotomy with Extended Membranectomy as the Initial Treatment

Abstract

Objective: The aim of this retrospective study is to evaluate the efficacy and incidence of complications of craniotomy and membranectomy in elderly patients for the treatment of organized chronic subdural hematoma (OCSH). **Materials and Methods:** We retrospectively reviewed a series of 28 consecutive patients suffering from OCSH, diagnosed by magnetic resonance imaging (MRI) or computer tomography (CT) to establish the degree of organization and determine the intrahematomal architecture including inner membrane ossification. The indication to perform a primary enlarged craniotomy as initial treatment for nonliquefied OCSH with multilayer loculations was based on the hematoma MRI appearance – mostly hyperintense in both T1- and T2-weighted images with a hypointense web- or net-like structure within the hematoma cavity or inner membrane calcification CT appearance - hyperdense. These cases have been treated by a large craniotomy with extended membranectomy as the initial treatment. However, the technique of a burr hole with closed system drainage for 24–72 h was chosen for cases of nonseptated and mostly liquefied Chronic Subdural Hematoma (CSDH). **Results:** Between 1998 and 2015, 148 consecutive patients were surgically treated for CSDH at our institution. Of these, 28 patients which have OSDH underwent a large craniotomy with extended membranectomy as the initial treatment. The average age of the patients was 69 (69.4 ± 12.1). Tension pneumocephalus (TP) has occurred in 22.8% of these patients ($n = 28$). Recurring subdural hemorrhage (RSH) in the operation area has occurred in 11.9% of these patients in the first 24 h. TP with RSH was seen in 4 of 8 TP patients (50%). Large epidural air was seen in one case. Postoperative seizures requiring medical therapy occurred in 25% of our patients. The average stay in the department of neurosurgery was 11 days, ranging from 7 to 28 days. Four patients died within 28 days after surgery; mortality rate was 14.28%. **Conclusion:** Large craniotomy and extended membrane excision for OSDH still carry a high rate of mortality and morbidity in elderly patients. TP, RSH, and postoperative seizures are frequently seen complications in elderly patients.

Keywords: Craniotomy, membranectomy, organized chronic subdural hematoma, tension pneumocephalus

Introduction

Chronic subdural hematoma (CSH) represents one of the most frequent intracranial hemorrhages encountered in neurosurgical department, which is seen in elderly citizens more frequently. The reasons why this type of hematoma occurs frequently among the elderly include an increase in antithrombotic medications, venous fragility, augmentation of the subdural space, and an increased exposure to traumatic injury resulting from frequent falls.^[1] CSH is thought to form in the dural border cell layer of the hematoma cavity that is surrounded by outer and inner membranes.^[2] Whereas there are few blood vessels in the inner membrane, the outer membrane contains

many fragile macrocapillaries (also called sinusoidal vessels) that are often the source of repeated multifocal bleeding.^[3] This repeated hemorrhaging from the outer membrane is considered to be a causative factor for progressive enlargement of the hematoma, occurring after a minor head injury,^[4] whereas the inner membrane is related to liquefaction of the subdural hematoma.^[2] CSH consists of a fibrous capsule composed with an inner and outer membrane filled with bloody fluid. Some of the internal architecture of CSH may appear as multiseptated, calcified,^[5] multilobule, or multilayered. This subtype of CSH is defined as organized CSH (OCSH), in which thick membranes with multiple septations develop, leading to the formation of encapsulated areas of a solid consistency.

This is an open access article distributed under the terms of the Creative Commons Attribution-NonCommercial-ShareAlike 3.0 License, which allows others to remix, tweak, and build upon the work non-commercially, as long as the author is credited and the new creations are licensed under the identical terms.

For reprints contact: reprints@medknow.com

How to cite this article: Balevi M. Organized chronic subdural hematomas treated by large craniotomy with extended membranectomy as the initial treatment. *Asian J Neurosurg* 2017;12:598-604.

Mustafa Balevi

Department of Neurosurgery,
Konya Numune Hospital,
Konya, Turkey

Address for correspondence:
Dr. Mustafa Balevi,
Turgut Özal Cd, 42100,
Selçuklu, Konya, Turkey.
E-mail: mbalevi@gmail.com

Access this article online

Website: www.asianjns.org

DOI: 10.4103/ajns.AJNS_8_15

Quick Response Code:



Indications of OCSH on computer tomography (CT) are mixed density, multiseptated CSH, sign of recent hemorrhage, midline shift, thickening, or calcification of the inner membrane.^[5] Magnetic resonance imaging (MRI) of the organized hematoma was hyperintense in both T1–T2 weighted images, sometimes hypointense in T1 and hyperintense in T2; all cases displayed a hypointense web- or net-like structure within the hematoma cavity.^[6-8]

Materials and Methods

We retrospectively reviewed a series of 28 consecutive patients suffering from OCSH, diagnosed by MRI [Figures 2 and 3] or CT [Figure 1] to establish the degree of organization. The indication to perform a primary enlarged craniotomy as initial treatment for nonliquefied OCSH with multilayer loculations was based on the hematoma MRI appearance – mostly hyperintense in both T1- and T2-weighted images with a hypointense web- or net-like structure within the hematoma cavity or inner membrane calcification CT appearance - hyperdense. These cases have been treated by a large craniotomy with extended membranectomy as the initial treatment. However, the technique of a burr hole with closed system drainage for 24–72 h was chosen for cases of nonseptated and mostly liquefied CSDH.

The Markwalder's neurological grading system^[9] was used to evaluate the surgical results on admission and at discharge [Table 1]. Grades for pre- and post-operative results between 0 and 2 were considered good and Grades between 3 and 4 were bad.

Craniotomy limits were decided on the basis of the MRI or CT. A large craniotomy flap is performed to expose the transition zone between external and internal hematoma membranes. The dura is then opened and separated by the external membrane of the hematoma with a dissector. This is always a simple maneuver. Outer hematoma membrane was excised. During this procedure, we were careful not to rupture the dural sinus. Once the reflection zone of the hematoma and the adjacent cortical surface are well

Table 1: The Markwalder’s neurological grading system (NSGM)

0	No neurological deficits
1	Patient alert and oriented, mild symptoms such as headache; absent or mild neurological deficits such as reflex asymmetry
2	Patient drowsy or disoriented with variable neurological Deficits such as hemiparesis
3	Patient stuporous but responding appropriately to noxious Stimuli; severe focal signs such as hemiplegia
4	Patient comatosed with absent motor response to painful Stimuli; decerebre or
5	Decortice posturing

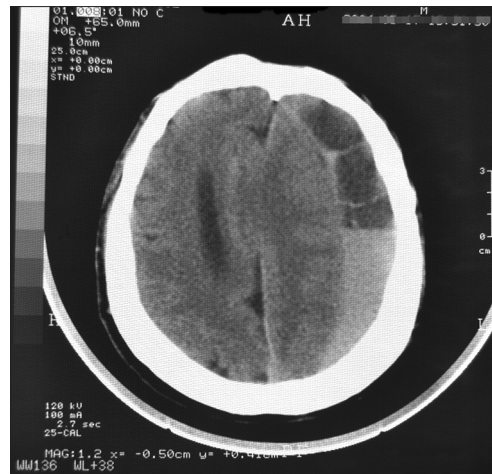

Figure 1: Computed tomography appearance of organized chronic subdural hematoma without contrast medium:mixed density, multiseptated organized chronic subdural hematoma, with signs of recent hemorrhage, midline shift

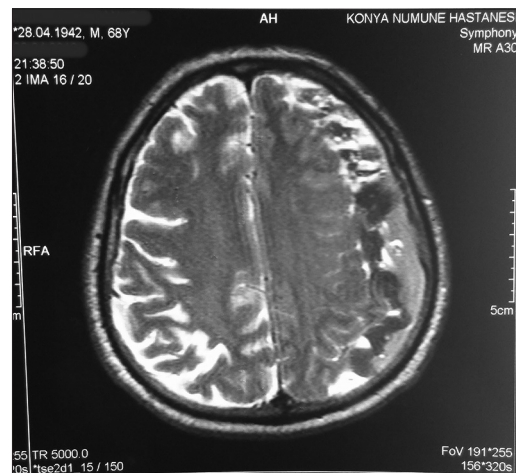


Figure 2: T2-weighted magnetic resonance imaging showing multiple intrahematoma loculations with hypointense web-net-like structure within the left hemispheric organized chronic subdural hematoma

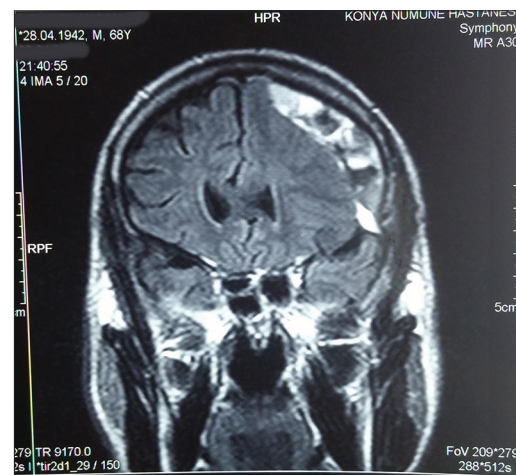


Figure 3: Preoperative T1-weighted magnetic resonance imaging showing multiple intrahematoma loculations with hypointense web-net-like structure within the left hemispheric organized chronic subdural hematoma

recognizable, we remove the hematoma by a gentle inject of physiologic saline solution. The inner membrane of the hematoma is progressively separated from an underlying arachnoid layer only by the water inject. This strategy avoids any traction on the cortical surface. No attempt should be made to remove by traction the membranes tenaciously adherent to the arachnoid surface or surrounding the bridge veins, but they are simply left *in situ*. A closed drainage system was left in the subdural space for 24–72 h postoperatively, and the treatment consisted of nursing in a flat position, administration of fluids, and supplemental breathing of 100% O₂.

All patients underwent sequential CT scans immediately after operation, and before discharge CT scan was done to quantify the decrease in the hematoma thickness, and to diagnose pneumocephalus and postoperative subdural, epidural, subarachnoidal, and intracerebral hemorrhage [Figures 4-7].

More frequent CT scans were taken if the patients showed unexpected neurological deterioration.

Simple aspiration of air through the skin incision using a syringe was applied for patients who have large epidural air.

Simple pneumocephalus did not require any specific treatment [Figure 8].

Statistical analysis

Data were analyzed using Statistical Package for the Social Sciences (SPSS) software package version 18.0 (SPSS, Chicago, IL, USA). Qualitative data were expressed in frequency and percentage. Qualitative data were analyzed using Fisher's exact test to compare different groups. Odds ratio was calculated to predict the risk factor. *P* value was assumed to be statistically significant at ≤ 0.05 .

Results

Between 1998 and 2015, 148 consecutive patients were surgically treated for CSDH at our institution. Of these, 28 patients which have OSDH underwent a large craniotomy with extended membranectomy as the initial treatment.

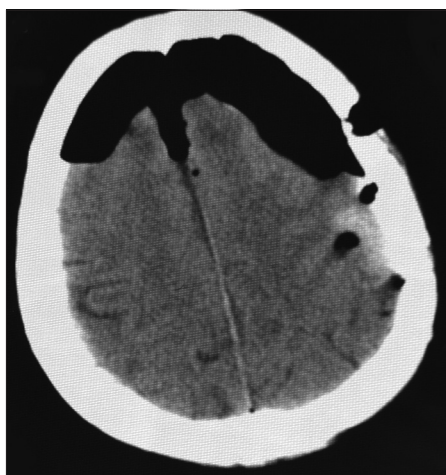

Figure 4: Computed tomography appearance of tension pneumocephalus

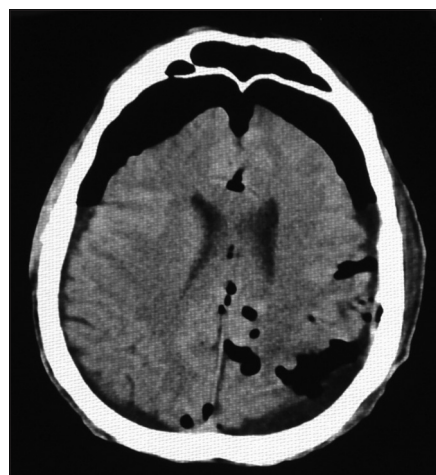

Figure 5: Computed tomography appearance of tension pneumocephalus with multiple small air bubbles in the subarachnoid space

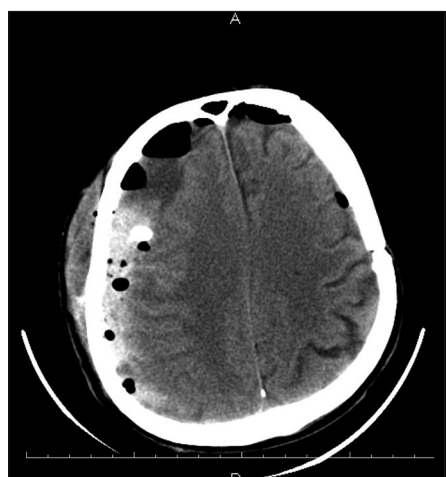

Figure 6: Computed tomography appearance of tension pneumocephalus with residual subdural hemorrhage

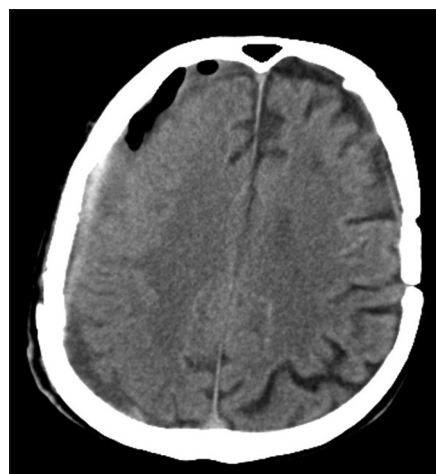


Figure 7: Simple pneumocephalus

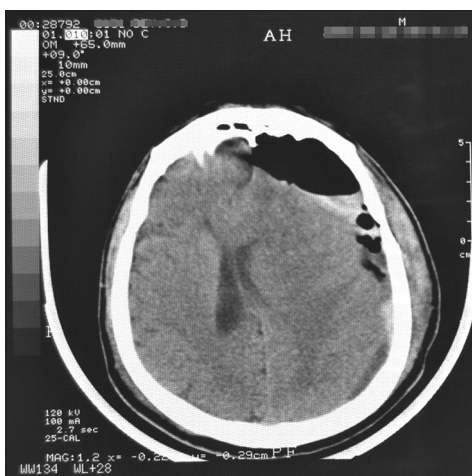


Figure 8: Left hemispheric the large epidural air

Of these 148 patients, 120 (81%) received one or two burr holes with drainage including 88 males and 32 females. The average age of these burr hole patients was 62.9 ± 16.8 years.

Of the remaining 28(19) patients undergoing craniotomy, there were 24 men and 4 women, and the mean age was 69 years (69.4 ± 12.1), with a range of 28–84 years.

Patient selection for craniotomy in groups

Based on CT [Figure 1] and/or MRI [Figures 2 and 3] findings, nonliquefied hematomas within CSDH, multilayer intrahematoma loculations, or thickened calcified membranes with heterogeneous structures in the hematoma cavity were selected for large craniotomies.

The major symptoms at first examination in OSDH groups were disturbance of consciousness ($n = 9$), headache ($n = 8$), motor deficits ($n = 6$), epilepsy ($n = 2$), and dysphasia ($n = 3$).

Pneumonia and deep vein thrombosis were seen in six cases.

Tension pneumocephalus (TP) was observed in eight patients on CT (28.5% of the cases) [Figures 4 and 5].

TP was related to the patient’s age (>60) [Table 2].

TP with a recurring subdural hemorrhage (RSH) was seen in 4 of 8 patients ($n = 8.50\%$) [Figure 6].

Simple pneumocephalus was seen in twenty patients (71.5%) [Figure 7].

TP was treated with closed subdural drainage system.

Large epidural air was seen in one case [Figure 8].

TP with RSH was seen in 4 of 8 patients ($n = 28.50\%$). TP and TP with RSH had a negative effect on postoperative neurological status and extended the length of hospital stay [Table 3], but mortality rate was not affected.

Four patients died within 28 days after surgery. The operative mortality rate in all these patients ($n = 28$) was

Table 2: Tension pneumocephalus relationship with age of the patients

Age	TP		MSA	
	<i>n</i>	%	<i>n</i>	%
<60	1	25	23	95,8
>60	3	75		4,2
F Ep				* <i>P</i> : 0,004
OR (95% CI)				0,014 (0,0007-0,29)

Table 3: Length of hospital stay after surgery

	TP		MSA	
	<i>n</i>	%	<i>n</i>	%
<10 days	1	12,5	15	75
≥ 10 days	7	87,5	5	25
F Ep				* <i>P</i> : 0,004
OR (95% CI)				0,0476 (0,0046-0.487)

Table 4: Death rates by 60-year age groups

	Recovery		Exitus	
	<i>n</i>	%	<i>n</i>	%
<60 age	23	82,1	1	25
≥ 60 age	5	17,9	3	75
F Ep				* <i>P</i> : 0,039
OR (95% CI)				13,8 (1.1776-161.7195)

Table 5: Mortality relationship with preoperative Markwalder’s scores of the patients

	Recovery		Exitus	
	<i>n</i>	%	<i>n</i>	%
Good (0-2)	23	82	1	28
Bad (3-4)	5	18	3	75
F Ep				* <i>P</i> : 0,039
OR (95% CI)				0,0725 (0.0062-0.8492)

14.28%. The causes of death were pneumonia, deep vein thrombosis, and pulmonary emboli.

The average stay in the Department of Neurosurgery was 11 days, ranging from 7 to 28 days. The average hospital stay for all operated patients was 11 (± 4) days. Length of hospital stay increased after TP complication.

Simple aspiration of air through the skin incision using a syringe was tried for one patient who has large epidural air, and these patients showed a favorable outcome within hours after aspiration.

Postoperative seizures requiring medical therapy occurred in 25% of our patients ($n = 7$).

Four patients died within 28 days after surgery. The operative mortality rate in all these patients ($n = 28$) was 14.28%. Poor prognosis was related to the patients’ age (>60) with a clinical grade on admission (grades 3–4)

[Tables 4 and 5]. The causes of death were pneumonia, deep vein thrombosis, and pulmonary emboli.

Discussion

For the initial management of CSH, numerous surgical treatments have been proposed.^[10,11] However, the extent of surgical treatment required for CSH is still controversial,^[12] and the optimal treatment for CSH is not well defined.^[11] The choice of surgical technique for CSH must be dictated by the levels of organization of the hematoma.^[6] Burr hole with drainage is mandatory for nonseptated and mostly liquified CSH.^[9,13-16] Although CSH is well known as a curable disease in the elderly and can be adequately managed with burr holes with drainage, the initial treatment of CSH can be ineffective. The reason behind the failure of this procedure should be viewed in the light of a number of factors: excessive formation of solid neomembrane,^[5] multilayered intrahematoma architecture nonliquefied hematoma with different hemorrhagic foci with layering effects.^[8] Some authors reported that small craniotomy with irrigation and closed system drainage can be considered as one of the treatment options in patients with CSDH.^[17-19] Conversely, craniotomy is generally accepted as the optimal approach for OCSH, reaccumulation of a CSH, existence of a solid hematoma, failure of brain reexpansion, or marked swelling subjacent to the hematoma.^[5,6,20,21] In OCSH cases, a two burr hole craniotomy cannot be considered as the solution of initial choice.^[6,7,18] We have treated, these cases, by craniotomy in the conviction of the need to achieve the widest possible membranectomy. Many authors reported that OSDH required a large craniotomy for the initial treatment.^[5-7,22]

Large craniotomies for OSDH provided a superior and safer opportunity to adequately deal with the hematoma, its membranes, and occasional troublesome bleeding.^[5,6,18,22] Extended outer and inner membranectomy is very important for brain expansion for subdural space.^[5,21,22] The outer membrane is related to hematoma enlargement because of the repetitive hemorrhages,^[2,23] whereas the inner membrane is related to liquefaction of the subdural hematoma.^[2,3] Extended inner membrane resection may facilitate the brain's expansion into the subdural space.^[5,6] Brain stiffness has been thought to be a factor affecting brain reexpansion after the evacuation of CSH.^[20] Partial inner membrane resection for OCSH may cause brain herniation.^[24] Brain herniation through the internal subdural membrane rarely occurs as a complication of OCSH.^[24-26]

Recurrence rate for RSH after craniotomy with membranectomy was 10.7%. The cause of RSH in these patients treated by large craniotomy was the fragile sinusoidal vessels that are present at the junction of inner and outer membranes, provoking repeated multifocal hemorrhages had not been coagulated adequately.^[6,7] The other reason of TP with RSH is of stretching and rupturing of bridging veins entering the superior sagittal sinus.^[27]

RSH after craniotomy was drained by a closed drainage system that was left in the subdural space for 24–72 h. Some authors have reported 3%–37% a recurrence rate after burr hole drainage for CSDH, but these cases needed a second surgery for recurring subdural hemorrhage (RSH).^[5,7,12,22,28-30] Among the most frequently confirmed causes of recurrence is the presence of thick membranes in the hematoma, which lead to a higher recurrence rate.^[5,7] Occasionally, advanced age has been considered to be a risk factor for recurrence after CSDH operations,^[16,18] but most studies have demonstrated no relationship between recurrence rate and age.^[12,31-33]

Pneumocephalus is the presence of air in the cranial cavity. When this intracranial air causes increased intracranial pressure and leads to neurological deterioration, it is known as TP. TP can be a major life-threatening postoperative complication, especially after evacuation of CSH.^[34] Pneumocephalus is commonly encountered after neurosurgical procedures, especially CSH drainage^[33,35-42] but can also be caused by craniofacial trauma^[43] and tumors of the skull base^[40] and rarely can occur spontaneously.^[44] Contributing factors for the development of pneumocephalus include head position, duration of surgery, nitrous oxide (N₂O) anesthesia,^[45,46] hydrocephalus, intraoperative osmotherapy, hyperventilation, spinal anesthesia, barotrauma, continuous cerebrospinal fluid drainage through lumbar drain or shunting system,^[40,47] epidural anesthesia, infections, dural defect after craniotomy,^[48] tear of arachnoid membrane,^[38,49] and neoplasms. Clinical complaints include headaches, nausea and vomiting, seizures, dizziness, and depressed neurological status.^[32,33,37,50] The subdural tensile air separates and compresses the frontal lobes. The typical “peaking” of the frontal lobes in subdural TP is explained by bridging veins entering the superior sagittal sinus. Stretching and rupturing of these veins may be implicated as a cause for a RSH.^[27] The compressed frontal lobes with widened interhemispheric space between the frontal poles mimic the silhouette of Mt. Fuji. Some neurosurgeons called this CT finding “Mt. Fuji” sign.^[51] The presence of air between the frontal poles associated with massive air over the frontal lobes presumably indicates an increased tension of the subdural air. Another sign is the presence of multiple small air bubbles in the subarachnoid space, especially in the cisterns.

The incidence rate of TP after craniotomy with membrane excision in our patient population was 28.5%. The incidence rate of TP after burr hole drainage was 4%–8%.^[41] Some authors reported TP complications after large craniotomy.^[52]

It is reported that these air bubbles enter the subarachnoid space through a tear in the arachnoid membrane caused by increased tension of air in the subdural space.^[38] Several authors emphasized that using a saline solution jet at the reflection zone of the hematoma avoids injury to the underlying arachnoid surface and newly formed capillaries during removal of the membranes.^[6,7] Careful hemostasis

and complete replacement of subdural hematoma by normal saline to prevent influx of air into the subdural space may further improve the surgical outcome for patients with CSDH.^[30] After evacuation of organized chronic hematoma in the elderly, the expansion of the brain into the subdural space may be insufficient.^[20] In these cases, the negative pressure effect contributes to the formation of TP.

Controlled decompression through a closed water-seal drainage system was applied to the patients for 2 days.^[31] The treatment consisted of nursing in a flat position, administration of fluids, and supplemental breathing of 100% O₂.^[3,44,52,53] Simple aspiration of air through the skin incision using a syringe was applied on one patient who had large subdural air.^[52]

Postoperative seizures requiring medical therapy occurred in 25% of our patients ($n = 28$). After large craniotomy, some studies reported 50% postoperative seizure.^[6,7]

Subarachnoidal hemorrhage, intracerebral hemorrhage, hygroma, and subdural empyema were not observed in our cases.

In-hospital mortality rate in our study was 14.3%. Some studies reported 0%–15.6% mortality rate.^[12,28,54] Most of the deaths in this series were due either to CSDH or to the complications of frailty and poor mobility in elderly,^[1,12,28,54] but in the nonoperated group, mortality was 44%.^[1] Surgery itself was generally successful.^[1] Poor prognosis was related to patient's age (>60) and clinical grade on admission (Grades 0–2 vs. Grades 3–4).^[54,55]

Craniotomy for evacuation of a hemorrhage, hematoma, or removal of the membranes for OSDH has long been viewed as dangerous for elderly patients^[8] although outcomes have improved enormously over the past 30 years with the advent of more sophisticated imaging systems, faster diagnoses, and better surgical techniques.

Conclusion

Large craniotomy and extended membrane excision for OSDH still carry a high rate of mortality and morbidity. This is mainly because of the absence of a codified and universally accepted technique of membranectomy. TP, RSH, and postoperative seizures are frequently seen complications in elderly patients.

Financial support and sponsorship

Nil.

Conflicts of interest

There are no conflicts of interest.

References

- Acakpo-Satchivi L, Luerssen TG. Brain herniation through an internal subdural membrane. A rare complication seen with chronic subdural hematomas in children. Case report. *Journal of Neurosurgery* 2007;107:485-88.
- Aoki N, Sakai T. Computed tomography features immediately after replacement of haematoma with oxygen through percutaneous subdural tapping for the treatment of chronic subdural haematoma in adults. *Acta Neurochir (Wien)* 1993;120:44-6.
- Araújo Silva DO, Matis GK, Costa LF, Kitamura MA, de Carvalho Junior EV, de Moura Silva M, *et al.* Chronic subdural hematomas and the elderly: Surgical results from a series of 125 cases: Old "horses" are not to be shot! *Surg Neurol Int* 2012;3:150.
- Arbit E, Shah J, Bedford R, Carlon G. Tension pneumocephalus: Treatment with controlled decompression via a closed water-seal drainage system. Case report. *J Neurosurg* 1991;74:139-42.
- Asghar M, Adhiyaman V, Greenway MW, Bhowmick BK, Bates A. Chronic subdural hematoma in the elderly - A north wales experience. *J R Soc Med* 2002;95:290-2.
- Black PM, Davis JM, Kjellberg RN, Davis KR. Tension pneumocephalus of the cranial subdural space: A case report. *Neurosurgery*.1979;5:368-70.
- Bouzarth WF, Hash CJ, Linderthum JR. Tension pneumocephalus following surgery for subdural hematoma. *J Trauma* 1980;20:460-3.
- Bremer AM, Nguyen TQ. Tension pneumocephalus after surgical treatment of chronic subdural hematoma: report of three cases. *Neurosurgery* 1982;11:284-7.
- Callovin GM, Bolognini A, Callovin G, Gammone V. Primary enlarged craniotomy in organized chronic subdural hematomas. *Neurol Med Chir (Tokyo)* 2014;54:349-56.
- Chung WY, Lee LS, Huang CI, Shoung HM. Tension pneumocephalus. Report of four cases. *Zhonghua Yi Xue Za Zhi (Taipei)* 1987;40:563-8.
- Cummins A. Tension pneumocephalus is a complication of chronic subdural hematoma evacuation. *J Hosp Med*. 2009;4:E3-4.
- Demetriades AK, Pretorius P, Stacey R. Progressive tension pneumocephalus as a delayed postoperative complication in the absence of any obvious CSF leak. *J Neurosurg Sci* 2010;54:109-11.
- Doglietto F, Sabatino G, Policicchio D. Transcranial cerebriherniation after chronic subdural hematoma treatment with no dura closure. *Neurology* 2006;67:493.
- Ernestus RI, Beldzinski P, Lanfermann H, Klug N. Chronic subdural hematoma: Surgical treatment and outcome in 104 patients. *Surg Neurol* 1997;48:220-5.
- Friedman GA. Nitrous oxide and the prevention of tension pneumocephalus after craniotomy. *Anesthesiology* 1983;58:196-7.
- Fukuhara T1, Gotoh M, Asari S, Ohmoto T, Akioka T. The relationship between brain surface elastance and brain reexpansion after evacuation of chronic subdural hematoma. *Surg Neurol*.1996;45:570-4.
- Gelabert-González M, Iglesias-Pais M, García-Allut A, Martínez-Rumbo R. Chronic subdural haematoma: Surgical treatment and outcome in 1000 cases. *Clin Neurol Neurosurg* 2005;107:223-9.
- Goodie D, Traill R. Intraoperative subdural tension pneumocephalus arising after opening of the dura. *Anesthesiology* 1991;74:193-5.
- Goyal S, Batra AM, Rohatgi A, Acharya R, Sharma AG. Tension pneumocephalus: a neurosurgical emergency. *J Assoc Physicians India* 2008;56:985.
- Hellwig D, Kuhn TJ, Bauer BL, List-Hellwig E. Endoscopic treatment of septated chronic subdural hematoma. *Surg Neurol* 1996;45:272-7.
- Imazumi S, Onuma T, Kameyama M, Naganuma H. Organized

- chronic subdural hematoma requiring craniotomy: Five case reports. *Neurol Med Chir (Tokyo)* 2001;41:19-24.
22. Ishiwata Y, Fujitsu K, Sekino T, Fujino H, Kubokura T, Tsubone K, *et al.* Subdural tension pneumocephalus following surgery for chronic subdural hematoma. *J Neurosurg* 1988;68:58.
 23. Isobe N, Sato H, Murakami T, Kurokawa Y, Seyama G, Oki S. Six cases of organized chronic subdural hematoma. *No Shinkei Geka* 2008;36:1115-20.
 24. Ito H, Yamamoto S, Komai T, Mizukoshi H. Role of local hyperfibrinolysis in the etiology of chronic subdural hematoma. *J Neurosurg* 1976;45:26-31.
 25. Kawakami Y, Tamiya T, Shimamura Y, Yokoyama Y, Chihara T. Tension pneumocephalus following surgical evacuation of chronic subdural hematoma. *No Shinkei Geka* 1985;13:833-7.
 26. Killeffer JA, Killeffer FA, Schochet SS. *Neurosurg Clin N Am.* The outer neomembrane of chronic subdural hematoma 2000;11:407-12.
 27. Kim JH, Kang DS, Kim JH, Kong MH, Song KY. Chronic subdural hematoma treated by small or large craniotomy with membranectomy as the initial treatment. *J Korean Neurosurg Soc* 2011;50:103-8.
 28. Ko BS, Lee JK, Seo BR, Moon SJ, Kim JH, KIM SH. Clinical analysis of risk factors related to recurrent chronic subdural hematoma. *J Korean Neurosurg Soc* 2008; 43:11-5.
 29. Kusano Y, Horiuchi T, Seguchi T, Kakizawa Y, Tanaka Y, Hongo K. Local brain herniation after partial membranectomy for organized chronic subdural hematoma in an adult patient: Case report and review of the literature. *Brain Inj* 2010;24:1118-21.
 30. Lee JK, Choi JH, Kim CH, Lee HK, Moon JG. Chronic subdural hematomas: A comparative study of three types of operative procedures. *J Korean Neurosurg Soc* 2009;46:210-4.
 31. Lee JY, Ebel H, Ernestus RI, Klug N. Various surgical treatment of chronic subdural hematoma and outcome in 172 patients: Is membranectomy necessary? *Surg Neurol* 2004;61:523-7.
 32. Lega BC, Danish SF, Malhotra NR, Sonnad SS. Choosing the best operation for chronic subdural hematoma: A decision analysis. *J Neurosurg* 2010;113:615-21.
 33. Markwalder TM, Steinsiepe KF, Rohner M, Reichenbach W, Markwalder H. The course of chronic subdural hematomas after burr-hole craniotomy and closed-system drainage. *J Neurosurg* 1981;55:390-6.
 34. Miranda LB, Braxton E, Hobbs J, Quigley MR. Chronic subdural hematoma in the elderly: Not a benign disease. *J Neurosurg* 2011;114:72-6.
 35. Mohamed EE. Chronic subdural hematoma treated by craniotomy, drectomy, outer membranectomy and subgaleal suction drainage. Personal experience in 39 patients. *Br J Neurosurg* 2003;17:244-7.
 36. Monajati A, Cotanch WW. Subdural tension pneumocephalus following surgery. *J Comput Assist Tomogr* 1982;6:902-6.
 37. Mondorf Y, Abu-Owaimer M, Gaab MR, Oertel JM. Chronic subdural hematoma - craniotomy versus burr hole trephination. *Br J Neurosurg* 2009;23:612-6.
 38. Mori K., Maeda M. Surgical treatment of chronic subdural hematoma in 500 consecutive cases: Clinical characteristics, surgical outcome, complications, and recurrence rate. *Neurologia Medico-Chirurgica* 2001;41:371-81.
 39. Muzii VF, Bistazzoni S, Zalaffi A, Carangelo B, Mariottini A, Palma L. Chronic subdural hematoma: Comparison of two surgical techniques. Preliminary results of a prospective randomized study. *J Neurosurg Sci* 2005;49:41-6.
 40. Oge K, Akpinar G, Bertan V. Traumatic subdural pneumocephalus causing rise in intracranial pressure in the early phase of head trauma: Report of two cases. *Acta Neurochir (Wien)* 1998;140:655-8.
 41. Okada Y, Akai T, Okamoto K, Iida T, Takata H, Iizuka H. A comparative study of the treatment of chronic subdural hematoma-burr hole drainage versus burr hole irrigation. *Surg Neurol* 2002;57:405-9.
 42. Paiva WS, de Andrade AF, Figueiredo EG, Amorim RL, Prudente M, Teixeira MJ. Effects of hyperbaric oxygenation therapy on symptomatic pneumocephalus. *Ther Clin Risk Manag* 2014;10:769-73.
 43. Pop PM, Thompson JR, Zinke DE, Hasso AN, Hinshaw DB. Tension pneumocephalus *J Comput Assist Tomogr* 1982;6:894-901.
 44. Reasoner DK, Todd MM, Scamman FL, Warner DS. The incidence of pneumocephalus after supratentorial craniotomy. Observations on the disappearance ce of intracranial air. *Anesthesiology* 1994;80:1008-12.
 45. Rocchi G, Caroli E, Salvati M, Delfini R. Membranectomy in organized chronic subdural hematomas: Indications and technical notes. *Surg Neurol* 2007;67:374-80.
 46. Sadeghian H. Mount Fuji sign in tension pneumocephalus. *Arch Neurol* 2000;57:1366.
 47. Schirmer CM, Heilman CB, Bhardwaj A. Pneumocephalus: Case illustrations and review. *Neurocrit Care* 2010;13:152-8.
 48. Sharma BS, Tewari MK, Khosla VK, Pathak A, Kak VK. Tension pneumocephalus following evacuation of chronic subdural haematoma. *Br J Neurosurg* 1989;3:381-7.
 49. Suda K, Sato M, Matsuda M, Handa J. Subdural tension pneumocephalus after trephination for chronic subdural hematoma. *No To Shinkei* 1984;36:127-30.
 50. Tanikawa M, Mase M, Yamada K, Yamashita N, Matsumoto T, Banno T, *et al.* Surgical treatment of chronic subdural hematoma based on intrahematoma membrane structure on MRI. *Acta Neurochir (Wien)* 2001;143:613-18.
 51. Tyson G, Strachan WE, Newman P, Winn Hr, Butler A, Jane J. The role of craniectomy in the treatment of chronic subdural hematomas. *J Neurosurg* 1980;52:776-81.
 52. Yamao N, Sasaki T, Watanabe Z, Watanabe M, Tanji H, Kodama N, *et al.* Case of postoperative subdural tension pneumocephalus. *No Shinkei Geka* 1984;12:841-6.
 53. Yamashita T, Yamamoto S. How do vessels proliferate in the capsule of a chronic subdural hematoma? *Neurosurgery* 1984;15:672-8.
 54. Yamashita T. The inner membrane of chronic subdural hematomas: pathology and pathophysiology. *Neurosurg Clin N Am* 2000;11:413-24.
 55. Zidan Ihab. Pneumocephalus after surgical evacuation of chronic subdural hematoma: Is it a serious complication? *Asian J Neurosurg* 2012;7:66-74.