

Endoscopic Endonasal Transsphenoidal Approach for Resection of Tuberculum Sella and Planum Sphenoidale Meningiomas: A Snapshot of Our Institutional Experience

Abstract

Introduction: Meningiomas of the tuberculum sellae and planum sphenoidale represent a subgroup of anterior skull base tumors that comprise approximately 5%–10% of all intracranial meningiomas. Most of the patients report with failing vision, so early surgical decompression either transcranial and/or endonasal approach is recommended. The endonasal route allows for direct coagulation of the tumor meningeal supply and extensive resection of dural attachments, and importantly, provides an inferior to superior access to the infrachiasmatic region that facilitates complete tumor removal without encountering the optic nerve. This article describes our institutional experience for the endonasal resection of tuberculum sellae and planum sphenoidale meningiomas. **Materials and Methods:** We retrospectively analyzed eight cases of tuberculum sellae and planum sphenoidale meningiomas who selectively underwent endoscopic endonasal transsphenoidal resection between 2015 and 2018. All patients had ophthalmological, endocrinological, and radiological evaluation both preoperatively and postoperatively. **Results:** Among the study group, we found age range 22–68 years, male:female 1:2. Among the radiological findings, there were five cases of tuberculum sellae meningioma, while three cases were of planum sphenoidale meningioma. In tumor resection status, we found gross total resection in six cases and debulking in two cases. Postoperative analysis of visual outcome revealed improvement in four cases, constant in three cases, and worsening in one case. We also found the post of nasal complications in four cases, cerebrospinal fluid leak in two cases and transient diabetes insipidus in one case. **Conclusion:** In this study, we highlighted our experience of a very small group of patients with anterior fossa meningioma specific to tuberculum sella and planum sphenoidale origin.

Keywords: Endoscopic endonasal approach introduction, planum sphenoidale, tuberculum sellae

**Md Al Amin Salek,
Md Hasnain Faisal,
Md Abdul Hye Manik,
Ahmed-UI-Mursalin
Choudhury,
Rukun Uddin
Chowdhury,
Md Aminul Islam**

*Department of Neurosurgery,
Combined Military Hospital,
Dhaka, Bangladesh*

Introduction

Tuberculum sella and planum sphenoidale meningiomas represent 5%–10% of intracranial meningiomas and arise from tuberculum sella and planum sphenoidale of anterior skull base region.^[1] Tuberculum sellae meningiomas are located in close proximity of optic chiasma and thus play a significant role in vision impairment. On the other hand, planum sphenoidale meningioma is located more anterior and in proximity of the olfactory groove location.

The mean age at diagnosis is in the fourth decade, and women are more affected by this pathology. Due to the constant anatomical relationship of these tumors with the optic nerves, there is a classic presentation of these tumors represented

by the chiasmal syndrome, a primary optic atrophy with bitemporal field defects in adult patients with a radiologically normal sellae. Surgical decompression is the mainstay of treatment.^[2]

In this study, we have presented our surgical experience in the treatment of eight patients with tuberculum sellae and planum sphenoidale meningiomas using endoscopic endonasal transsphenoidal approach.

Materials and Methods

We retrospectively analyzed eight cases of anterior fossa meningioma specific to tuberculum sella and planum sphenoidale origin, who underwent endoscopic endonasal transsphenoidal (transtuberular-transplanum) approach between 2015

Address for correspondence:

*Dr. Md Al Amin Salek,
Department of Neurosurgery,
Combined Military Hospital,
Dhaka, Bangladesh.
E-mail: salek1972@yahoo.com,
aamin72@gmail.com*

Access this article online

Website: www.asianjns.org

DOI: 10.4103/ajns.AJNS_85_19

Quick Response Code:



This is an open access journal, and articles are distributed under the terms of the Creative Commons Attribution-NonCommercial-ShareAlike 4.0 License, which allows others to remix, tweak, and build upon the work non-commercially, as long as appropriate credit is given and the new creations are licensed under the identical terms.

For reprints contact: reprints@medknow.com

How to cite this article: Salek MA, Faisal MH, Manik MA, Choudhury AU, Chowdhury RU, Islam MA. Endoscopic endonasal transsphenoidal approach for resection of tuberculum sella and planum sphenoidale meningiomas: A snapshot of our institutional experience. *Asian J Neurosurg* 2020;15:22-5.

Submission: 04-04-2019 **Accepted:** 19-06-2019
Published: 25-02-2020

and 2018 at the Neurosurgery Department of Combined Military Hospital, Dhaka, Bangladesh. We excluded those cases who underwent craniotomy, large tumor extending beyond midpupillary line. Indications for endoscopic approaches were tumors situated on the midline with or without extension into the optic canal and vessel encasement. All the patients in the study group had been examined preoperatively with computed tomography (CT) and Magnetic resonance imaging (MRI) studies. We considered tuberculum sellae meningiomas the ones located on the small surface between the chiasmatic sulcus and diaphragma sellae and planum sphenoidale meningioma, the ones localized more anteriorly near to the olfactory groove location. Ophthalmological and endocrinological evaluations had been done both preoperatively and postoperatively.

Surgical steps

The procedure was done under general anesthesia with orotracheal intubation. Patient was placed in supine position and head was fixed by Mayfield head clamp tilting to the left, and the torso was elevated gently. Fascia lata and free fat graft being prepared from the thigh. The patient together with the endoscopic/video camera equipment being draped with aseptic techniques. The nasal cavity was prepared with adrenalin (1:1000) soaked cottonoids for at least 5 min to decrease bleeding. Preoperatively, we assessed the state of hyperostosis by CT scan to anticipate the use of high-speed drill. We used 4-mm rigid endoscopes with 0° and 30° angled lenses using both nostrils. Surgical corridor was created by doing middle turbinectomy, creation of Hadad flap with the removal of both posterior bony septum and anterior cartilaginous septum, shoulder osteotomy, and removal of vomer.

Skull base defect reconstruction was done with fat, fascia lata, nasoseptal flap, and reinforced with platelet-rich fibrin.

Postoperative management

Patients were electively kept in critical care center for postoperative management. Hourly urine output to rule out diabetes insipidus. Biochemical and endocrine review was done for electrolytes, serum osmolality, and pituitary hormone profile.

Follow up protocol

Clinical, endocrinological, and radiological follow-up was done initially 3 monthly and 6 monthly for 2 years and then every yearly to rule out any recurrence.

Results

Table 1 shows the distribution of the age group of 8 patients with ages between 31 and 64 years.

In Figure 1, we observed greater prevalence in women than men.

Table 1: Distribution of age

Age range	n
31-40	2
41-50	3
51-60	2
61+	1

Table 2: Radiological findings

Localization	n
Tuberculum sellae	5
Planum sphenoidale	3
Internal carotid encasement	1
Involvement of the optic canal	4

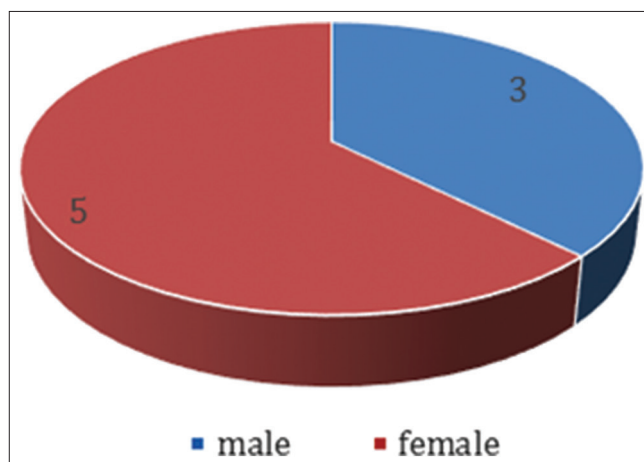


Figure 1: Distribution of sex

As shown in Table 2, we put the preoperative radiological findings.

As shown in Figure 2, the outcome of visual disturbances was analyzed, improved in four cases, in three cases, the visual deficit remained constant, and in one case the visual deficit worsened postoperatively.

Resection status of tumor revealed complete resection of tumor in six cases and subtotal resection in two cases, as shown in Figure 3.

In Table 3, we found the post of complications with nasal complications including encrustation, synechiae, and anosmia found in four cases, two patients developed cerebrospinal fluid (CSF) leak that was managed conservatively, a tumor recurrence in one and transient DI in one case.

Case illustration

In Figure 1, it was observed that male patient (5) was more than female patient (3). A 35-year-old nonpregnant female having gradual impairment of vision in both eyes for 6 months. Visual field analysis revealed complete vision loss in the right eye and up to finger count in the left eye [Figure 4a-d]. MRI of the brain with contrast revealed

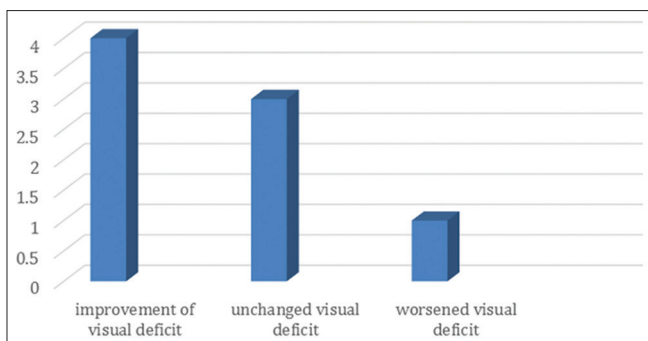


Figure 2: Distribution of outcome of visual disturbances

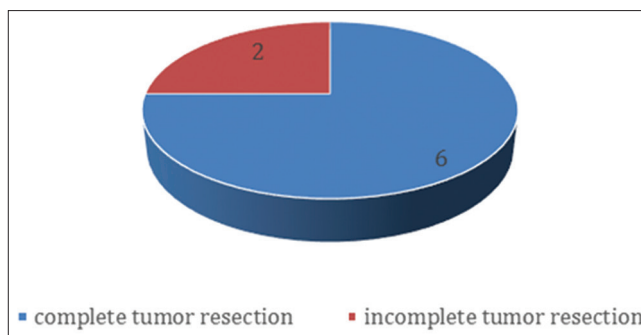


Figure 3: Distribution of resection status

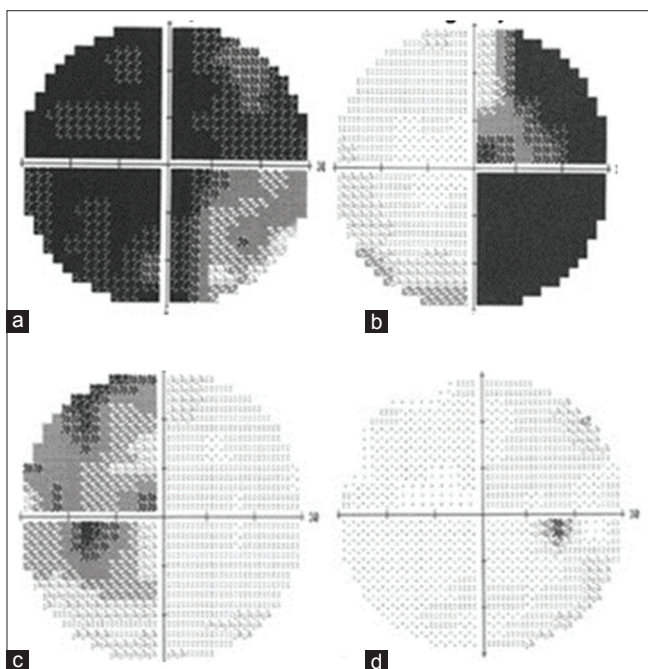


Figure 4: Ophthalmological illustration, preoperative (a and b) and postoperative (c and d)

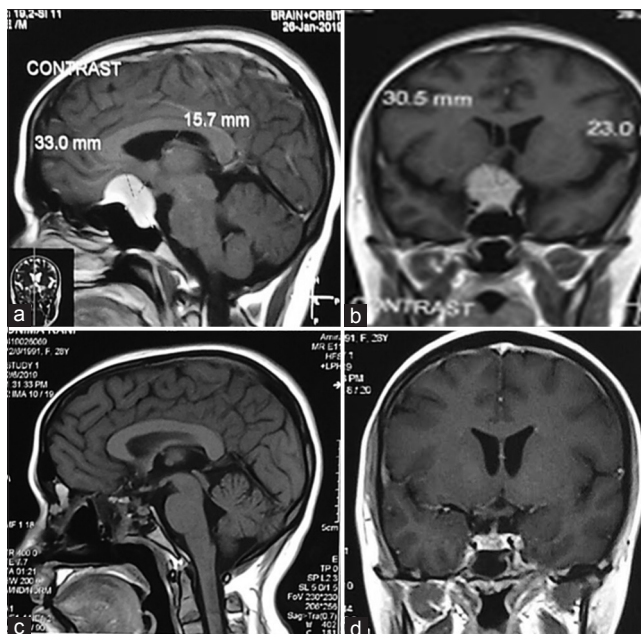


Figure 5: Radiological illustration of a case of a tuberculum-planum meningioma, preoperative (a and b) and postoperative (c and d)

Table 3: Distribution of post op complications

Complications	n
Nasal complications	4
CSF rhinorrhea	2
Tumor recurrence	1
Transient diabetes insipidus	1
CSF – Cerebrospinal fluid	

tuberculum sella and planum sphenoidale meningioma severely compressing the optic chiasm [Figure 5a-d]. Endoscopic endonasal transtubercular-transplanum removal tumor was done [Figure 6a-c].

Discussion

Tuberculum sella and planum sphenoidale meningioma present a frequently encountered pathology of the anterior skull base that gives rise to an early visual pathology with relatively slow progression, but due to the fact that other symptoms are

missing or are subtle, they have a larger tendency to develop undiagnosed for longer periods of time.^[3,4]

In our study, we have included both tuberculum sellae and planum sphenoidale meningiomas as the anatomical landmarks are very close to each other, they displace the optic apparatus in a similar fashion and were operated with the same endoscopic endonasal technique. Although there is some limitation of the surgical corridor through endoscopic endonasal transsphenoidal approach, removal of medial portion of lesser wing and anterior clinoid process increase the exposure and surgical freedom of the expanded endonasal approach.^[5]

There are cases described in the literature of tuberculum sellae meningiomas misinterpreted as pituitary macroadenomas, but this was not the case in our study.^[6]

Out of the eight cases operated, four cases presented an improvement of the visual acuity while in three cases the visual acuity remained stable, overall this results in a

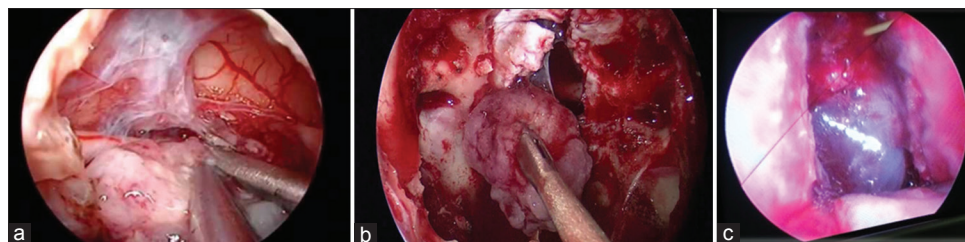


Figure 6: Intraoperative removal of tumor (a and b) and reconstruction of skull base defect (c)

stabilization of the preoperative visual acuity in over 88% of the treated cases, a percentage that is in accordance with endoscopic resection presented in the literature.^[7,8]

Complete tumor removal was achieved in 75% of cases, which is well between the described 56%–100% margins found in the literature.^[9]

CSF leak and recurrence of the tumors were low, and we believe this is due to the relatively small number of patients included in the study.

Studies have shown that patients treated through extended endoscopic approaches might benefit from better rates of complete surgical resection, and visual outcome with preservation of olfaction, less CSF leakage with visual improvement.^[10]

Conclusion

As per literature, endoscopic endonasal transsphenoidal resection can be considered as a standard surgical option of tuberculum sella and planum sphenoidale meningioma management and visual recovery. In this study, we highlighted our experience of a very small group of patients with anterior fossa meningioma specific to tuberculum sella and planum sphenoidale origin.

Financial support and sponsorship

Nil.

Conflicts of interest

There are no conflicts of interest.

References

1. Chi JH, McDermott MW. Tuberculum sellae meningiomas.

Neurosurg Focus 2003;14:e6.

2. Fernandez-Miranda JC, Pinheiro-Nieto C, Gardner PA, Snyderman CH. Endoscopic endonasal approach for a tuberculum sellae meningioma. *J Neurosurg* 2012;32 Suppl: E8.
3. Fahlbusch R, Schott W. Pterional surgery of meningiomas of the tuberculum sellae and planum sphenoidale: Surgical results with special consideration of ophthalmological and endocrinological outcomes. *J Neurosurg* 2002;96:235-43.
4. Jallo GI, Benjamin V. Tuberculum sellae meningiomas: Microsurgical anatomy and surgical technique. *Neurosurgery* 2002;51:1432-39.
5. Di Somma A, Torales J, Cavallo LM, Pineda J, Solari D, Gerardi RM, *et al.* Defining the lateral limits of the endoscopic endonasal transtuberulum transplanum approach: Anatomical study with pertinent quantitative analysis. *J Neurosurg* 2018;130:848-6.
6. Fatemi N, Dusick JR, de Paiva Neto MA, Malkasian D, Kelly DF. Endonasal versus supraorbital keyhole removal of craniopharyngiomas and tuberculum sellae meningiomas. *Neurosurgery* 2009;64:269-84.
7. Bander ED, Singh H, Ogilvie CB, Cusic RC, Pisapia DJ, Tsiouris AJ, *et al.* Endoscopic endonasal versus transcranial approach to tuberculum sellae and planum sphenoidale meningiomas in a similar cohort of patients. *J Neurosurg* 2018;128:40-8.
8. Kitano M, Taneda M, Nakao Y. Postoperative improvement in visual function in patients with tuberculum sellae meningiomas: Results of the extended transsphenoidal and transcranial approaches. *J Neurosurg* 2007;107:337-46.
9. López F, Suárez V, Costales M, Rodrigo JP, Suárez C, Llorente JL. Endoscopic endonasal approach for the treatment of anterior skull base tumours. *Acta Otorrinolaringol Esp* 2012;63:339-47.
10. Ottenhausen M, Banu MA, Placantonakis DG, Tsiouris AJ, Khan OH, Anand VK, *et al.* Endoscopic endonasal resection of suprasellar meningiomas: The importance of case selection and experience in determining extent of resection, visual improvement, and complications. *World Neurosurg* 2014;82:442-9.