

Favorable Outcome of Endovascular Treatment for Intracranial Aneurysms: A Single-Center Study in Thailand

Abstract

Purpose: The purpose of this study is to collect the information on patients with intracranial aneurysm (IA) receiving endovascular management in Siriraj Hospital, Mahidol University, Thailand. **Materials and Methods:** We retrospectively reviewed data from patients with IA who underwent endovascular treatment from January 1997 through July 2013. We collected patients' demographic data including age, sex, clinical presentations, and aneurysmal profiles, as well as endovascular treatment technique, complications, angiographic results, and regrowth rate. Treatment results included success rate, clinical findings during follow-up, and regrowth rate. **Results:** We reviewed data from 497 patients with 636 aneurysms (female:male ratio, 1.9:1; age range, 15–90 years; mean age, 59.18 years) and 69% presented with rupture. One hundred and twenty patients with 127 aneurysms received endovascular treatment. The most common location for endovascular treatment was the posterior communicating artery (15.8%), and endovascular techniques were used most often for posterior circulation and paraclinoid aneurysms. The success rate was approximately 99.2% with a 16.5% regrowth rate and no rebleeding. Regrowth rate did not correlate with immediate postoperative angiographic findings. We encountered 23 complications (18.1%); most commonly, intra-procedural rupture (7/23). Good outcomes occurred in approximately 95.9% of the patients. **Conclusions:** The success rate for endovascular treatment was >90%. Regrowth rate and clinical outcomes were within standard limits. Posterior circulation and paraclinoid aneurysms were our main targets. We tended to use fewer devices and simpler techniques to secure ruptured IA; however, the regrowth rate was similar to that using device-assisted techniques in other studies. We found no significant factors affecting regrowth rate, including immediate posttreatment angiographic results.

Keywords: Aneurysm, angiography, endovascular, stent

Introduction

Intracranial aneurysm (IA) is a major cause of nontraumatic subarachnoid hemorrhage, which is associated with high mortality and morbidity. Surgical clipping was the standard treatment for aneurysms until the introduction of a detachable coil system by Guglielmi *et al.* in 1991. This embolization procedure is effective with results equivalent to traditional microsurgery but is a less invasive method.^[1] Endovascular coiling is now used more often for IAs, and the development of new endovascular techniques and devices is ongoing.^[2,3] According to the International Subarachnoid Aneurysm Trial, endovascular coiling was associated with a better prognosis than surgical treatment, with an absolute risk reduction of 7.4%.^[4]

In our institute, Siriraj Hospital, endovascular coiling to treat IAs began

in 1997. The purpose of this study was to evaluate the angiographic outcomes of endovascular treatment for IAs in our hospital.

Materials and Methods

Patient characteristics

We retrospectively reviewed the medical records of 525 patients with nontraumatic IAs who had catheter angiographic studies at Siriraj Hospital between January 1997 and July 2013. We excluded patients with mycotic aneurysms and vasculitis and included 497 patients. Demographic data and clinical presentations were recorded for each patient, and the patient status was defined using the modified Rankin scale (mRS) at initial presentation and follow-up. The characteristics of all aneurysms were evaluated using digital subtraction angiography for their location, shape, size, and dome-to-neck ratio.

This is an open access journal, and articles are distributed under the terms of the Creative Commons Attribution-NonCommercial-ShareAlike 4.0 License, which allows others to remix, tweak, and build upon the work non-commercially, as long as appropriate credit is given and the new creations are licensed under the identical terms.

For reprints contact: reprints@medknow.com

How to cite this article: Withayasuk P, Churojana A, Songsaeng D, Aurboonyawat T, Chankaew E. Favorable outcome of endovascular treatment for intracranial aneurysms: A single-center study in Thailand. *Asian J Neurosurg* 2018;13:721-9.

Pattarawit Withayasuk, Anchalee Churojana, Dittapong Songsaeng, Taweasak Aurboonyawat¹, Ekawut Chankaew¹

Department of Radiology, Interventional Neuroradiology Unit, Siriraj Hospital, Mahidol University, ¹Department of Surgery, Neurosurgery Unit, Siriraj Hospital, Mahidol University, Bangkok, Thailand

Address for correspondence:

Dr. Pattarawit Withayasuk, Department of Radiology, Interventional Neuroradiology Unit, Siriraj Hospital, Mahidol University, Bangkok, Thailand. E-mail: dorawit@gmail.com

Access this article online

Website: www.asianjns.org

DOI: 10.4103/ajns.AJNS_70_18

Quick Response Code:



Endovascular procedure and technique

There were 127 aneurysms in 120 patients who had undergone endovascular treatment under general anesthesia. The characteristics and the best projection of the aneurysms were obtained from digital subtraction angiography at the time of the procedure. The goal of the treatment was to exclude the aneurysmal sac from circulation as completely as possible. Initially, a simple technique using detachable coils with a single microcatheter was planned if there was no anticipated technical difficulty or technical limitation; otherwise, additional devices or a flow diverter were considered. The procedure ended when angiographically complete occlusion was confirmed or when the last coil could not be safely introduced into the aneurysmal sac.

Data analysis was performed for the embolization technique, angiographic results, aneurysmal regrowth rate, patient outcome, and treatment complications. Angiographic results were classified as complete obliteration, subtotal obliteration (residual aneurysmal neck), and incomplete obliteration (residual aneurysmal sac or remnant) [Figure 1].^[5-7]

Aneurysmal regrowth was assessed at every follow-up by angiography at 3, 6, and 12 months and 2–5 years, except in the unruptured group, for whom follow-up began at 6 months. An aneurysm was considered to be regrowth if a previously treated aneurysm was found to recanalize or a residual remnant had increased in size on any follow-up angiography.

Patient outcome was assessed at the end of the procedure and during follow-up using the mRS and graded as good recovery, improvement, stable, or worse. Procedural complications were recorded and correlated with patient outcome.

Statistical analysis

The baseline characteristics of the aneurysms were compared between the group that included the entire study population and the group receiving endovascular treatment, using Fisher’s exact test and Student’s *t*-test, with *P* < 0.05 being considered statistically significant. Correlations between aneurysmal regrowth and therapeutic variables were evaluated by Chi-square test. Data management and all analyses were performed using PASW statistics 18.0 (SPSS Inc., Chicago, IL, USA).

Results

Of the 497 patients, there were 636 aneurysms with an average male:female ratio of 1:2 and a mean age of 59.2 years (range, 15–90 years). Most (69%) presented with subarachnoid hemorrhage. Patients’ characteristics are shown in Table 1. Of the 636 IAs, 563 (88.5%) were saccular and 73 (11.5%) were fusiform. The most common location was the posterior communicating artery (19.7%), followed by the anterior communicating artery (15.8%).

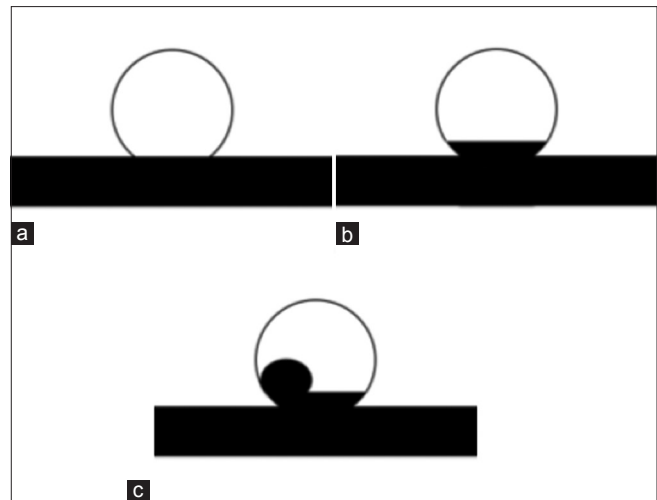


Figure 1: Raymond classification for aneurysmal occlusions. (a) Complete obliteration of the aneurysm. (b) Subtotal obliteration of the aneurysm. (c) Incomplete obliteration of the aneurysm

Table 1: Patient characteristics (n=497)

Parameters	n (%)
Male:female	171 (34.3):326 (65.7)=1:1.9
Age, years (range)	59.18 (15-90)
Clinical presentation	
Ruptured aneurysm	343 (69)
Unruptured aneurysm	154 (31)
Incidental findings	94 (19)
Cranial nerve palsy	43 (8.6)
Pain	7 (1.4)
Thromboembolic event	5 (1)
Other	5 (1)

Most saccular aneurysms (73.5%) were small at <7 mm in diameter and most averaged 3–5 mm in diameter. Relatively wide-necked aneurysms (dome: neck ratio ≥1.5) were found in 47.8% of aneurysms. The angiographic characteristics of the IAs are shown in Table 2.

Of the 636 IAs, 374 (59%) were treated surgically and 122 (19.2%) had endovascular interventions, five (0.8%) had combined surgery and endovascular treatment, and 129 (20.3%) had conservative treatment with observation only. When comparing surgical and endovascular therapy, 16.9% and 83.1% of the aneurysms occurred in the anterior circulation and 57.9% and 42.1% occurred in the posterior circulation, respectively (*P* = 0.000).

Of 127 aneurysms (20%) in 120 patients (24.2%) with endovascular treatment, there were 83 females (69.2%) and 37 males (30.8%), with a mean age of 59.2 years (range, 15–88 years). Ruptured aneurysms were found in 60.6% of all patients. The most commonly treated location was the posterior communicating artery (15.8%), but the proportion of endovascular treatment was higher for carotid cave aneurysms (6/18 or 33.3%) and those in the posterior circulation as follows: 45.5% (15/33) in

the intradural vertebral artery, 48% (12/25) in the basilar trunk, and 39.1% (9/23) in the basilar tip. A comparison of all aneurysmal characteristics between the endovascular therapy group and the entire study population group is shown in Tables 3 and 4.

The endovascular techniques used to treat IAs were simple coiling, device-assisted coiling, and parent

artery sacrifice [Table 5]. Nearly half of the aneurysms were treated with simple coiling using a single microcatheter (49%); intracranial stents were used in most cases of device-assisted coiling (25%). Flow diverter stents were used in seven aneurysms (one fusiform shape in the left cavernous internal carotid artery with the remaining in the basilar tip, basilar trunk, and intradural vertebral artery). Coronary stent graft systems (JOSTENT GRAFTMASTER with Hydrex coating system; Jomed International, Abbott Vascular, Redwood City, CA, USA) were used exclusively in three cases with fusiform aneurysms; one with vertebral artery aneurysm and another two with aneurysms in the cavernous portion of the internal carotid artery. Sacrifice of the parent artery was performed in three cases with fusiform-shaped aneurysms (two in the vertebral artery and one in the cavernous portion of the internal carotid artery). Stent-assisted coiling was the primary technique used for wide-necked aneurysms (44.2%), whereas a simple coiling technique was used in 26.9%. A comparison of the endovascular techniques used in wide-necked and small-necked aneurysms is shown in Table 6.

Four aneurysms received combined treatment and another aneurysm repair started with clipping and was followed by a flow diverter stent. Four aneurysms received combined treatment. Treatment in one patient with a left posterior communicating aneurysm began with balloon-assisted coiling; however, after accidental intra-procedural rupture of the aneurysm occurred, we secured the aneurysm by clipping after partial coiling.

Table 2: Aneurysmal characteristics (n=636)

Aneurysmal characteristics	n (%)
Location (n=636)	
Anterior circulation	488 (72.7)
Posterior circulation	148 (27.3)
Size (saccular aneurysm only; n=563)	
<7 mm	413 (73.4)
≥7 mm	150 (26.6)
Neck size (saccular aneurysm only; n=563)	
<4 mm	373 (66.3)
≥4 mm	190 (33.7)
Dome:neck ratio (saccular aneurysm only; n=563)	
<1.5	269 (47.8)
≥1.5	294 (52.2)
Aneurysmal shape (saccular aneurysm only; n=563)	
Bilobed	25 (4.4)
Lobulated	74 (13.1)
Aneurysmal bleb	22 (3.9)

Table 3: Aneurysm location: Comparison between the endovascular group and the all aneurysms group

Parameter	Endovascular group (n=127)		All aneurysms (n=636)	
	n (%)	Size (mean)	n (%)	Size (mean)
Anterior circulation	72 (56.7)		488 (76.7)	
Posterior communicating artery	20 (15.8)	2.7-9.0 (5.28)	125 (19.7)	1.2-17 (5.96)
Anterior communicating artery	13 (10.3)	2.65-10.06 (5.27)	100 (15.8)	1.1-16.9 (4.83)
Middle cerebral artery	1 (0.8)	3.2-11 (6.03)	81 (12.9)	2.3-110 (8.427)
ICA-supraclinoid portion	6 (4.7)	2.8-28.98 (14.66)	47 (7.4)	1.3-44.3 (11.46)
ICA-cavernous portion	7 (5.5)	2.84-8.3 (4.69)	43 (6.7)	1.2-69.4 (14.02)
Anterior cerebral artery	6 (4.8)	4.47-12.8 (6.52)	27 (4.3)	2.84-11.21 (5.17)
ICA-paraclinoid portion	9 (7.1)	3.50-4.91 (4.17)	26 (4.2)	1.5-14.18 (4.36)
ICA-carotid cave	6 (4.7)	3-24.6 (7.22)	18 (2.8)	1.6-14.55 (4.74)
ICA-ophthalmic segment	4 (3.2)	2.7 (2.7)	11 (1.7)	1.99-24.62 (7.63)
Anterior choroidal artery	0	-	6 (0.9)	2.11-6.5 (4.61)
ICA-bifurcation	0	-	4 (0.7)	2.25-8.39 (3.92)
Posterior circulation	55 (43.3)		148 (42.9)	
V4 segment of vertebral artery	15 (11.8)	2.58-22 (7.43)	33 (5.2)	2.47-45.8 (10.8467)
Basilar trunk	12 (9.4)	2.3-12.98 (6.71)	25 (3.9)	1.2-65 (11.44)
Basilar tip	9 (7.1)	2.19-15.06 (5.97)	23 (3.5)	1.6-22 (7.28)
Posterior cerebral artery	7 (5.5)	5.46-41 (11.93)	18 (2.8)	2.5-12.3 (5.89)
Superior cerebellar artery	7 (5.5)	2.76-17.03 (6.89)	15 (2.4)	2.19-15.06 (6.81)
Posteroinferior cerebellar artery	4 (3.2)	3.18-9.02 (6.45)	15 (2.4)	1.95-8.17 (5.2)
Vertebrobasilar junction	1 (0.8)	3.39 (3.39)	15 (2.4)	2.2-55 (11.77)
Anteroinferior cerebellar artery	0	-	4 (0.7)	2.97-4.4 (3.75)

ICA – Internal carotid artery

Table 4: Aneurysmal characteristics: comparison between the endovascular group and the all aneurysms group

Parameter	Endovascular group, n (%)	All aneurysms, n (%)
Aneurysm size (mm)	n=127	n=636
<7	91 (71.6)	432 (67.9)
<3	12 (9.4)	104 (16.3)
3-4.99	40 (31.5)	197 (31.0)
5-6.99	39 (30.7)	131 (20.6)
≥7	36 (28.4)	149 (32.1)
7-9.99	14 (11.0)	88 (13.8)
10-24.99	20 (15.8)	94 (14.8)
≥25	2 (1.6)	22 (3.5)
Neck size (saccular aneurysms only)	n=120	n=563
<4	73 (60.8)	373 (66.3)
≥4	47 (39.2)	190 (33.7)
Dome:neck ratio (saccular aneurysms only)	n=120	n=563
<1.5	52 (43.3)	269 (47.8)
≥1.5	68 (56.7)	294 (52.2)
Shape	n=127	n=636
Saccular	120 (94.5)	563 (88.5)
Bilobed	8 (6.7)	25 (4.4)
Lobulated	11 (9.2)	74 (13.1)
Aneurysmal bleb	8 (6.7)	22 (3.9)
Fusiform	7 (5.5)	73 (11.5)

Table 5: Endovascular technique in aneurysmal treatment (n=127)

Endovascular technique	n (%)
Simple coiling	61 (48)
Stent-assisted coiling	31 (24.4)
Balloon-assisted coiling	21 (16.5)
Flow diverter and covered stent	10 (7.9)
Sacrifice	3 (2.4)
Catheter-assisted coiling	1 (0.8)

In the 127 endovascular-treated IAs, we had a 99.2% success rate. One technical failure happened in a small aneurysm in the basilar artery, with a dome:neck ratio <1.5, where the tip of the microcatheter could not be positioned in the aneurysmal sac after stent deployment.

Immediate postoperative angiographic results were assessed as follows: complete obliteration in 32 aneurysms (25.2%) [Figure 2]; subtotal obliteration in 75 (59%) [Figure 2]; and incomplete obliteration in 20 aneurysms (15.8%).

Procedural complications occurred in 18.1% of cases (23 patients) and are summarized in Table 7. One of seven patients who had intra-procedural aneurysmal sac rupture required further surgery and none had worse clinical outcomes. One patient who had coil protrusion into

Table 6: Comparison of the endovascular techniques used in wide-necked* and small-necked aneurysms (n=127)

Technique and material	Wide-necked aneurysm (n=54), n (%)	Small-necked aneurysm (n=3), n (%)	Total	P
Simple coiling	14 (25.9)	47 (64.4)	61	<0.05
Stent-assisted coiling	24 (44.4)	7 (9.6)	31	<0.05
Balloon-assisted coiling	10 (18.5)	11 (15.1)	21	Not significant
Flow diverter stent	4 (7.5)	3 (4.1)	5	Not significant
Parent artery sacrifice	1 (1.9)	2 (2.7)	3	Not significant
Covered stent	0	3 (4.1)	3	Not significant
Catheter-assisted coiling	1 (1.9)	0	1	Not significant

*Wide-necked aneurysm defined as aneurysms with a dome: neck ratio <1.5

Table 7: Complications in 23 aneurysms

Complication	n (%)	Clinical outcome on follow-up
Hemorrhagic complication:	7 (30.4)	Stable, 2; improved, 2; good recovery, 2; lost to follow-up, 1
Intra-procedural rupture		Improved clinical outcome, 1; good recovery, 1
Embolic complication	2 (8.7)	
Device-related complication	12 (52.2)	
Coil loosening	2 (8.7)	Death, 1; lost to follow-up, 1
Inflammation from coil mass	1 (4.3)	Death, 1
Stent malposition or migration	4 (17.4)	Stable, 2; improved, 1; increased neurological deficit, 1
Stent cracking	1 (4.3)	Good recovery, 1
Coil protrusion	4 (17.4)	Improved, 3; good recovery, 1
Parent artery occlusion	2 (8.7)	Improved, 1; death, 1

the parent artery required unplanned stent deployment. Four cases with stent malposition during the procedure required additional stent deployment, and 2/4 were flow diverters. Asymptomatic-delayed parent artery occlusion was found on follow-up in two cases and both were treated with covered stents. Our most serious complication occurred in one patient with a large basilar tip aneurysm. After successful embolization with an adjunctive flow diverter stent, the patient had progressive edema surrounding the coil mass with a significant mass effect to the brainstem. This patient eventually died.

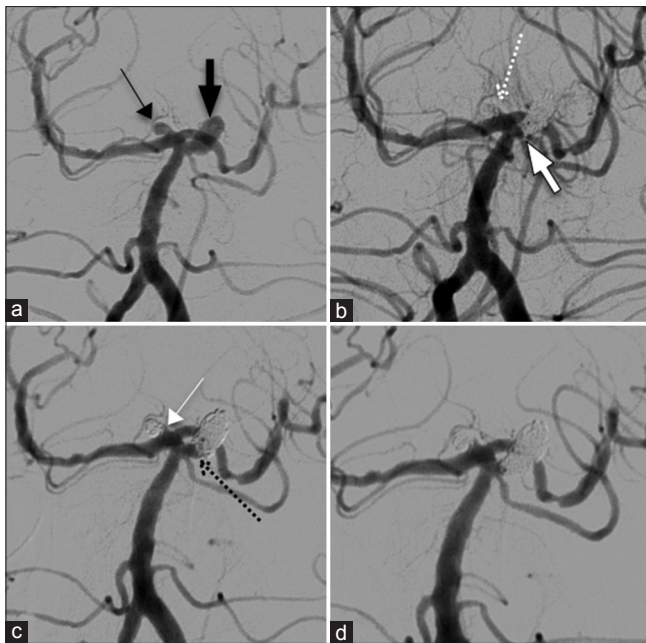


Figure 2: An 82-year-old female presented with rupture aneurysm. (a) Aneurysms of left SCA (thick black arrow) and basilar tip (thin black arrow) with dome: neck ratios of about 3.1 and 1.1, respectively. (b) Following simple coiling, complete obliteration of the left SCA aneurysm (thick white arrow) and subtotal obliteration of the basilar tip (white dot arrow). (c) Six months later, regrowth of the left SCA (black dot arrow) with stable of the basilar tip (thin white arrow). (d) Retreatment by simple coiling of the left SCA aneurysm with complete obliteration. SCA – Superior cerebellar artery

Aneurysmal regrowth from endovascular therapy occurred in 21 aneurysms (16.5%), during a mean follow-up duration of 9.9 months. However, excluding the longest period of regrowth of 8 years, the mean duration of regrowth was 5.6 months. The predictor variables for aneurysmal regrowth are shown in Table 8. No factors had a significant correlation with regrowth, including the initial angiographic results. However, aneurysms with a posterior circulation location, small neck (dome:neck ratio ≥ 1.5), small size (< 7 mm), and those treated with a simple coiling technique had a greater tendency for regrowth.

After excluding 22/120 patients who were lost to follow-up, patient outcomes were evaluated in 98 patients with a mean follow-up of 7.3 months [Table 9]. A good outcome was found in 67.3%, stable in 28.7%, worse in 1%, and mortality in 3%.

Regarding clinical outcomes in nine patients who presented with cranial nerve palsies, two patients had good recovery of ptosis and ophthalmoplegia at 6 and 12 months, respectively, four patients had clinical improvement within 3–6 months, two patients had no clinical change, and one patient who received adjunctive flow diverter treatment had worse diplopia.

Three deaths occurred in our series; one resulted from preexisting severe mRS because of subarachnoid hemorrhage, one was secondary to progressive edema of

Table 8: Predictors of aneurysmal re-growth

Aneurysmal characteristic	Number of aneurysms, n (%)	Regrowth rate in 21 aneurysms, n (%)	P
Clinical presentation	n=124*		
Rupture	76 (61.3)	11 (14.5)	0.358 (not significant)
Unruptured	48 (38.7)	10 (20.8)	
Location	n=124*		
Anterior	49 (39.5)	6 (12.2)	0.260 (not significant)
Posterior	75 (60.5)	15 (20)	
Size	n=124*		
≥ 7 mm	36 (29)	5 (13.9)	0.563 (not significant)
< 7 mm	88 (71)	16 (18.2)	
Neck size	n=124*		
≥ 4 mm	48 (38.7)	8 (16.7)	0.949 (not significant)
< 4 mm	76 (61.3)	13 (17.1)	
Dome:neck ratio	n=124*		
≥ 1.5	73 (58.9)	15 (20.5)	0.199 (not significant)
< 1.5	51 (41.1)	6 (11.8)	
Treatment technique	n=113**	n=20***	
Simple coiling	61 (54)	13 (21.3)	0.276 (not significant)
Device-assisted coiling	52 (46)	7 (13.5)	
Immediate angiographic results	n=124*	21 (16.9)	
Complete obliteration	31 (25)	4 (12.9)	0.524 (not significant)
Subtotal obliteration	75 (60.5)	15 (20)	
Incomplete obliteration	18 (14.5)	2 (11.1)	

*Three patients with combined surgical and endovascular therapy were excluded, **11 patients with flow diverter stents, covered stents, and parent artery sacrifice were excluded

Table 9: Clinical outcomes (n=98 patients)

Clinical outcome	Rupture, n (%)	Unruptured, n (%)	Total, n (%)
Good recovery	30 (49.2)	4 (10.8)	34 (34.7)
Improved status	25 (41)	7 (18.9)	32 (32.6)
Stable	4 (6.5)	24 (64.9)	28 (28.7)
Increased neurological deficit	0	1 (2.7)	1 (1)
Death	2 (3.3)	1 (2.7)	3 (3)
Total patients	61 (100)	37 (100)	98 (100)

*We excluded 22 patients who were lost to follow-up

an embolized basilar tip aneurysm, and the other death was from unrelated causes.

Discussion

IA is a major cause of acute subarachnoid hemorrhage, resulting in catastrophic events with high morbidity and mortality of 25%–50% cases. Unruptured IA may present with headache, cranial nerve palsy, or ischemic stroke from a thromboembolic event or may be an incidental finding

during brain imaging.^[5] The disease is relatively common in the United States and Canada, with a prevalence of approximately 5%.^[6] Several studies support endovascular therapy as a suitable technique for IA, particularly with aneurysmal hemorrhage.

In our series, IA commonly presented with subarachnoid hemorrhage (69.1%). The disease was more common in females (female:male ratio, 2:1), with a mean age of 38 years. Our patient characteristics were similar to other studies.^[7-11] Common locations were the posterior communicating artery, anterior communicating artery, and middle cerebral artery. Our incidence differed from the previous reports in which the anterior communicating artery was the most common location. Screening brain imaging has not been a standard protocol in our clinical practice.

Although several reports suggest that larger aneurysms have a higher risk of rupture,^[12-14] in our series, the primary presentation was rupture with a majority of small aneurysms <7 mm in diameter (73.5%).

In our institute, the decision for endovascular therapy involves consensus between a neurosurgeon and an interventional neuroradiologist based on cost-effectiveness; therefore, embolization was frequently indicated in locations of increased surgical difficulty, resulting in a greater proportion of coiling and in the posterior circulation and carotid cave. This finding is similar to the previous studies showing that endovascular treatment has a lower morbidity and mortality than surgical treatment in these locations.^[12,15,16] As our standard procedure, we prefer a simple coiling technique using a single microcatheter with the goal of minimizing the intra-procedural risk while addressing cost-benefit concerns. In general, wide-necked aneurysms have limitations with this simple technique because the coils are difficult to maintain within the sac, and there is also a risk of the coil protruding into the parent artery, even after appropriate detachment. Adjunctive techniques (including balloon-assisted, stent-assisted, or double-catheter) are planned in aneurysms with unfavorable angioarchitecture for simple coiling or wide-necked aneurysms if the dome-to-neck ratio is >1.5. Brinjikji *et al.* suggested that if the dome-to-neck ratio was >1.6, device-assisted techniques were not required but were recommended with ratios <1.2.^[15,17] In their studies, the mean dome:neck ratio was 1.97 ± 0.59 in simple coiling aneurysm repair and 1.59 ± 0.42 in adjunctive treatment. Most often, our assisting device was an intracranial stent. Occasionally, stent deployment was unplanned but performed if coil protrusion occurred during the procedure, and we successfully used a simple coiling technique in wide-necked aneurysms (26.9%). Our mean dome:neck ratio was 1.98 ± 0.81 for the simple coiling technique (lowest ratio, 0.88) and 1.57 ± 1.21 in device-assisted procedures.

Our immediate angiographic results were 25.2% complete occlusion, 59% subtotal obliteration, and 15.7% incomplete

obliteration. Our data showed no significant difference between simple coiling and device-assisted techniques. In general, larger aneurysms with wider necks typically have lower reported rates of successful occlusion^[12] and reported rates of complete aneurysmal occlusion vary from 26% to 81%.^[4,8,9,12] The Endovascular Approach of Nonruptured Aneurysms study demonstrated complete occlusion in 43.4%–63.7% of aneurysms, neck remnant in 20.8%–23.3%, and residual aneurysmal sac in 10.9%–35.8%.^[16] Wieber *et al.* showed that using stent-assisted coiling could totally obliterate aneurysms in 50% of cases.^[17]

Complications from our embolization procedure occurred in 18.1% (23) of patients. Hemorrhagic complications (5.5%) were related to intra-procedural rupture of the aneurysmal sac, and in almost all patients (6/7); management consisted of reversal of systemic heparinization and continuation of coil insertion to occlude the aneurysm as completely as possible. One patient underwent urgent aneurysm surgery for clipping. None of our hemorrhagic complications had associated mortality or worse outcome. Meta-analyses of this complication in a larger series reported an incidence of 1.4%–4.7%, with an associated mortality rate of 30%–40%.^[11]

Thromboembolic complications (1.2%) of the distal artery were procedure-related events and were found incidentally during controlled angiography following treatment.

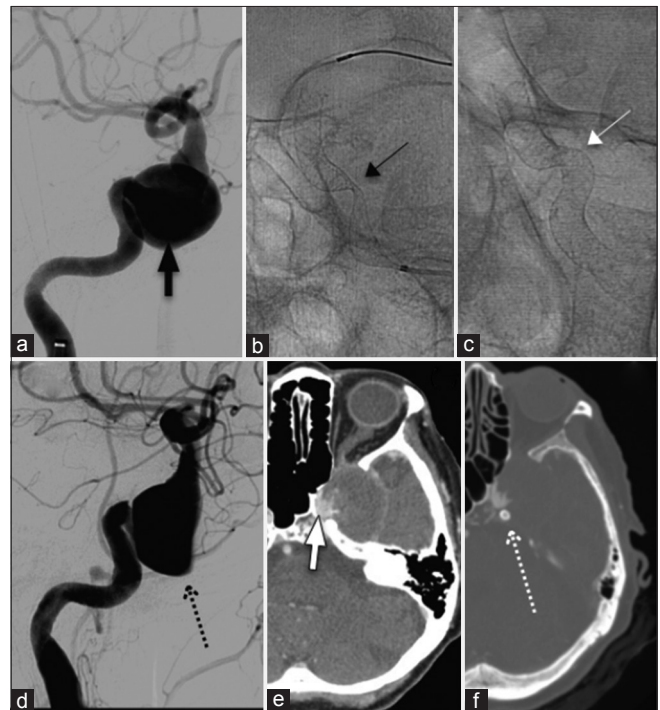


Figure 3: A 78-year-old female with diplopia. (a) Angiogram showing a large aneurysm in the left cavernous region (thick black arrow). (b) We decided to use a FD; however, there the FD kinked after deployment (thin black arrow). (c) Better opening of the FD was seen after angioplasty (white thin arrow). (d) Controlled angiogram after treatment showing contrast stagnation in the aneurysmal sac (black dot arrow). (e and f) CT angiogram 6 months postoperatively showing a residual sac (thick white arrow) and good patency of the FD (white dotted arrow). FD – Flow diverter; CT – Computed tomography

Previous studies report a wide incidence range for this complication of 2.4%–16.7%.^[7,8]

Intra-procedural device-related complications (9.4%) in our study included coil migration, coil straightening, coil protrusion, and stent malposition [Figure 3], resulting in unfavorable coil packing and incomplete aneurysmal occlusion. However, no hemorrhagic or embolic events were observed.

Regarding the use of flow diverter stents, a meta-analysis by Brinjikji *et al.* reported 4% morbidity and 5% mortality.^[18] Postoperative subarachnoid hemorrhage, intraparenchymal hemorrhage, and perforator infarction were each found in 3% of patients and ischemic stroke in 6%. The authors also showed that posterior circulation aneurysms repaired with a flow diverter stent had a greater tendency to have ischemic complications than those in the anterior circulation. We experienced only six cases with complications using this adjunctive device and almost no hemorrhagic or embolic complications. Of the three deaths in our series, one was a treatment-related death of a patient with a large nonruptured basilar tip aneurysm. He had postprocedural progressive brain edema surrounding the coil mass, with inevitable mass effect to the brainstem. This was likely result from inflammation using bioactive coil (Matrix coil; Boston Scientific Neurovascular) [Figure 4]. Stent malposition occurred in two patients during the procedures, which required additional stent deployment.

Coronary stent graft for intracranial neurovascular disease was first described in 1997.^[19] Chiaradio *et al.* reported a

case where a covered stent was used in a fusiform aneurysm in the intracranial segment of the vertebral artery.^[20] Saatci *et al.* reported a case series treating internal carotid artery aneurysms in 24 patients with a 95.8% success rate.^[21] Other authors also report good results in giant aneurysms and dissecting vertebral artery aneurysms.^[22,23] In our series, we used a coronary stent graft in three cases with immediate-good angiographic results, but 2/3 had delayed asymptomatic parent artery occlusion, even with continuation of antiplatelet therapy.

The regrowth rate in our series was 16.5% and no rebleeding was found during the mean follow-up of 9.9 months. No significant predictors for aneurysmal regrowth were identified. We also found no correlation between angiographic results (complete, subtotal, and incomplete occlusion) and the rate of regrowth in our series. Reported regrowth rates vary from 0% to 42%.^[1,8,9,11] Raymond *et al.* demonstrated recanalization rates of 20% in completely occluded aneurysms versus 40.1% in those with neck remnants and 51.1% in those with aneurysmal sac remnants.^[24] Li *et al.* reported a reopening rate of 3.5% for total occlusion, 43.5% for subtotal occlusion, and 50% for incomplete occlusion.^[25] Large aneurysm size was documented to be a risk factor for reopening and retreatment, explained in part by lesser packing density and a higher proportion of aneurysms with intraluminal thrombus [Figure 5].^[26] We obtained different results that may be explained by the small number of patients in our study and insufficient follow-up duration. However, because we weighed the cost–benefit ratio, we considered that it might not always be necessary to attempt complete

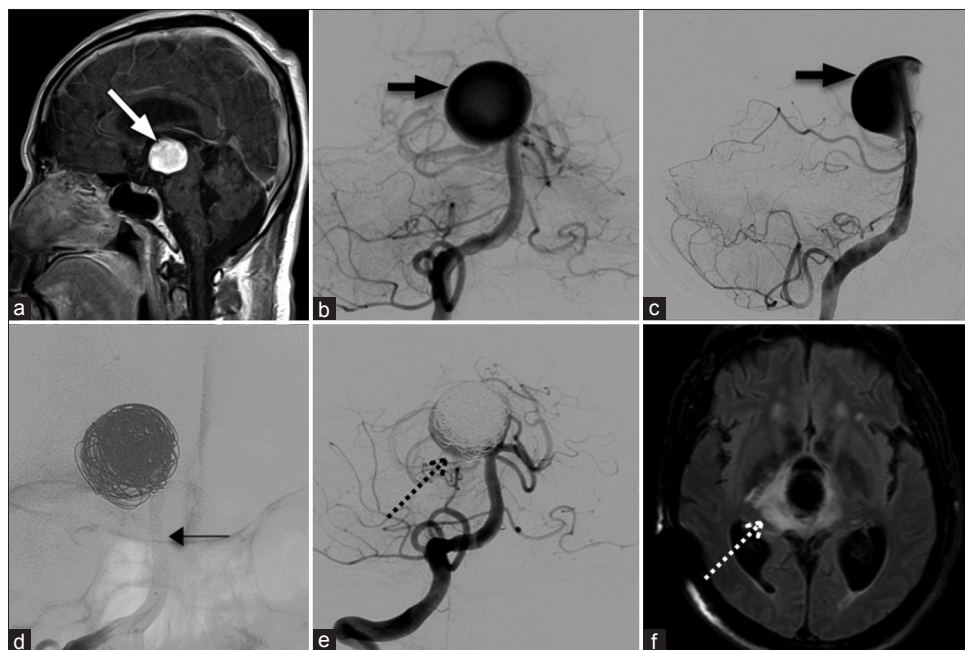


Figure 4: A 65-year-old male with headache. (a) MRI showing an aneurysm (thick white arrow). (b and c) Right VA angiogram showing a large basilar tip aneurysm (thick black arrow). (d) Flow diverter stenting with coil (thin black arrow). (e) Angiogram showing incomplete obliteration (black dot arrow). The patient developed drowsiness 1 week after. (f) MRI showing abnormal high signal intensity in the brainstem around the coil mass (white dotted arrow), likely resulting from inflammation by using bioactive coils. MRI – Magnetic resonance imaging; VA – Vertebral artery

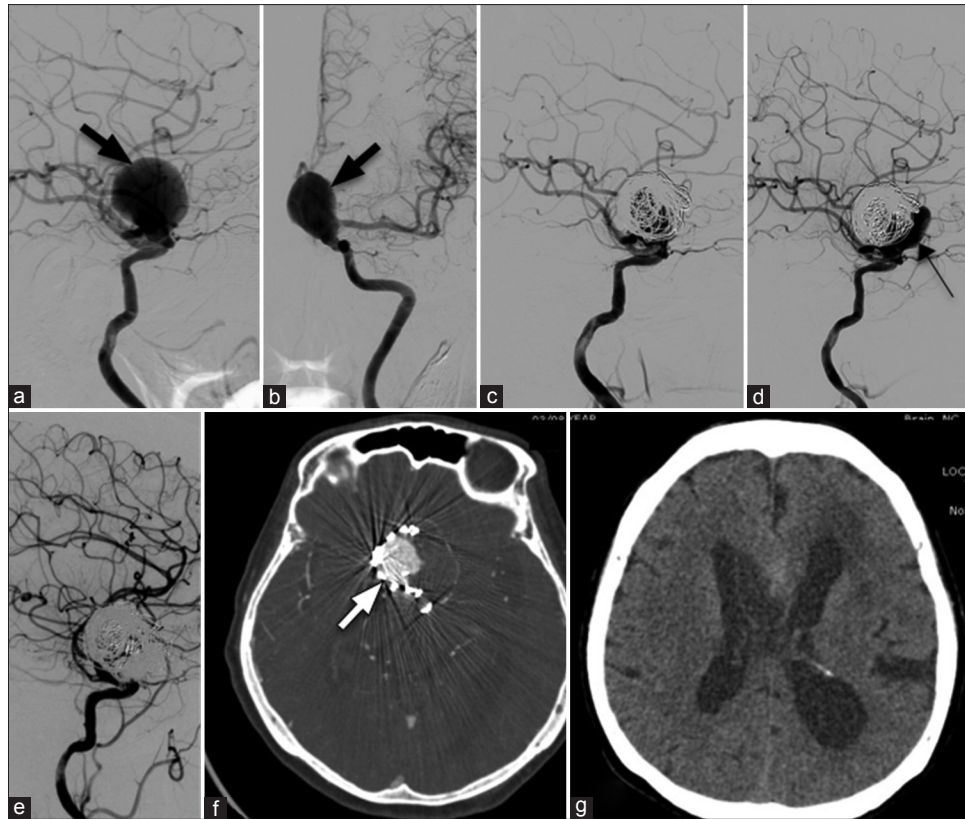


Figure 5: A patient with transient ischemic attack. (a and b) Angiogram showing a giant aneurysm from the ophthalmic segment of the left ICA (thick black arrow). (c) Stent-assisted coil embolization with incomplete obliteration. (d) Six months later, there is regrowth with recoiling performed in the same setting (thin black arrow). (e) Angiogram showing incomplete obliteration. (f and g) 5 years later, the patient developed obstructive hydrocephalus with regrowth (thick white arrow) then surgical ligation of the left ICA. The patient had right hemiparesis after surgery. ICA – Internal carotid artery

occlusion, particularly in the ruptured group, using multiple devices, if a simple technique effectively secured the aneurysm and our results confirmed this consideration.

Our results from endovascular treatment of IA were comparable to the previous publications, with a high success rate and favorable outcome of 96%.^[8] In our patients presenting with subarachnoid hemorrhage, 90.1% had good outcome; 49.2% with good recovery and 30.8% with improved clinical status, and 60% of patients with an initial mRS = 4 showed improved outcome. In our series, procedure-related mortality and morbidity were each found in one patient (0.8%), compared with reported overall morbidity and mortality rates for endovascular treatment of aneurysms of 3.7%–5.3% and 1.1%–1.5%, respectively.^[4,11] Although since 1997, endovascular technique in treatment of IA advanced overtime, according to our center's policy, we tend to treat aneurysm by simple technique. This is limitation that we did not separate result between era of stent or no stent.

Conclusions

Endovascular therapy for IA in our institute is feasible with low morbidity and mortality rates. Even a simple coiling technique was successfully used for some wide-necked aneurysms. No significant difference in aneurysmal

regrowth rate was demonstrated for complete, subtotal, and incomplete occlusion. Although adjunctive techniques for wide-necked aneurysms were helpful, we consider that it is not always necessary to attempt complete aneurysmal occlusion using several devices, particularly in the rupture group when considering the cost–benefits. However, long-term angioarchitecture and clinical follow-up are required to determine the long-term safety and efficacy of endovascular treatment.

Ethical standards

This study meets the guidelines of the Declaration of Helsinki and all patients gave informed consent for the use of their data in the study. The study was approved by the Siriraj Institutional Review Board (COA No. Si151/2013).

Declaration of patient consent

The authors certify that they have obtained all appropriate patient consent forms. In the form the patient(s) has/have given his/her/their consent for his/her/their images and other clinical information to be reported in the journal. The patients understand that their names and initials will not be published and due efforts will be made to conceal their identity, but anonymity cannot be guaranteed.

Financial support and sponsorship

Nil.

Conflicts of interest

There are no conflicts of interest.

References

- Seibert B, Tummala RP, Chow R, Faridar A, Mousavi SA, Divani AA, *et al.* Intracranial aneurysms: Review of current treatment options and outcomes. *Front Neurol* 2011;2:45.
- Guglielmi G, Viñuela F, Briganti F, Duckwiler G. Carotid-cavernous fistula caused by a ruptured intracavernous aneurysm: Endovascular treatment by electrothrombosis with detachable coils. *Neurosurgery* 1992;31:591-6.
- Guglielmi G, Viñuela F, Dion J, Duckwiler G. Electrothrombosis of saccular aneurysms via endovascular approach. Part 2: Preliminary clinical experience. *J Neurosurg* 1991;75:8-14.
- Molyneux AJ, Kerr RS, Yu LM, Clarke M, Sneade M, Yarnold JA, *et al.* International subarachnoid aneurysm trial (ISAT) of neurosurgical clipping versus endovascular coiling in 2143 patients with ruptured intracranial aneurysms: A randomised comparison of effects on survival, dependency, seizures, rebleeding, subgroups, and aneurysm occlusion. *Lancet* 2005;366:809-17.
- Heros RC. Intracranial aneurysms. A review. *Minn Med* 1990;73:27-32.
- Keedy A. An overview of intracranial aneurysms. *Mcgill J Med* 2006;9:141-6.
- Brilstra EH, Rinkel GJ, van der Graaf Y, van Rooij WJ, Algra A. Treatment of intracranial aneurysms by embolization with coils: A systematic review. *Stroke* 1999;30:470-6.
- Ferns SP, Sprengers ME, van Rooij WJ, Rinkel GJ, van Rijn JC, Bipat S, *et al.* Coiling of intracranial aneurysms: A systematic review on initial occlusion and reopening and retreatment rates. *Stroke* 2009;40:e523-9.
- Ishibashi T, Murayama Y, Urashima M, Saguchi T, Ebara M, Arakawa H, *et al.* Unruptured intracranial aneurysms: Incidence of rupture and risk factors. *Stroke* 2009;40:313-6.
- Xavier AR, Abdelbaky A, Rayes M, Tiwari A, Narayanan S. Clinical and angiographic outcome in patients with completely occluded intracranial aneurysms by endovascular coiling: Our experience. *J Neurointerv Surg* 2011;3:335-9.
- Brisman JL, Song JK, Newell DW. Cerebral aneurysms. *N Engl J Med* 2006;355:928-39.
- Morita A, Fujiwara S, Hashi K, Ohtsu H, Kirino T. Risk of rupture associated with intact cerebral aneurysms in the Japanese population: A systematic review of the literature from Japan. *J Neurosurg* 2005;102:601-6.
- Park HK, Horowitz M, Jungreis C, Kassam A, Koebbe C, Genevro J, *et al.* Endovascular treatment of paraclinoid aneurysms: Experience with 73 patients. *Neurosurgery* 2003;53:14-23.
- Sun Y, Li Y, Li AM. Endovascular treatment of paraclinoid aneurysms. *Interv Neuroradiol* 2011;17:425-30.
- Brinjikji W, Cloft HJ, Kallmes DF. Difficult aneurysms for endovascular treatment: Overwide or undertall? *AJNR Am J Neuroradiol* 2009;30:1513-7.
- Pierot L, Spelle L, Vitry F; ATENA Investigators. Immediate anatomic results after the endovascular treatment of unruptured intracranial aneurysms: Analysis of the ATENA series. *AJNR Am J Neuroradiol* 2010;31:140-4.
- Wiebers DO, Whisnant JP, Huston J 3rd, Meissner I, Brown RD Jr., Piepgras DG, *et al.* Unruptured intracranial aneurysms: Natural history, clinical outcome, and risks of surgical and endovascular treatment. *Lancet* 2003;362:103-10.
- Brinjikji W, Murad MH, Lanzino G, Cloft HJ, Kallmes DF. Endovascular treatment of intracranial aneurysms with flow diverters: A meta-analysis. *Stroke* 2013;44:442-7.
- Singer RJ, Dake MD, Norbash A, Abe T, Marcellus ML, Marks MP, *et al.* Covered stent placement for neurovascular disease. *AJNR Am J Neuroradiol* 1997;18:507-9.
- Chiaradio JC, Guzman L, Padilla L, Chiaradio MP. Intravascular graft stent treatment of a ruptured fusiform dissecting aneurysm of the intracranial vertebral artery: Technical case report. *Neurosurgery* 2002;50:213-6.
- Saatci I, Cekirge HS, Ozturk MH, Arat A, Ergungor F, Sekerci Z, *et al.* Treatment of internal carotid artery aneurysms with a covered stent: Experience in 24 patients with mid-term follow-up results. *AJNR Am J Neuroradiol* 2004;25:1742-9.
- Blasco J, Macho JM, Burrel M, Real MI, Romero M, Montaña X, *et al.* Endovascular treatment of a giant intracranial aneurysm with a stent-graft. *J Vasc Interv Radiol* 2004;15:1145-9.
- He M, Zhang H, Lei D, Mao BY, You C, Xie XD, *et al.* Application of covered stent grafts for intracranial vertebral artery dissecting aneurysms. *J Neurosurg* 2009;110:418-26.
- Raymond J, Guilbert F, Weill A, Georganos SA, Juravsky L, Lambert A, *et al.* Long-term angiographic recurrences after selective endovascular treatment of aneurysms with detachable coils. *Stroke* 2003;34:1398-403.
- Li MH, Gao BL, Fang C, Gu BX, Cheng YS, Wang W, *et al.* Angiographic follow-up of cerebral aneurysms treated with Guglielmi detachable coils: An analysis of 162 cases with 173 aneurysms. *AJNR Am J Neuroradiol* 2006;27:1107-12.
- van Rooij WJ, Sluzewski M. Unruptured large and giant carotid artery aneurysms presenting with cranial nerve palsy: Comparison of clinical recovery after selective aneurysm coiling and therapeutic carotid artery occlusion. *AJNR Am J Neuroradiol* 2008;29:997-1002.