Article published online: 2022-08-16

Case Report

Temporalis Muscle cysticercosis: Common Parasite at Uncommon Location

Abstract

Isolated involvement of the temporalis muscle by cysticercosis is uncommon. The clinical features may mimic other inflammatory conditions of maxilofacial region or that of temporal headache. We describe here a case of right temporalis muscle cysticercosis that was initially misdiagnosed as dental caries. She clinically improved with albendazole and steroid. The radiology done after 6 months of therapy showed a complete resolution of the intramuscular lesion. Although rare, cysticercosis should be kept as one differential in patients present with unilateral temporal headache in endemic areas. Intramuscular cysticercosis can be diagnosed on the basis of radiological findings and respond well to pharmacological therapy.

Keywords: *Albendazole, cysticercosis, Taenia solium, temporal pain*

Lomesh Wankhede[1], Sushanta Kumar Sahoo[1], Bharat Hosur

Departments of Radiology and [1]Neurosurgery, PGIMER, Chandigarh, India

Introduction

Cysticercosis involving the central nervous system is well known and most of them present with seizures. The involvement of skeletal muscles in the region of head and neck is less commonly reported in the literature.[1] These cases are difficult to diagnose because of their rarity and the clinical features may mimic other maxilofacial pathologies. We here describe a case of isolated temporalis muscle cysticercosis in a young female, whose symptomatology mimics dental caries. Good clinical and radiological outcomes are noted after medical management. The differential diagnosis as well as the importance of radiological investigations in these rare entities further emphasized.

Case Report

A 28-year-old female presented to the outpatient neurosurgery department for evaluation of right temporal headache and difficulty in chewing for 3 months. She was diagnosed to have dental caries of the right second molar tooth at a local hospital and was initially considered the cause of her symptomatology. She was referred to us as she did not improve after 2 months of anti-inflammatory and analgesics. On evaluation, there was mild tenderness in the right temporal region without any identifiable swelling. However, on palpation, there was induration over the right temporal area. There was no focal neurological deficit. Magnetic resonance imaging (MRI) was advised with a differential diagnosis of temporal arteritis. Radiology revealed a bulky right temporal muscle. There was an elliptical intramuscular enhancing lesion appeared hypointense on T1, hyperintense on T2 with eccentric hypointense dot and perilesional edema [Figure 1a and b]. A radiological diagnosis of temporalis muscle cysticercosis was made. Screening radiology of the brain was normal. She was advised albendazole 15 mg/kg body weight with a tapering dose of steroids (dexamethasone). She improved gradually and at 6-month follow-up, she was symptom free. MRI at the last follow-up showed complete resolution of the lesion [Figure 1c and d].

Discussion

Cysticercosis is endemic in Asian countries. Man acts as a definite host for the causative parasite *Taenia solium*.[2] They spread to distant sites in the body through the bloodstream. Probably because of the high vascularity, these parasites have a strong predilection for the central nervous system. Most of the patients present with clinical

Address for correspondence:
Dr. Sushanta Kumar Sahoo, Department of Neurosurgery, PGIMER, Sector 12, Chandigarh - 160 012, India. E-mail: drsushantsahoo@gmail.com

Access this article online

Website: www.asianjns.org

DOI: 10.4103/ajns.AJNS_55_19

Quick Response Code:

This is an open access journal, and articles are distributed under the terms of the Creative Commons Attribution-NonCommercial-ShareAlike 4.0 License, which allows others to remix, tweak, and build upon the work non-commercially, as long as appropriate credit is given and the new creations are licensed under the identical terms.

For reprints contact: WKHLRPMedknow_reprints@wolterskluwer.com

How to cite this article: Wankhede L, Sahoo SK, Hosur B. Temporalis muscle cysticercosis: Common parasite at uncommon location. Asian J Neurosurg 2021;16:431-2.

Submitted: 04-Mar-2019 **Revised:** 19-Mar-2019
Accepted: 31-Oct-2020 **Published:** 28-May-2021

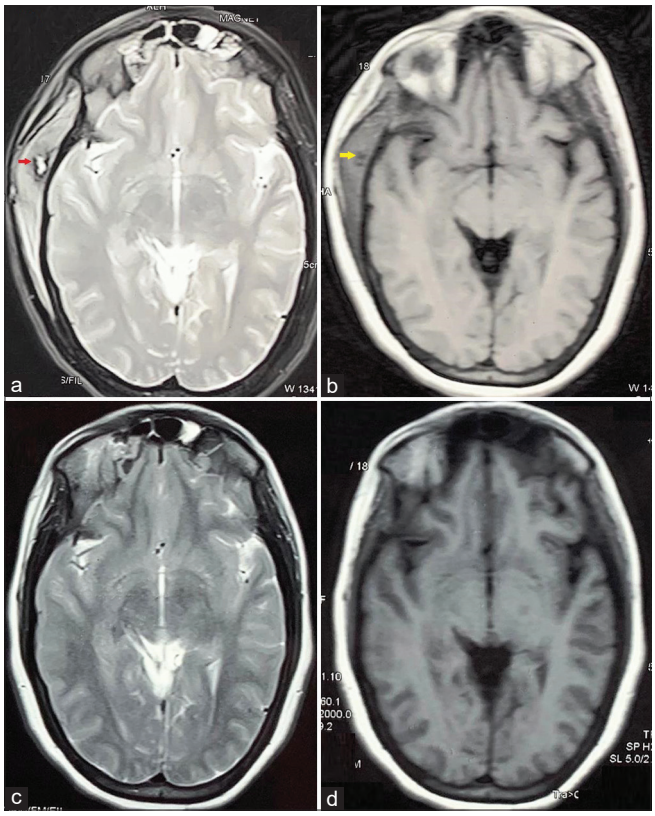

Figure 1: (a) T2-weighted magnetic resonance imaging showing bulky right temporalis muscle with hyperintense lesion and hypointense ring surround it (red arrow). (b) T1-weighted magnetic resonance imaging showing hypointense right intra temporalis muscle lesion (yellow arrow). (c and d) Follow-up magnetic resonance imaging at 6 months showing complete resolution of the lesion

symptoms of seizure and headache. In the active phase, they respond well to antihelminthic drugs. At times when the parasite disseminates, it may affect the heart, lungs, eyes, and skeletal muscles.[3] Very few cases of isolated temporalis muscle cysticercosis have been reported in the literature. Most often, such patients present with temporal headache with a palpable swelling, difficulty in chewing, and in acute inflammatory stage, they may also present with trismus.[1] The accurate pathophysiology of isolated temporalis muscle cysticercosis is not known. Dissemination of the parasite through the bloodstream usually results in distant site cysticercosis. Theoretically, high flow through the internal carotid artery is responsible for high incidences of intracranial involvement. Accidental migration through the external carotid artery (ECA) may result in the deposition of the parasite at sites supplied by its terminal branches. Temporalis muscle receives extensive blood supply from the internal maxillary artery which is one of the terminal and large branches of ECA. This is probably the reason for temporalis muscle cysticercosis, an unusual extracranial site.

Due to their rarity, isolated skeletal muscle involvements are difficult to diagnose. Clinically, they mimic any inflammatory pathology involving the maxilofacial region, as in our case. Cysticercosis may appear as a cystic lesion in the intramuscular plane with an echogenic nidus on ultrasound.[3] On MR imaging, the T2 hyperintense lesion with hypointense focus (scolex) can be identified. Cysticercosis serology like enzyme-linked imunosorbent assay and enzyme-linked immunoelectrotransfer blot tests may further establish the diagnosis.[4]

These cases usually manage with antihelminthic drugs. Albendazole 15 mg/kg body weight and praziquantel 50 mg/kg body weight per day in divided doses for 30 days is the standard treatment.[3,4] Before starting drug therapy, screening of the brain should be done to look for associated neurocysticercosis and ocular cysticercosis where the latter considered as a contraindication for albendazole. Intramuscular cysticercosis usually responds well to medical management and may not require surgical interventions.

Conclusion

Isolated cysticercosis of the temporalis muscle, though rare, should be kept as a differential in patients from endemic areas presenting with unilateral pain and swelling of the temporal region. Careful evaluation of radiology is essential to establish the diagnosis. Good clinical and radiological improvement usually seen with drug therapy.

Declaration of patient consent

The authors certify that they have obtained all appropriate patient consent forms. In the form the patient(s) has/have given his/her/their consent for his/her/their images and other clinical information to be reported in the journal. The patients understand that their names and initials will not be published and due efforts will be made to conceal their identity, but anonymity cannot be guaranteed.

Financial support and sponsorship

Nil.

Conflicts of interest

There are no conflicts of interest.

References

1. Singh S, Sreenivasan V, Garg K, Wazir ND, Rajput JS, Sandhu Virk P. Cysticercosis involving muscle of mastication: A review and report of two cases. Case Rep Dent 2013;2013:814126.
2. Meena D, Gupta M, Jain VK, Arya RK. Isolated intramuscular cysticercosis: Clinicopathological features, diagnosis and management – A review. J Clin Orthop Trauma 2016;7:243-9.
3. Giri KY, Alam S, Dandriyal R, Natu SS. Solitary cysticercosis of the temporalis muscle: Report of a rare case. J Maxillofac Oral Surg 2016;15:240-4.
4. Sethi PK, Sethi NK, Torgovnick J, Arsura E. Cysticercosis of temporalis muscle: An unusual cause of temporal headaches. A case report. J Headache Pain 2007;8:315-6.