

Cortical Blindness after Cervical Spine Surgery in Supine Position – A Rare Case Report and Review of the Literature

Abstract

We report the first case of perioperative visual loss due to cortical blindness after supine cervical spine surgery. A 46-year-old female presented with severe right-sided brachialgia of 1½ years' duration. Her magnetic resonance imaging (MRI) (cervical spine) showed severe right foraminal stenosis at C5–6. She underwent C5–6 anterior cervical discectomy and fusion. Nine hours after surgery, during a routine postoperative round, the patient complained of complete bilateral visual loss. The fundus examination and pupillary light reflex were normal. MRI of the brain showed the posterior cerebral artery infarct with hypoplasia of the left vertebral artery. She was transferred to the neurointensive care unit where antiplatelet treatment was started along with heparin. Her vision slowly began to improve, and at the end of 1 year, she had a reasonable visual acuity in both eyes. It is now standard practice in our institution to check patients' vision immediately after surgery.

Keywords: Cervical, cortical blindness, infarct, perioperative visual loss, spine surgery, supine

Introduction

Perioperative visual loss (POVL) after the spine surgery is a nightmare for any spine surgeon. Its incidence after spine surgery usually varies from 0.028% to 0.2%.^[1] The reported causes of POVL after spine surgery include external ocular injury, ischemic optic neuropathy (anterior or posterior), central or branch retinal artery occlusion, central retinal vein occlusion, cortical blindness, angle-closure glaucoma, and pituitary apoplexy.^[2,3] However, when it occurs, it usually happens after spine surgery done in the prone position. We report the case of a 46-year-old female with cortical blindness after undergoing anterior cervical discectomy and fusion in the supine position, which was never reported earlier in literature.

Case Report

A 46-year-old, *de novo* diagnosed mild hypertensive, nondiabetic female presented with complaints of neck pain, right-sided headache, and right upper limb radiculopathy of 1½ year's duration. She had paresthesias in the right C6 dermatome with normal hand dexterity and bowel–bladder functions. Her higher mental functions and cranial nerve examination

findings were normal. She also had a normal motor and sensory examination except for mild sensory blunting in the right C6 dermatome. Plain radiographs of the cervical spine showed reduced lordosis with spondylotic changes at the C5–6 segment [Figure 1]. Computed tomography of the cervical spine showed a posterior osteophyte at the C5–6 level [Figure 2]. Magnetic resonance imaging (MRI) of the cervical spine showed disc osteophyte complex at the right C5–6 foramen impinging on the right C6 nerve root with no spinal cord changes [Figure 3]. As a trial of prolonged conservative management failed, she underwent anterior cervical discectomy and fusion at C5–6 via Smith–Robinson approach from the left side.

The surgical duration was 3 h, and the approximate blood loss was <20 ml. The blood pressures were maintained uniformly throughout the procedure with a mean arterial blood pressure (MAP) of 85–90 mmHg except for a transient decrease in the MAP to 65 mmHg for 1–2 min. The surgical procedure and recovery from anesthesia went uneventful. However, 9 h after the surgery, during a routine post-operative check, the patient complained

**Raghav Dutt
Mulukutla,
Phani Krishna
Karthik Yelamarthy¹,
RamMohan
Vadapalli²**

*Departments of Spine Services
and ¹Consultant Spine
Surgeon, Department of Spine
Surgery, Udai Omni Hospital,
Hyderabad, Telangana, India,*

*²Consultant Radiologist, Vijaya
Diagnostics, Hyderabad, India*

Address for correspondence:

*Dr. Phani Krishna Karthik
Yelamarthy,
Department of Spine Services,
Udai Omni Hospital,
Hyderabad, Telangana, India.
E-mail: dryelamarthykarthik@
gmail.com*

Access this article online

Website: www.asianjns.org

DOI: 10.4103/ajns.AJNS_473_20

Quick Response Code:



This is an open access journal, and articles are distributed under the terms of the Creative Commons Attribution-NonCommercial-ShareAlike 4.0 License, which allows others to remix, tweak, and build upon the work non-commercially, as long as appropriate credit is given and the new creations are licensed under the identical terms.

For reprints contact: WKHLRPMedknow_reprints@wolterskluwer.com

How to cite this article: Mulukutla RD, Yelamarthy PK, Vadapalli R. Cortical blindness after cervical spine surgery in supine position – A rare case report and review of the literature. *Asian J Neurosurg* 2021;16:406-11.

Submitted: 17-Oct-2020

Revised: 11-Jan-2021

Accepted: 13-Mar-2021

Published: 28-May-2021

of loss of vision bilaterally and with no other complaints. She was conscious, coherent, and oriented with an arterial blood pressure of 160/90 mmHg, pulse rate of 84/min, respiratory rate of 18/min, temperature of 37°C, and oxygen saturation of 99% on room air. On neurological examination, there was a complete loss of vision in both the eyes with normal cranial nerve function and motor function of all four limbs with sensory blunting in the right C6 dermatome. The fundus examination and pupillary light reflex were normal. The cerebellar function was not assessed due to complete visual loss. The patient's laboratory parameters such as total blood count, renal and liver function tests, serum electrolytes, and cardiac enzymes were normal. Her electrocardiogram and echocardiography including transesophageal echocardiography were normal. The patient underwent MRI of the brain, which showed a posterior cerebral artery (PCA) infarct [Figure 4]. The carotid neck vessel Doppler was normal. Magnetic resonance (MR) angiography of the brain showed hypoplasia of the left vertebral artery [Figure 5]. She was transferred to the neurointensive care unit with a preliminary diagnosis of posterior circulation stroke where antiplatelet treatment was started along with unfractionated

heparin and supportive management. Her vision slowly began to improve from day 4. By the end of 2 months, she regained satisfactory vision with bilateral scotomas with significant resolution of MRI changes in the brain [Figure 6]. At the end of 1 year, she regained her vision significantly with a visual acuity of 20/200 in the right eye and 20/125 in the left eye, and Humphrey Visual Field 24-2 showed a left homonymous incomplete congruous hemianopia extending into the right inferior quadrant [Figure 7]. At the end of 2 years, she had near-normal vision.

Review of literature

We searched PubMed from 1990 to 2020 with the keywords “cortical blindness” and “spine surgery” and “complication.” Our initial search showed 23 articles. On applying additional filters (Human studies, English language), we found 17 articles. After going through the full reports, 12 were excluded, and five cross-references were added, and a total of 10 articles were considered for the present review [Table 1].

Results

There are nine case reports and one retrospective case series. Out of the 80 patients in the reviewed articles, there were 54 males and 25 females while the sex of the

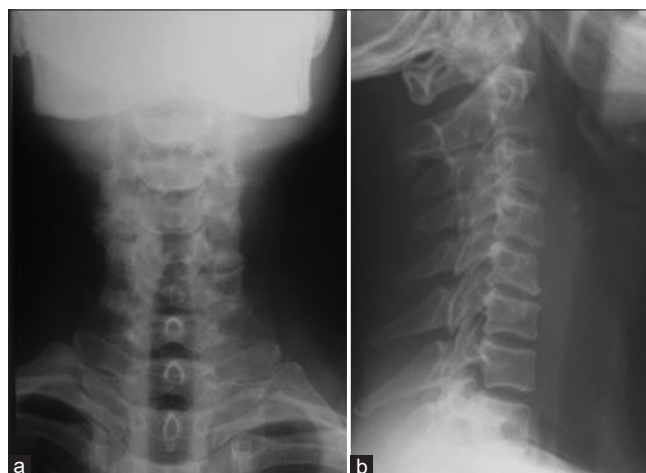

Figure 1: Showing antero-posterior (1a) and lateral (1b) plain radiographs of the cervical spine with spondylotic changes more pronounced at C5–6

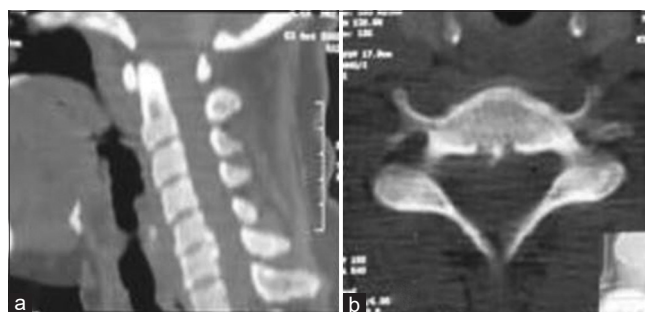

Figure 2: Showing sagittal (2a) and axial (2b) computed tomography scan images of the cervical spine with posterior osteophyte at C5–6

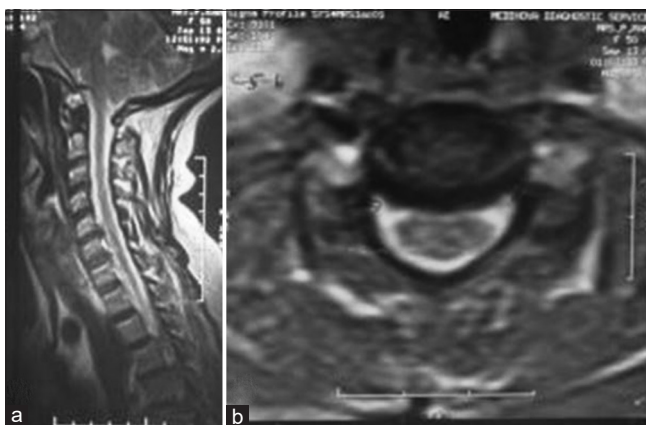


Figure 3: Showing sagittal (3a) and axial (3b) magnetic resonance imaging of the cervical spine with severe right C5–6 foraminal stenosis

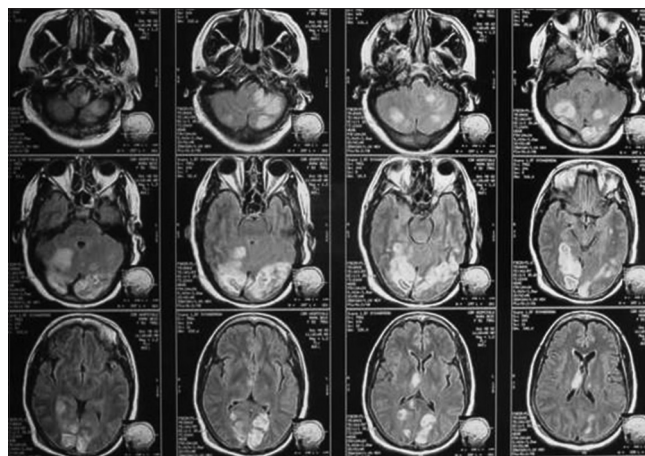


Figure 4: Showing magnetic resonance imaging of the brain with posterior cerebral artery infarct

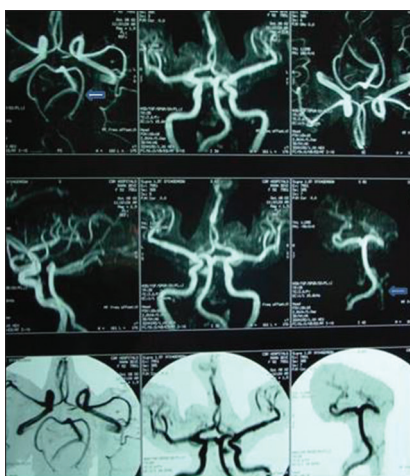


Figure 5: Showing magnetic resonance angiogram of the brain with hypoplasia of the left vertebral artery indicated by block arrow

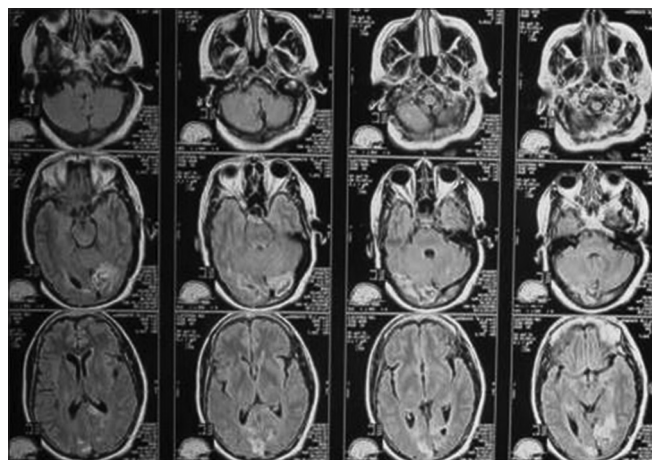


Figure 6: Showing magnetic resonance imaging of the brain showing significant resolution of lesions at 2 months postoperative

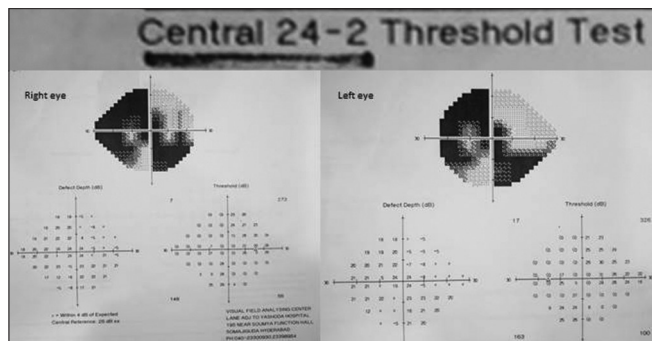


Figure 7: Showing Humphrey Visual Field 24-2 with left homonymous incomplete congruous hemianopia extending into the right inferior quadrant

patient was not disclosed in one case report. Only one patient had cervical spine surgery, and the rest underwent surgery to the dorsolumbar spine or lumbar spine. All the patients underwent surgery in the prone position, while only one patient underwent surgery in the sitting position. Hemodynamic alterations during the surgery were mentioned in three reports. Only 4 out of the 80 patients showed complete recovery of vision at the end of the last follow-up.

Discussion

The majority of the cases of POVL after spine surgery are due to posterior ischemic optic neuropathy (PION) or central retinal artery occlusion (CRAO). The incidence of cortical blindness as a cause for POVL after spine surgery is low when compared to PION or CRAO, with only a handful number of cases reported in the literature to date. When occipital blindness occurs postoperatively; generally, it is the result of the occipital infarction due to embolism or hypotension.^[14] Even though embolic events are most common after cardiac surgeries, intraoperative hypotension as a cause of occipital infarction for POVL after spine surgery has been documented.^[6,8,10] The common risk factors for POVL after spine surgery include prone position, prolonged operative time, anemia, intraoperative hypotension, diabetes, obesity, male sex, use of Wilson frame, excessive blood loss, and excessive intraoperative crystalloid usage.^[2] The symptoms of cortical blindness set in within the first 24 h, but there are cases documented where patients developed visual loss immediately after surgery.^[4] Our patient developed blindness immediately after surgery, but her vision was not checked immediately after surgery nor did she complain of loss of vision until about 9 h after the surgery. She was immediately checked by the spine team as well as by an ophthalmologist. As the pupillary reflex and fundoscopy were normal, clinical diagnosis of cortical blindness was suspected, and the patient was subjected to MRI, which showed PCA infarcts with vertebral artery hypoplasia on the left side. She showed recovery by the end of 1 year with residual visual field defects, which further improved to near-normal vision. Our patient had no documented risk factors for POVL, except for a transient decrease in the MAP to 65 mmHg, even though the exact pathogenesis due to intraoperative hypotension is not very elucidative.^[15] Induced (permissive) hypotension is frequently used in elective spine surgery to reduce the intraoperative blood loss and the need for transfusion. However, it is associated with a small but serious risk of ischemic complications like myocardial infarction.^[16] As the microvascular perfusion of the individual organ systems cannot be assessed directly, it is not advisable to use this technique to reduce blood loss in patients with risk factors for ischemia.^[16] A week prior to her surgery during routine preoperative workup, she was found to have mildly elevated blood pressure, which was completely controlled before surgery by medication. However, MR cerebral angiography was done postoperatively after she developed cortical blindness and not before surgery. The postoperative MR angiography revealed vertebral artery hypoplasia on the left side [Figure 5]. Our patient was not subjected to invasive carotid angiography as the MR angiography showed normal carotids. The incidence of the hypoplastic vertebral artery in one cadaveric study is 10%, with the incidence in literature ranging from 2% to 35%.^[17]

Table 1: The review of literature of cases with cortical blindness after spine surgery from 1990-2020

Author	Number of cases	Age/sex	Spinal region involved	Pathology	Surgery	Position	Duration of surgery
Agarwal <i>et al.</i> ^[4]	1	60/female	Lumbar spine	Metastatic disease	Posterior decompression plus stabilization	Prone	Not mentioned
Vaiano <i>et al.</i> ^[5]	1	54/male	Lumbar spine	Degenerative	Intradiscal ozone therapy	Prone	N/A
Nathan <i>et al.</i> ^[6]	1	11/female	Dorsolumbar spine	Neuromuscular scoliosis	Posterior deformity correction	Prone	675 min
Goni <i>et al.</i> ^[7]	1	38/male	Lumbar spine	Trauma	Posterior spinal decompression and stabilization	Prone	105 min
Huber and Grob ^[8]	1	66/female	Lumbar spine	Degenerative	Posterior spinal decompression and fusion	Prone	195 min
Ibrahim <i>et al.</i> ^[9]	1	67/male	Dorsolumbar spine	Deformity	Deformity correction plus posterior spinal fusion (done in two stages)	Prone	Not mentioned
Mione <i>et al.</i> ^[10]	1	55/male	Lumbar spine	Degenerative	Posterior decompression	Prone	95 min
Vakharia <i>et al.</i> ^[11]	1	The early 60s	Dorsal spine	Metastasis	Tumor resection plus stabilization	Prone	Not mentioned
De la Garza-Ramos <i>et al.</i> ^[12]	70	13.1±2.6 years (average) with 21% females, 70% males	Dorsolumbar spine	Deformity (idiopathic scoliosis)	Deformity correction	Prone	Not mentioned
Stevens <i>et al.</i> ^[13]	2	1) 58/female 2) 57/male	1) Lumbar spine 2) Cervical spine	1) Degenerative scoliosis 2) Kyphotic deformity secondary to ankylosing spondylitis	1) Anterior followed by posterior fusion 2) Posterior cervical osteotomy	1) Supine followed by prone 2) Sitting	Not mentioned
Author	Blood loss	Risk factors for POVL	Hemodynamic alterations during the procedure	Proposed pathogenesis for cortical blindness	The onset of symptoms after the procedure	Recovery	
Agarwal <i>et al.</i> ^[4]	700 ml	Prone position	No	Not mentioned	Immediately after surgery	Not mentioned	
Vaiano <i>et al.</i> ^[5]	N/A	Prone position	No	Air embolism during oxygen-ozone therapy	1 min	Full visual recovery by 9th day	
Nathan <i>et al.</i> ^[6]	1300 ml (820 ml transfused via cell saver)	Prone position, prolonged surgery, excessive blood loss, crystalloid replacement, intraoperative hypotension	Hypotensive anesthesia (lowest intraoperative MAP-37 mmHg)	Hypotensive anesthesia combined with excessive blood loss and fluid replacement	Few hours	Full recovery by 6 months postsurgery	
Goni <i>et al.</i> ^[7]	420 ml	Prone	No	Not mentioned	12 h	No	

Contd...

Table 1: Contd...

Author	Blood loss	Risk factors for POVL	Hemodynamic alterations during the procedure	Proposed pathogenesis for cortical blindness	The onset of symptoms after the procedure	Recovery
Huber and Grob ^[8]	1500 ml	Prone	Short decrease of systolic blood pressure to <85 mm of Hg	1) Abnormal neck posture while positioning 2) Embolization due to accidental puncture of the subclavian artery	Immediately after surgery	No significant improvement at the last follow-up (5 months)
Ibrahim <i>et al.</i> ^[9]	1st stage-3000 ml, 2nd stage-1800 ml	Prone in both stages	No	Occipital seizures after the second surgery	6 h	Regained baseline vision in the 1st week after surgery
Mione <i>et al.</i> ^[10]	-	Prone	Blood pressure reduced to 48 mm of Hg for 12 min	Cerebral hypoperfusion with bilateral fetal posterior cerebral arteries	Few hours after surgery	Blind till last follow-up (2 years)
Vakharia <i>et al.</i> ^[11]	Not mentioned	Prone	No	Not mentioned	Few hours	Complete recovery at last follow-up (2 months after surgery)
De la Garza-Ramos <i>et al.</i> ^[12]	Not mentioned	Prone	Not mentioned	Not mentioned	Not mentioned	Not mentioned
Stevens <i>et al.</i> ^[13]	1) 1000 ml in first stage and 8500 ml in second stage	1) Atrial fibrillation 2) Not mentioned	No	1) Cardioembolic event due to atrial fibrillation 2) Air embolism	1) 4 days after second stage patient developed a left paracentral scotoma 2) 20 h after the surgery	1) 2 years after the surgery, the visual field defect persisted 2) Improved in 4 days after hyperbaric therapy

N/A - Not available; MAP - Mean arterial blood pressure; POVL - Perioperative visual loss

The frequency of posterior circulation stroke is higher in patients with hypoplastic vertebral artery.^[18] Furthermore, in the reviewed literature, few cases had embolic events or occipital seizures that had led to occipital blindness, and neither of these conditions were present in our patient. The combination of transient hypotension with the presence of a single patent vertebral artery might have resulted in the posterior circulation infarct in this patient.

There are cases with cortical blindness due to occipital infarct after spine surgery, but none of them are in the supine position [Table 1]. Our case is the first of its kind reported in the English language literature where we believe that bilateral occipital infarction occurred due to transient intraoperative hypotension leading to reduced posterior circulation flow due to the presence of a single vertebral artery of normal caliber following cervical spine surgery in the supine position. The authors feel that it is important to screen patients planned for cervical spine surgery with MR angiography of the brain including the study of carotids and vertebral arteries in the routine preoperative workup, as it would be a noninvasive test unlike carotid angiogram. As the incidence of vertebral

artery anomalies is high, such patients may be benefitted by strict monitoring of intraoperative blood pressures and avoidance of hypotensive anesthesia to reduce the chance of perioperative stroke. In addition, it would be prudent if the surgeon or anesthetist looks for any apparent visual loss immediately after extubation.

Conclusion

POVL can occur after spine surgery even in the supine position with very minimal blood loss and with no comorbid conditions. The operating team should be watchful of this rare complication. It is now standard practice in our institution to check patients' vision immediately after surgery. Prompt and appropriate investigations and referral to allied specialists are mandatory.

Declaration of patient consent

The authors certify that they have obtained all appropriate patient consent forms. In the form the patient(s) has/have given his/her/their consent for his/her/their images and other clinical information to be reported in the journal. The

patients understand that their names and initials will not be published and due efforts will be made to conceal their identity, but anonymity cannot be guaranteed.

Financial support and sponsorship

Nil.

Conflicts of interest

There are no conflicts of interest.

References

- Baig MN, Lubow M, Immesoete P, Bergese SD, Hamdy EA, Mendel E. Vision loss after spine surgery: Review of the literature and recommendations. *Neurosurg Focus* 2007;23:E15.
- Epstein NE. Perioperative visual loss following prone spinal surgery: A review. *Surg Neurol Int* 2016;7:S347-60.
- Berg KT, Harrison AR, Lee MS. Perioperative visual loss in ocular and nonocular surgery. *Clin Ophthalmol* 2010;4:531-46.
- Agarwal N, Hansberry DR, Goldstein IM. Cortical blindness following posterior lumbar decompression and fusion. *J Clin Neurosci* 2014;21:155-9.
- Vaiano AS, Valente C, De Benedetti G, Caramello G. Transient cortical blindness after intradiscal oxygen-ozone therapy. *Indian J Ophthalmol* 2016;64:944-6.
- Nathan ST, Jain V, Lykissas MG, Crawford AH, West CE. Transient cortical blindness as a complication of posterior spinal surgery in a pediatric patient. *J Pediatr Orthop B* 2013;22:416-9.
- Goni V, Tripathy SK, Goyal T, Tamuk T, Panda BB, Bk S. Cortical blindness following spinal surgery: Very rare cause of perioperative vision loss. *Asian Spine J* 2012;6:287-90.
- Huber JF, Grob D. Bilateral cortical blindness after lumbar spine surgery. A case report. *Spine (Phila Pa 1976)* 1998;23:1807-9.
- Ibrahim TF, Sweis RT, Nockels RP. Reversible postoperative blindness caused by bilateral status epilepticus amauroticus following thoracolumbar deformity correction: Case report. *J Neurosurg Spine* 2017;27:63-7.
- Mione G, Pische G, Wolff V, Tonnelet R, Humbertjean L, Richard S. Perioperative bioccipital watershed strokes in bilateral fetal posterior cerebral arteries during spinal surgery. *World Neurosurg* 2016;85:367.e17-21.
- Vakharia K, Siasios I, Dimopoulos VG, Pollina J. Posterior reversible encephalopathy syndrome resolving within 48 hours in a normotensive patient who underwent thoracic spine surgery. *J Clin Med Res* 2016;8:263-6.
- De la Garza-Ramos R, Samdani AF, Sponseller PD, Ain MC, Miller NR, Shaffrey CI, *et al.* Visual loss after corrective surgery for pediatric scoliosis: Incidence and risk factors from a nationwide database. *Spine J* 2016;16:516-22.
- Stevens WR, Glazer PA, Kelley SD, Lietman TM, Bradford DS. Ophthalmic complications after spinal surgery. *Spine (Phila Pa 1976)* 1997;22:1319-24.
- Williams EL. Postoperative blindness. *Anesthesiol Clin North Am* 2002;20:605-22.
- Bijker JB, Gelb AW. Review article: The role of hypotension in perioperative stroke. *Can J Anaesth* 2013;60:159-67.
- Dutton RP. Controlled hypotension for spinal surgery. *Eur Spine J* 2004;13 Suppl 1:S66-71.
- Iqbal S. Vertebrobasilar variants and their basic clinical implications. *Int J Med Res Heal Sci* 2013;2:799-808.
- Park JH, Kim JM, Roh JK. Hypoplastic vertebral artery: Frequency and associations with ischaemic stroke territory. *J Neurol Neurosurg Psychiatry* 2007;78:954-8.