

Surgical Management of Extraocular Muscle Cysticercosis Causing Optic Foramen Syndrome

Abstract

Extraocular muscle cysticercosis usually presents with proptosis and restriction of eyeball movements. However, it can cause vision loss by compression of the optic nerve at the optic foramen in infrequent circumstances. We report a rare case with an unusual manifestation of ptosis, proptosis, lateral rectus palsy, and acute vision loss in the right eye. Magnetic resonance imaging was suggestive of cysticercal cyst. Emergency optic nerve decompression with cyst excision was done. Treatment of choice for extraocular muscle cysticercosis presenting with restriction of eyeball movements is mainly medical, consisting of albendazole and steroids. However, as this lesion rarely causes vision loss, indications of surgical decompression of optic nerve are not well defined. We recommend that early surgical management should be done along with medical treatment in cases of vision loss caused by extraocular muscle cysticercosis.

Keywords: Extraocular muscle cysticercosis, optic nerve decompression, vision loss

Introduction

Cysticercosis is the most common parasitic disease of the central nervous system worldwide. The unusual location of the cysts may result in uncommon manifestations.^[1] Orbital cysticercosis can involve both the intraocular structures and extraocular muscles.^[2] Although cysticercosis frequently affects extraocular muscles causing the restriction in ocular movements,^[3] optic foramen syndrome being caused by extraocular muscle cysticercosis has not been reported hitherto. Medical management is the treatment of choice for ocular cysticercosis with restriction of eye movements and proptosis, but the management of choice for a case with associated vision loss is not clear.^[4-6] Here, we report a patient with complete vision loss due to extraocular cysticercosis due to optic nerve compression at the optic foramen and its neurosurgical management.

Case Report

A 23-year-old male, a manual laborer by occupation, presented with right eye ptosis and painless rapidly progressive deterioration of vision in the right eye over 20 days with complete loss of vision for

the last 5 days. The vision in the left eye was normal. He had no history of orbital pain, headache, seizure, fever, or vomiting. On examination, he had no perception of light in the right eye with ptosis, proptosis, and restricted abduction of the right eye [Figure 1a and b]. Fundus examination was suggestive of early changes of primary optic atrophy. Left eye examination was completely normal.

Magnetic resonance (MR) imaging of the orbit revealed a septate cystic lesion in the superior rectus muscle near its origin in proximity to the optic canal with resultant compression onto the optic nerve [Figure 1c and d]. Laboratory investigations were within normal limits (eosinophil count -0.2% , serum enzyme-linked immunosorbent assay [ELISA] negative for cysticercus). This clinical presentation was typical for orbital cysticercosis. As the patient had rapidly progressive vision loss due to this cystic lesion in superior rectus muscle which was causing mass effect over the optic nerve, the plan was made to excise the lesion surgically.

Right pterional craniotomy, optic nerve decompression (deroofting of the optic canal) with excision of the cyst, was

**Rajnish Kumar Patidar,
Suryanarayanan Bhaskar,
Jaskaran Singh Gosal,
Mayank Garg,
Deepak Kumar Jha,
Poonam Elhence¹**

Departments of Neurosurgery and ¹Pathology, All India Institute of Medical Sciences, Jodhpur, Rajasthan, India

Address for correspondence:
Dr. Suryanarayanan Bhaskar,
Department of Neurosurgery,
All India Institute of Medical
Sciences, Jodhpur - 342 005,
Rajasthan, India.
E-mail: bhaskar.n surg@yahoo.
com

Access this article online

Website: www.asianjns.org

DOI: 10.4103/ajns.AJNS_280_19

Quick Response Code:



This is an open access journal, and articles are distributed under the terms of the Creative Commons Attribution-NonCommercial-ShareAlike 4.0 License, which allows others to remix, tweak, and build upon the work non-commercially, as long as appropriate credit is given and the new creations are licensed under the identical terms.

For reprints contact: reprints@medknow.com

How to cite this article: Patidar RK, Bhaskar S, Gosal JS, Garg M, Jha DK, Elhence P. Surgical management of extraocular muscle cysticercosis causing optic foramen syndrome. *Asian J Neurosurg* 2020;15:165-7.

Submission: 10-09-2019 Accepted: 25-10-2019

Published: 25-02-2020

done. The lesion was cystic, contained clear fluid, and was removed piecemeal from within the superior rectus muscle. Postoperative MR showed complete excision of the cyst [Figure 1e]. Histopathological examination was suggestive of cysticercosis [Figure 1f]. Unfortunately, there was no improvement in his vision, but ptosis, proptosis, and lateral gaze restriction improved gradually. He was started on oral albendazole (400 mg twice daily) along with a tapering dose of steroids for a month to prevent a recurrence. On follow-up at 6 months, there is still no vision in the right eye, although his right eye extraocular movements have entirely recovered. There is no ptosis or proptosis [Figure 1g and h].

Discussion

Orbital cysticercosis is classified into two types: intraocular or extraocular depending on the site of involvement by the cysticercal cyst. Intraocular involvement consists of cysts in the retina, vitreous, and anterior segment of the eye. Extraocular variety is further classified according to the structure involved by the cyst: extraocular muscles or, very rarely, the optic nerve.^[4,6,7] Extraocular involvement, especially the cysticercal cyst in the extraocular muscle, is the most frequent presentation in Asian countries as compared to Latin countries where the intraocular involvement is more common.^[7] Superior rectus muscle followed by lateral rectus muscle is the most common site of cyst lodgment in the extraocular muscle.^[8]

Vision loss in orbital cysticercosis usually occurs in intraocular form due to subretinal/vitreous inflammatory cysts and nodules. Vision loss rarely occurs in the extraocular type, especially in the extraocular muscle

variety, as the extraocular muscle cysts cause proptosis and restriction in eyeball movements. Vision loss in the extraocular type occurs if the cyst involves the optic nerve directly. Our case was unusual in the sense that the cysticercal cyst in the superior rectus muscle was not only causing the proptosis, ptosis, and restriction of the right eye in the lateral gaze, but was also affecting the vision by compression of the optic nerve at the optic foramen. To the best of our knowledge, there is only one such report in literature, wherein extraocular muscle cysticercal involvement caused vision loss by the compression of optic nerve.^[7] However, in contrast to our case, in that case, the cyst involved the inferior rectus muscle; enzyme-linked immunosorbent assay (ELISA) test for cysticercosis was positive, and the patient was managed medically with albendazole. Although vision loss was complete in that case, the outcome was similar, that is, no improvement was seen in vision after the completion of medical treatment.

Gurha *et al.*^[9] described a case of optic nerve sheath cysticercal cyst in the optic canal in which the patient's vision improved dramatically after surgical deroofting of the optic canal and excision of the cyst. As our patient had presented with a history of rapidly worsening vision loss and the optic nerve was severely compressed at the optic foramen by the cystic lesion along with negative ELISA, we thought that surgical decompression of the optic nerve might give him the best chance of having any improvement in vision. However, the vision did not improve in our patient despite adequate decompression as probably the optic atrophy had already set in. Due to rarity of such presentation and as it has been reported only once before, indications of surgery are not yet well defined in such cases.

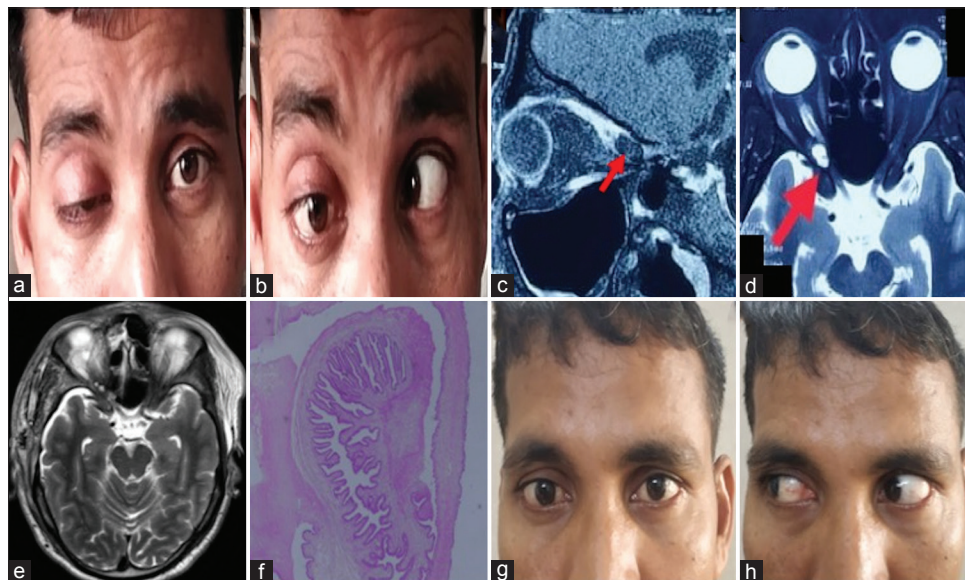


Figure 1: (a and b) Preoperative clinical photographs: right-sided ptosis and restricted abduction of the right eye. (c and d) Magnetic resonance sagittal and axial preoperative images: cysticercal cyst in the superior rectus muscle present at the orbital apex with optic nerve compression. (e) Postoperative T2-weighted axial magnetic resonance: excision of the cyst. (f) Histopathology (H and E, $\times 2$): the larval form of cysticercus with duct-like invaginations lined by double-layered eosinophilic membrane and body wall showing myxoid matrix and calcareous bodies. (g and h) Postoperative clinical images: no ptosis and improvement in extraocular muscle palsy

Medical therapy, combining albendazole with prednisolone, is the recommended treatment for the extraocular muscle form of cysticercosis.^[5,6,8,10] However, in all these series, patients suffered from proptosis and restriction of eyeball movements rather than vision loss. We recommend that surgical decompression of the optic nerve be done if the patient presents early in the course of disease with progressive vision loss.

Conclusion

Orbital cysticercosis is still prevalent in Asian countries, with ocular muscle involvement even more common in endemic areas. Extraocular cysticercosis involving the extraocular muscles can cause vision loss by compression of the optic nerve at the optic foramen. Early diagnosis and surgical decompression of the optic nerve is essential in order to avoid permanent vision loss.

Declaration of patient consent

The authors certify that they have obtained all appropriate patient consent forms. In the form the patient(s) has/have given his/her/their consent for his/her/their images and other clinical information to be reported in the journal. The patients understand that their names and initials will not be published and due efforts will be made to conceal their identity, but anonymity cannot be guaranteed.

Financial support and sponsorship

Nil.

Conflicts of interest

There are no conflicts of interest.

References

1. Sawhney IM, Singh G, Lekhra OP, Mathuriya SN, Parihar PS, Prabhakar S. Uncommon presentations of neurocysticercosis. *J Neurol Sci* 1998;154:94-100.
2. David S, Mathai E. Ocular cysticercosis – A review of 25 cases. *J Assoc Physicians India* 2000;48:704-7.
3. Dhiman R, Devi S, Duraipandi K, Chandra P, Vanathi M, Tandon R, *et al.* Cysticercosis of the eye. *Int J Ophthalmol* 2017;10:1319-24.
4. Rath S, Honavar SG, Naik M, Anand R, Agarwal B, Krishnaiah S, *et al.* Orbital cysticercosis: Clinical manifestations, diagnosis, management, and outcome. *Ophthalmology* 2010;117:600-5, 605.e1.
5. Surve A, Goel S, Bajaj MS, Pujari A. Extraocular muscle cysticercosis: Never skip steroids. *BMJ Case Rep* 2018;2018. pii: bcr-2017-223356.
6. Murthy R, Samant M. Extraocular muscle cysticercosis: Clinical features and management outcome. *Strabismus* 2008;16:97-106.
7. Goyal JL, Das S, Kumar S, Chauhan D, Baheti U, Sangit V. Retrobulbar cysticercosis masquerading as optic nerve glioma. *Orbit* 2007;26:61-3.
8. Mohan K, Saroha V, Sharma A, Pandav S, Singh U. Extraocular muscle cysticercosis: Clinical presentations and outcome of treatment. *J Pediatr Ophthalmol Strabismus* 2005;42:28-33.
9. Gurha N, Sood A, Dhar J, Gupta S. Optic nerve cysticercosis in the optic canal. *Acta Ophthalmol Scand* 1999;77:107-9.
10. Das KK, Gosal JS, Singh S, Mehrotra A, Jaiswal A, Jaiswal S, *et al.* Solitary Cysticercal Cyst Inside the Blake's Pouch Remnant of Mega Cisterna Magna with Associated Aqueductal Stenosis: Clinical and Management Implications. *World Neurosurg* 2017;102:693.e1-693.e5.