

Endoscopic Approach to Subcortical (Lobar) Hemorrhage

Abstract

Objective: To highlight the basic points of brain endoscopic procedure for Subcortical (Lobar) Hemorrhage to achieve repeatability and reproducibility in the results among the new brain endoscopic surgeons. **Method:** Sharing the experience of 10 years as an endoscopic surgeon to bring out the basic insight into the method, challenges, points which need special attention during the surgery and discussion of recent advancements in the endoscopic equipment for safe surgery. **Conclusion:** Procedure of endoscopic evacuation of brain hematoma is simple with learning curve. In the beginning new endoscopic surgeons should operate in the presence of experience surgeon. They should follow standard technique to achieve the good surgical outcome and uniformity in the result every time they perform the surgery.

Keywords: Endoscope, hemorrhage, subcortical

Introduction

According to the Guidelines of the treatment of stroke 2015^[1] indication for the treatment of subcortical hemorrhage, we should take into consideration the following factors:

1. Disturbance of consciousness
2. Volume of blood more than 30 ml or more
3. Activities of daily living (ADL) is affected
4. General condition of the elderly patients
5. Expectation of the family member of the patient
6. Chances of clinical improvement after the surgery
7. Timing of operation should be done earliest to prevent secondary injury. However, in some cases, waiting is good for the patients.

Before the Procedure

Timing of the operation

In elderly patients, there are many comorbid conditions which need to be evacuated in shorter time and under local anesthesia (LA). It is better to wait for 72 h–1 week to allow for the softening of the hematoma. However, the timing of operation should be guided by the general condition and the symptoms of the patients. In such cases, we should expect

hard hematoma and bleeding if operated before 72 h.

Preoperative evaluation

We should always check for the vessel abnormality with magnetic resonance angiography and computed tomographic (CT) angiography as we have to operate with one suction tube and bleeding can be troublesome. Especially in subcortical cases, we should check for arteriovenous malformations and arteriovenous fistulas. If there is a possibility of the bleeding, we should not go for the endoscopic procedure.

Preparation of instruments

We require the general instruments for burr hole or small craniotomy or enlargement of the translucent sheath, suction tube, rigid endoscope, View site™ Brain Access System (Vycor Medi-cal) [Figure 1], operating bipolar. Flexible endoscope is required, especially for the subcortical bleed. Training is required to keep the endoscope in position and introducing suction through the port. If port is not available, we may need spatula and microscope system.

Anesthesia

The writer prefers LA with some sedation (propofol/dexmedetomidine) in patients who have altered consciousness

**Daisuke Suyama,
Brajesh Kumar¹,
Saiko Watanabe²,
Riki Tanaka²,
Yasuhiro Yamada²,
Tsukasa Kawase²,
Yoko Kato²**

*Department of Neurosurgery,
Fuchu Keijinkai Hospital,
Fuchu, Tokyo 183-8507,*

*²Department of Neurosurgery,
Banbuntane Hotokukai
Hospital, Fujita University,
Nagoya 454-8509, Japan,*

*¹Department of Neurosurgery,
Ruban Hospital Patliputra,
Patna, Bihar, India*

Address for correspondence:

*Dr. Brajesh Kumar,
House No-15, Gokul Marg,
North S. K. Puri, Boring Road,
Patna - 800 013, Bihar, India.
E-mail: drbrajesh78@gmail.com*

Video Available on:
www.asianjns.org

Access this article online

Website: www.asianjns.org

DOI: 10.4103/ajns.AJNS_216_17

Quick Response Code:



How to cite this article: Suyama D, Kumar B, Watanabe S, Tanaka R, Yamada Y, Kawase T, et al. Endoscopic approach to subcortical (Lobar) hemorrhage. *Asian J Neurosurg* 2019;14:67-71.

This is an open access journal, and articles are distributed under the terms of the Creative Commons Attribution-NonCommercial-ShareAlike 4.0 License, which allows others to remix, tweak, and build upon the work non-commercially, as long as appropriate credit is given and the new creations are licensed under the identical terms.

For reprints contact: reprints@medknow.com

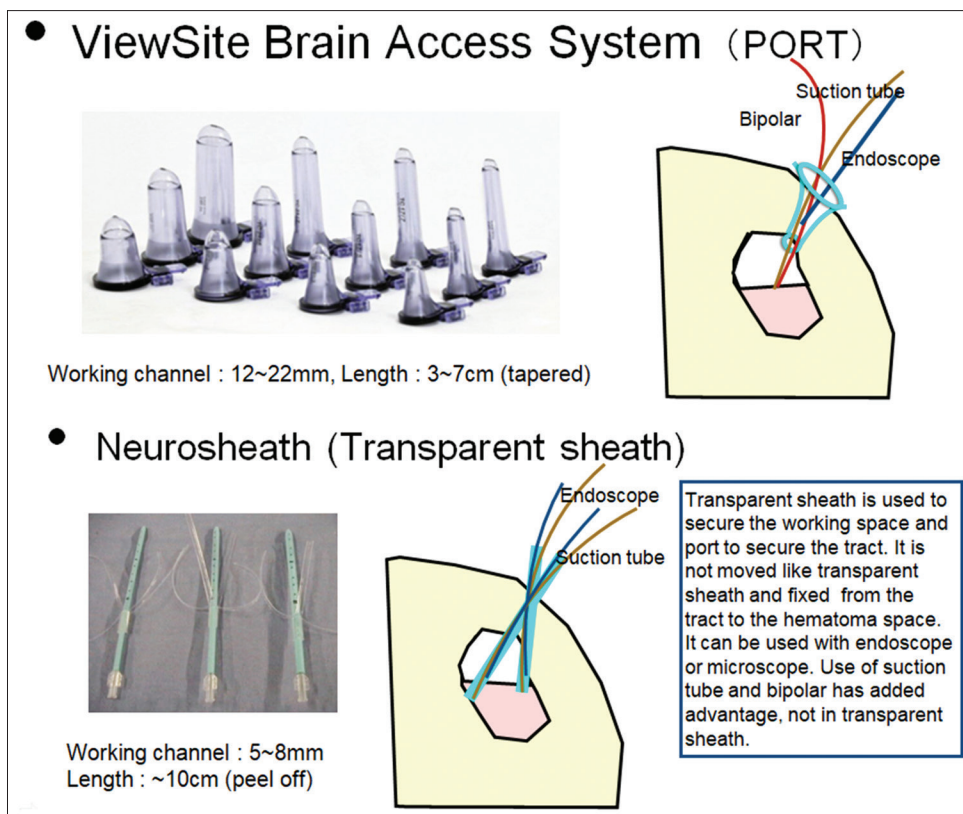


Figure 1: Instrument used

and those who cannot obey commands. In other patients, writer prefers general anesthesia.

Making burr hole, puncture of dura and position

For endoscopic evacuation, we should not go by closest point of hematoma by CT. We think normally that this will easy to remove from there, but this is a pitfall as cannot see the part of hematoma close to the endoscope and we may lose the orientation. This philosophy of the closest point entry works better in the deeper lesions where we can move endoscope in rotating manner and see the margins of hematoma. CT axial image [Figure 2], OM line only shows the wideness of hematoma not the depth of hematoma [Figure 3]. When enter vertical to the hematoma (90°), we can view wider area and burr hole should be put on the upper side of the hematoma. All the view (axial, coronal, and sagittal) should be taken into consideration for marking the burr hole point and marker should be placed on the skull [Figures 2]. Puncture point should be directed vertically directed toward the center of hematoma [Figure 4]. We should always reconsider the scan and match the marker and puncture point before making burr hole. If we make big skin incision, there is a mismatch between marker and the puncture point, and we may lose the orientation even if the difference is <1 cm as subcortical hemorrhage may come close to the surface.

The patient should be in comfortable position with padding of all pressure points. Puncture point should be highest. Brain shift should always be kept in mind.

Evacuation of the Hematoma

In putaminal hemorrhage case, we start the hematoma evacuation from the margin of the hematoma, but in the subcortical hemorrhage, we cannot observe the whole border of the hematoma, so we should approach from the center of the hematoma. After some decompression, the brain gradually shifts down. We should come out hematoma close to the surface is then evacuated. Then, again deeper part of the hematoma is evacuated. We should always keep in mind [Figure 5] the limitation of movement of endoscope and should not go laterally below the angle of the sheath [Figure 6]. If the center of hematoma cannot be evacuated, this implies it is hard. Then, we need to move the position of the sheath and need bigger suction but decreases the field of vision. We need neural sheath 2.7 mm, rigid endoscope, and 4-mm suction tube. If we cannot remove with 4-mm suction, then we can try to remove sheath together with the suction and clots comes along with that. If we fail again, we need tumor-holding forceps to hold or crush the hematoma which can remove with the suction.

We should always keep in mind the brain shift during the procedure [Video].

Hemostasis

Bleeding is mostly on the lateral side and closer to the brain surface. These points are difficult to check by the rigid endoscope, so flexible endoscopes are required. Irrigation

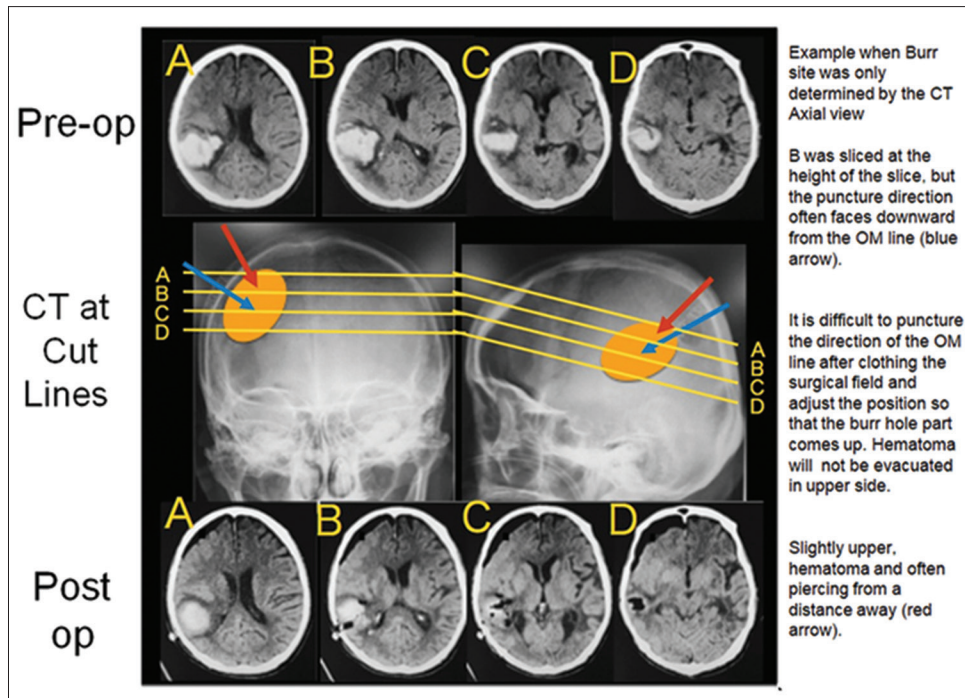


Figure 2: Hematoma localization

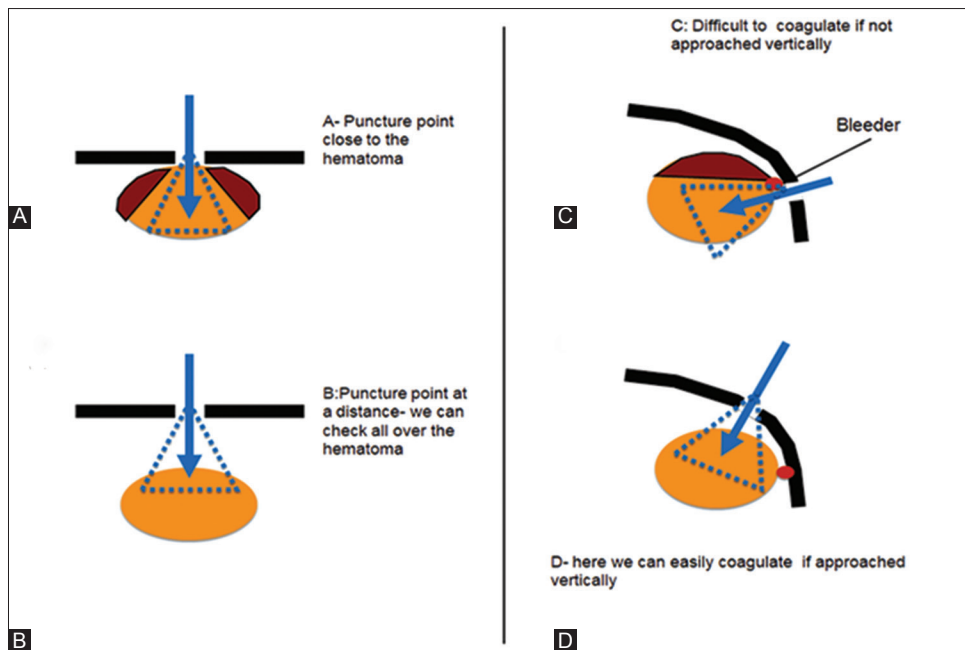


Figure 3: (a-d) Philosophy of Entry Point

is important for the controlling the small bleedings. Blind coagulation should not be done. We should always see the bleeding point by adequate irrigation before going for the coagulation as there may be some bigger vessel which may cause clinical deterioration.

After the removal of hematoma, we remove the translucent sheath and irrigate from the burr hole point. We also put the tip of flexible endoscope to the burr hole and irrigate

the hematoma cavity till clear fluid comes out. If water is not clear, we keep on irrigating and wait for 10–15 min till clear water comes out. If it is not clear in spite of this, we decrease blood pressure <100 mmHg and continue irrigation. Hemostasis is mostly achieved with this maneuver. If it is not clear even after this, we should consider oozing from near the surface. We take flexible endoscope and proceed to the deepest point and then come back near to the surface slowly checking around the bleeding point. We will find

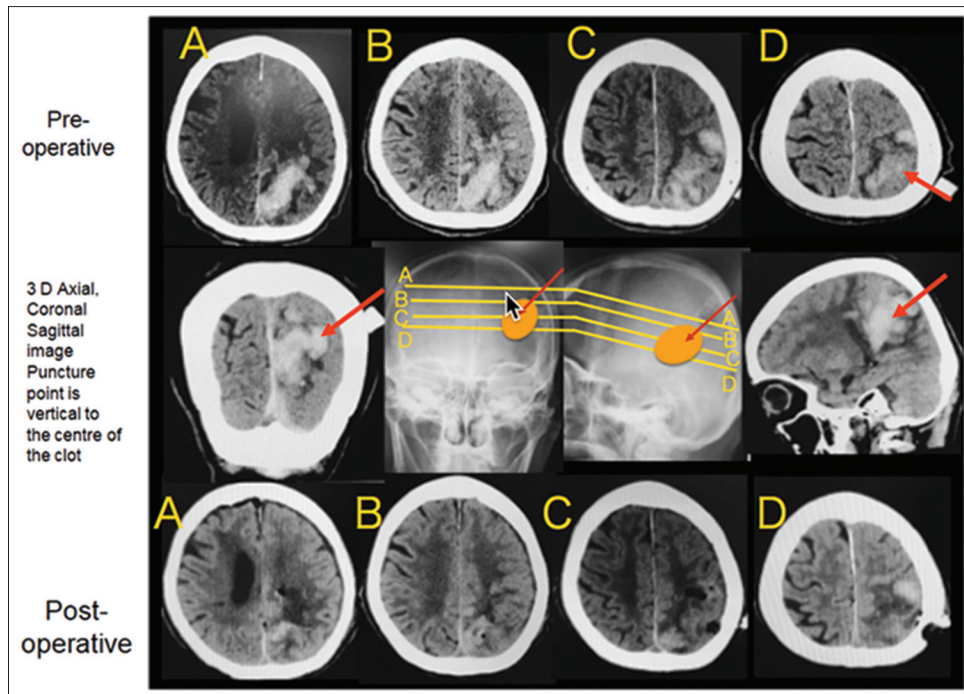


Figure 4: Placement of Puncture Point

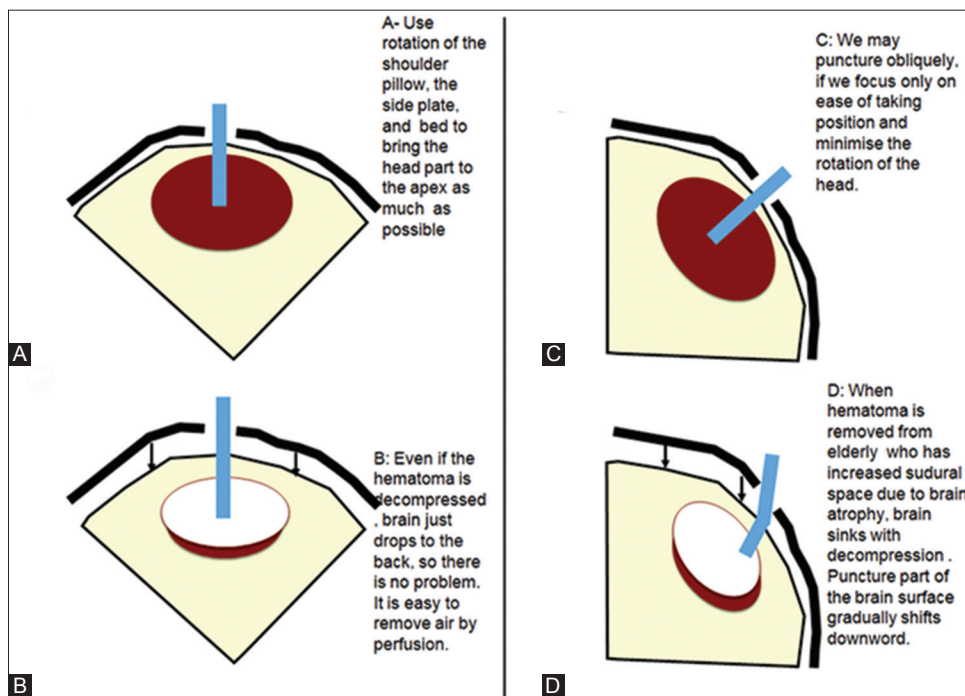


Figure 5: (a-d) Head Position for hematoma removal

some bleeding point and should irrigate directly over the bleeding point [Figure 7]. Water pressure can stop the bleeding. If we have coagulation system over the flexible endoscope, we coagulate during the irrigation. Even after this if there is no hemostasis, we should put translucent sheath again coagulate the vessel with monopolar with big suction tube. We can control lateral side bleeding by putting pressure with surgical cotton.

Conclusion

The purpose of operating subcortical hematoma in the elderly are as follows:

- Early recovery of the altered consciousness
- Increase in ADL.

This result we can also get by the partial decompression of hematoma if we think about short operating time and

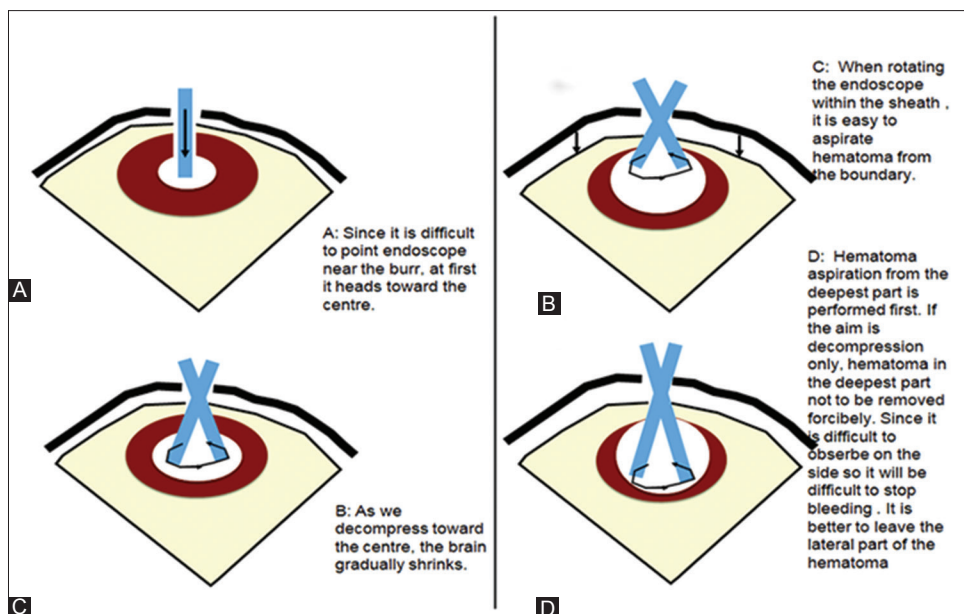


Figure 6: (a-d) Hematoma Removal

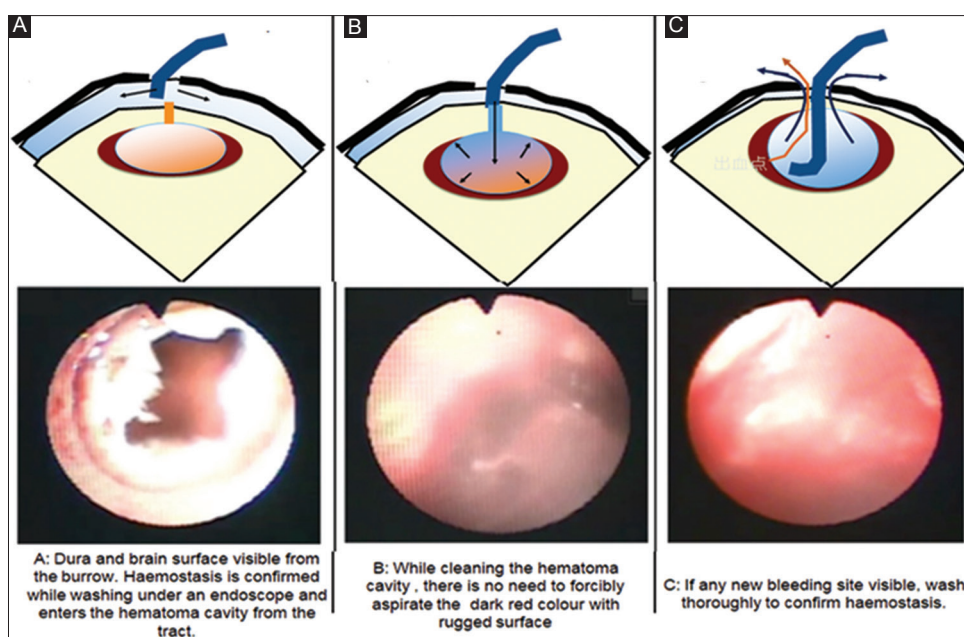


Figure 7: (a-c) Hemostasis

safety of the patient. If one prefers the total removal of the hematoma and to check the original bleeding point, it is better to go for craniotomy if one cannot wait till softening of the hematoma. Result wise, there is no difference observed by the author in the result of evacuation by endoscopy or craniotomy. The big difference by endoscopy is that surgeon has to always alert regarding brain shift just under the burr hole. Technically, it is important to observe the subdural space and hematoma cavity by the flexible endoscope. Those who are less experienced should make bigger burr hole.

Financial support and sponsorship

Nil.

Conflicts of interest

There are no conflicts of interest.

Reference

1. Ishihara H, Suzuki M. Japanese guidelines for management of stroke 2015. *Nihon Rinsho* 2016;74:677-80.