

## Meningitis for *Streptococcus salivarius* Secondary to Paradoxical Cerebrospinal Fluid Rhinorrhea as a Complication of Retrosigmoid Approach

### Abstract

Rhinorrhea secondary to a retrosigmoid approach is rare, but when it manifests, it is due to a paradoxical cerebrospinal fluid (CSF) leak, as a result of the communication between the mastoid cells, middle ear, and eustachian tube, which finally ends on the release of CSF through the nasopharynx. Abnormal communications increases the risk of infections, not only at the surgical site but also through an ascending path. Magnetic resonance cisternography (MRC) with intrathecal gadolinium injection through a lumbar puncture not only allows an adequate diagnosis but also helps to establish management plans. Here, we present an eighty-three-year-old female patient, with a history of trigeminal neuralgia, who underwent retrosigmoid approach to perform trigeminal microvascular decompression. After intervention, the patient consulted for rhinorrhea, fever, and headache. Lumbar puncture was performed, resulting on the isolation of *Streptococcus salivarius* in CSF. Nuclear MRC with intrathecal gadolinium injection was performed, identifying a paradoxical CSF leak. Failure in medical management with conservative treatment ends in surgical reexploration, identifying a bone defect in mastoid cells, which was corrected.

**Keywords:** Nuclear magnetic resonance cisternography, paradoxical cerebrospinal fluid rhinorrhea, retrosigmoid approach, *Streptococcus salivarius*

### Introduction

The presence of rhinorrhea is a manifestation of the outflow of cerebrospinal fluid (CSF), due to the presence of an abnormal communication between the subarachnoid space, the middle ear, and the nasal cavity. Approximately 70% of CSF leaks are corrected spontaneously without the need for surgical intervention. Even so, patients who report this symptom remain at risk of recurrent rhinorrhea, pneumocephalus, and meningitis.<sup>[1]</sup> The mainstay of surgical treatment is the correct locating of the defect.<sup>[2]</sup>

Rhinorrhea can also occur in abnormal communications, due to posterior fossa and middle fossa approaches; these defects are called paradoxical CSF leaks.<sup>[3,4]</sup>

We describe a case report of paradoxical CSF rhinorrhea as a consequence of a retrosigmoid approach.

### Case Report

An eighty-three-year-old female patient presented with a history of arterial

hypertension, diabetes mellitus, and trigeminal neuralgia, who underwent trigeminal microvascular decompression by retrosigmoid approach where vascular lobe of the superior left cerebellar artery was found with arachnoid adhesions in the left V3 branch of the trigeminal nerve, with subsequent surgical release. In the postoperative period, remission of craniofacial pain was evidenced; there was no evidence of residual cranial nerves compromise or CSF leaks. Due to favorable clinical evolution, the patient's egress was decided.

Three months after surgery, the patient reconsulted because of clinical symptoms of 1-day global headache, constant 10/10 intensity, multiple emetic episodes, and walking instability. At physical examination, pain with palpation was found at the surgery site, surgical wound without signs of infection, and tremor of intention on both upper limbs, with no other findings on neurological examination. Rhinorrhea was also found.

Laboratory tests were performed, with evidence of leukocytosis of 18,290 u/l

**María Paula Vargas Osorio,  
Juan Esteban Muñoz Montoya<sup>1</sup>,  
Marco Luciano Charry Lopez<sup>2</sup>,  
Luis Orlando Rojas Romero<sup>1</sup>**

Medicine Undergraduate, Universidad Militar Nueva Granada, <sup>1</sup>Department of Neurosurgery, Hospital Militar Central, Universidad Militar Nueva Granada, <sup>2</sup>Department of Neuroradiology, Hospital Militar Central, Bogota, Colombia

#### Address for correspondence:

Dr. Juan Esteban Muñoz Montoya,  
Department of Neurosurgery,  
Hospital Militar Central,  
Universidad Militar Nueva Granada,  
Bogotá, Colombia.  
E-mail: juanesteban1285@gmail.com

#### Access this article online

Website: [www.asianjns.org](http://www.asianjns.org)

DOI: 10.4103/ajns.AJNS\_179\_18

#### Quick Response Code:



**How to cite this article:** Vargas Osorio MP, Muñoz Montoya JE, Charry Lopez ML, Rojas Romero LO. Meningitis for *Streptococcus salivarius* secondary to paradoxical cerebrospinal fluid rhinorrhea as a complication of retrosigmoid approach. Asian J Neurosurg 2019;14:310-3.

This is an open access journal, and articles are distributed under the terms of the Creative Commons Attribution-NonCommercial-ShareAlike 4.0 License, which allows others to remix, tweak, and build upon the work non-commercially, as long as appropriate credit is given and the new creations are licensed under the identical terms.

For reprints contact: [reprints@medknow.com](mailto:reprints@medknow.com)

and neutrophilia of 85.1%, with a C reactive protein of 17.8 mg/dl. In addition, cranial computerized axial tomography (CT) showed evidence of postoperative changes from the left retrosigmoid craniectomy, which consisted on the presence of retromastoid collection and pneumocephalus [Figure 1].

Due to cranial CT findings, it was decided to perform a lumbar puncture to study meningitis. Purulent CSF sample was obtained, with an opening pressure of 10 cm of water. Samples were taken for culture, and treatment with broad-spectrum antibiotics – vancomycin, metronidazole, and cefepime – was started. The results of CSF analysis were obtained with positive parameters for infection given by 1076 mg/dl, glucose 81 mg/dl, leukocytes 15,170 cells/ml and multisensitive *Streptococcus salivarius* isolation in CSF culture; consequently, it was decided to change the antibiotic scheme to ceftriaxone 2 g every 12 h intravenously for 21 days.

Subsequently, due to the persistence of rhinorrhea, the need for a study of CSF leak by means of nuclear magnetic resonance cisternography (MRC) with intrathecal gadolinium injection via lumbar puncture was considered. It confirmed the presence of paradoxical CSF rhinorrhea [Figure 2]. Medical treatment was established initially with acetazolamide for 7 days combined with lumbar drain for 5 days, even if thought it failed to control CSF leak. Finally, the patient was taken to surgical reintervention for management.

Before the surgical procedure, a new lumbar puncture for CSF study was decided, with no germ isolated in the culture, glucose: 58 mg/dl, proteins: 100 mg/dl, and leukocytes 5 cells/ml.

During the surgical procedure at the opening of mastoid cells, a cyst with CSF in its interior was found in the left retrosigmoid region. Cell sealing was performed using bone wax; dura mater was covered with fat and muscle grafts, in combination with primary anatomic closure of the

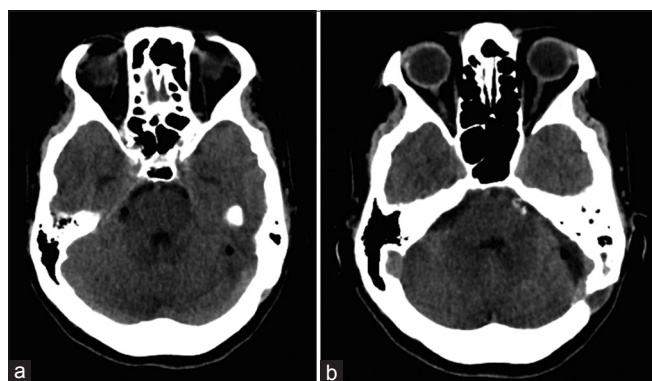

Figure 1: (a) Presence of air at the level of the cerebellum, and interpeduncular and crural cisterns and (b) Partial disruption of the posterior mastoid cells with left mastoid occupation, associated with a retrosigmoid bone defect

dural defect, reconstruction with bone cement, and lumbar drainage without complications.

The patient continued with favorable postoperative evolution. It was revalued 3 months, 6 months, and 1 year postoperatively, asymptomatic, without retromastoid collection and no rhinorrhea.

## Discussion

Retrosigmoid approach has been used on the removal of brain tumors, the sectioning of the vestibular nerve, auditory brainstem implantation, and microvascular decompression of nerves in their intracranial trajectory. In these cases, rhinorrhea is a rare complication that can appear as a postoperative complication.<sup>[5]</sup>

The most frequent complications of the retrosigmoid approach are cerebellar trauma, venous sinus injury, cranial nerve involvement, vascular and brainstem involvement, and CSF leaks, which may occur through the surgical wound or may result in rhinorrhea.<sup>[6]</sup>

Other surgeries that can produce this phenomenon are the translabyrinthine and transcochlear approaches, although it is observed more in patients who undergo tumor resections,<sup>[1]</sup> mainly of tumors located in the region of the cerebellopontine angle.<sup>[7]</sup> The retrosigmoid approach

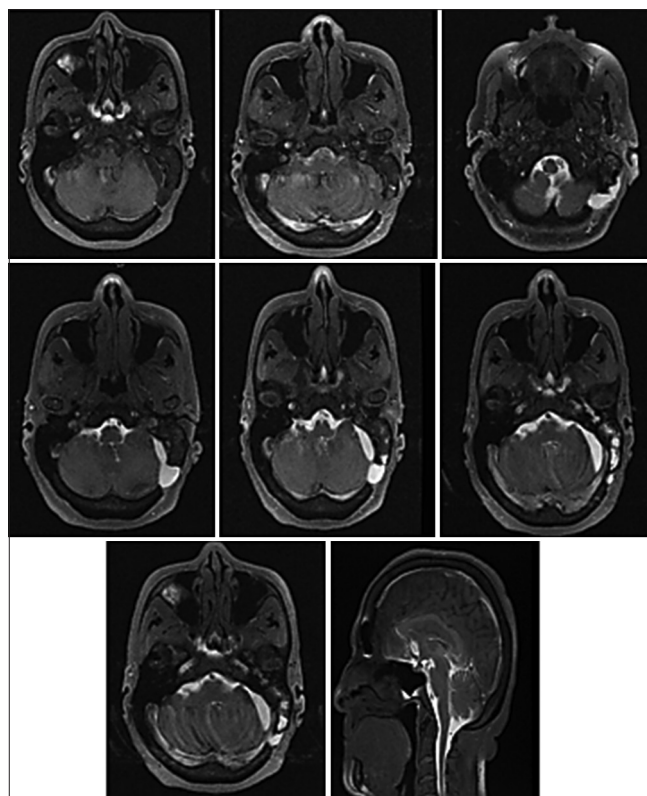


Figure 2: Nuclear magnetic resonance cisternography with intrathecal gadolinium injection through lumbar puncture: The left retromastoid continuity solution is seen with the mastoid cavity, which appears occupied by contrast material, extending from the eustachian tube to the nasopharynx, which confirms paradoxical leak

may result in the discharge of CSF at the site of incision or through the ipsilateral cavity via the mastoid cells, middle ear, and the eustachian tube.<sup>[5]</sup>

In the previous case report, a retrosigmoid approach was performed to achieve trigeminal microvascular decompression, but it was complicated by rhinorrhea, as described in the literature.

Physiopathologically, rhinorrhea manifest consequently to the presence of a paradoxical leak of CSF, which occurs due to the opening of mastoid or perilyabyrinthine cells in a iatrogenic manner, communicating with the middle ear, through the vestibular tract or the round window, by the eustachian tube.<sup>[2,6]</sup> This has been described in Mondini dysplasia<sup>[8]</sup> and in the removal of epidermoid cyst located in the cerebellopontine angle region.<sup>[9]</sup>

The presence of an abnormal communication leading to the apparition of rhinorrhea is potentially risk, since it can become a great chance for the development of an ascending infection, which can result in fulminant meningitis.<sup>[10]</sup> The CSF leak increases a 10% risk per year of developing meningitis.<sup>[11]</sup>

According to the Daudia *et al.*'s study, the overall risk of meningitis in patients with persistent CSF rhinorrhea was 19%, with an annual incidence of 0.3 episodes/year of meningitis, with many of meningitis episodes occurring during the 1<sup>st</sup> year of leak appearance.<sup>[12]</sup>

The most frequently isolated bacteria in CSF, of patients with meningitis secondary to neurosurgical procedures, trauma, and CSF leak, are reported to be *Streptococcus pneumoniae*, *Staphylococcus aureus*, *Enterobacteriaceae*, and *Pseudomonas aeruginosa*.<sup>[13]</sup> Even so, bacterial meningitis caused by *S. salivarius* is rarely reported in literature.<sup>[14]</sup>

*S. salivarius* is classified within the group of Gram-positive cocci bacteria, isolated for the first time from samples of the human oral cavity.<sup>[15]</sup> It is a common commensal located in the skin, gastrointestinal tract, genitourinary tract, oral cavity, and paranasal sinuses. Even when it is considered a microorganism with low virulence, it can cause life-threatening infections, particularly endocarditis.<sup>[14]</sup>

Nowadays, there are several diagnostic methods for the approximation in the study of CSF leak.<sup>[16]</sup> Nuclear magnetic resonance cisternography (MRC) and computed tomography cisternography (CTC), both procedures performed after intrathecal gadolinium injection through a lumbar puncture, have gained great acceptance for the adequate localization of the abnormal communication, and are currently the chosen study in CSF leaks with intermittent low-flow rhinorrhea.<sup>[4]</sup>

MRC with gadolinium injection through lumbar puncture, used as diagnostic allows to identify the temporal bone defect and the exact location of the leak. If the defect is

located in the mastoid cells, mastoid antrum, middle ear, or eustachian tube and it communicates with the nasopharynx, as the described case of Thomas *et al.*'s study,<sup>[2]</sup> it also leads to find defects in the anterior and posterior fossa, with the advantage of having better penetration to fractures and small dural lacerations, with a sensitivity from 85% to 92% and a specificity of 100% for diagnosis. Furthermore, it allows the development of intervention strategies.<sup>[4]</sup>

Intrathecal gadolinium-enhanced MRC is a promising technique that may permit direct sensitive visualization of the site of the leakage,<sup>[10]</sup> Wezel and Leppien presented a case in which CSF leak was detected only by MRC, whereas CT didn't detect CSF leak nor bone defect.<sup>[1,16]</sup>

MRC after the intrathecal administration of gadolinium represents an effective and minimally invasive method for evaluating suspected CSF fistulas along the skull base. It provides multiplanar capabilities without risk of radiation exposure and an excellent approach to depict the anatomy of CSF spaces and CSF fistulas.<sup>[1]</sup>

In the study described by Aydin *et al.*, gadolinium-enhanced MRC demonstrated CSF leaks in 43 of the 51 patients included. The sensitivity of gadolinium-enhanced MRC for localization of CSF leaks was 84%. Forty-four patients underwent surgery to repair dural tears. Surgical findings confirmed the results of gadolinium-enhanced cisternography in 43 of the 44 patients who underwent surgery (98%). Eight patients with negative gadolinium-enhanced MRC had no active rhinorrhea at the time of procedure, and seven of them did not need surgery. None of the patients developed an acute adverse reaction that could be attributed to the procedure. None of the patients developed any neurological symptoms or signs caused by intrathecal gadolinium injection during a mean follow-up period of 4.12 years.<sup>[17]</sup>

In the previous case report, intrathecal gadolinium-enhanced MRC allowed us to observe the paradoxical leak from the mastoid cells through visualizing the passing contrast by the eustachian tube and then the nasopharynx. This not only let us to diagnose but also to carry out a surgical plan.

When carrying out the management of CSF leaks, two behaviors can be performed: (1) Initially, conservative management should be performed, which includes rest, elevation of the head, and pharmacology therapy in order to reduce CSF production and (2) The performance of invasive procedures such as the placement of a lumbar drain and finally surgical reexploration should be considered when conservative management fails.<sup>[5]</sup>

Postoperative CSF leakage after a retrosigmoid approach continues to be considered a feared complication and represents an economic problem for both the patient and the hospitals.<sup>[18]</sup> In addition to this, there are risk factors that increase the appearance of CSF fistulas, such as the body mass index. Many techniques have emerged for the

correction of CSF leakage including fat, muscle, and galea grafts, alone or in combination, primary anatomic closure of the dural defect, reconstruction with bone cement, and lumbar drainage.<sup>[18]</sup>

When conservative medical treatment fails it can be related to the identification of bone defects in the mastoid cells and dural tears during surgical reexploration. Montgomery initially introduced the use of fat as graft material to pack in the petrosal and mastoid apex.<sup>[19]</sup> Jackler then recommended the use of muscle fascia portion to cover the associated dural defect with fat strips over the fascia.<sup>[20]</sup>

The use of bone wax and bone plates (bone pate) are rarely used in acoustic neuroma surgeries, even though many surgeons resect the mastoid cells with bone wax in retrosigmoid approaches, as recommended by Falcioni in his study.<sup>[21,22]</sup>

As, in our case, the conservative management with acetazolamide and lumbar drain failed, consequently the patient was taken to direct correction of the bone and dural defect in the posterior fossa with bone wax and closure of the dural defect.

## Conclusion

Nuclear MRC with gadolinium injection intrathecally through a lumbar puncture is a save diagnostic, method with a good sensitivity and specificity for the diagnosis of CSF leak, such as a paradoxical leak. Paradoxical cerebrospinal fluid rhinorrhea increases the risk of meningitis, leading to the need of recommending performing a conservative or surgical intervention for its management.

## Declaration of patient consent

The authors certify that they have obtained all appropriate patient consent forms. In the form, the patient has given her consent for her images and other clinical information to be reported in the journal. The patient understands that name and initials will not be published and due efforts will be made to conceal identity, but anonymity cannot be guaranteed.

## Financial support and sponsorship

Nil.

## Conflicts of interest

There are no conflicts of interest.

## References

- Selcuk H, Albayram S, Ozer H, Ulus S, Sanus GZ, Kaynar MY, et al. Intrathecal gadolinium-enhanced MR cisternography in the evaluation of CSF leakage. *AJNR Am J Neuroradiol* 2010;31:71-5.
- Thomas B, Purkayastha S, Vattoth S. CT Cisternography of paradoxical cerebrospinal fluid rhinorrhea after operation for acoustic neuroma. *Neuroradiol J* 2005;18.
- Bhalodiya NH, Joseph ST. Cerebrospinal fluid rhinorrhea: Endoscopic repair based on a combined diagnostic approach. *Indian J Otolaryngol Head Neck Surg* 2009;61:120-6.
- Ziu M, Savage JG, Jimenez DF. Diagnosis and treatment of cerebrospinal fluid rhinorrhea following accidental traumatic anterior skull base fractures. *Neurosurg Focus* 2012;32:E3.
- Sirikici A, Bayazit Y, Bayram M, Kervancioglu R. MRI findings simulating CSF leakage on routine imaging. *Turk J Diagn Interv Radiol* 2000;6:283-6.
- Elhammady MS, Telischi FF, Morcos JJ. Retrosigmoid approach: Indications, techniques, and results. *Otolaryngol Clin North Am* 2012;45:375-97.
- Bazowski P, Kwiek S, Ignasiak B. Petronasal fistula caused by the epidermal cyst of the cerebellopontine angle region. *Otolaryngol Pol* 1996;50:173-7.
- Bayazit YA, Celenk F, Duzlu M, Goksu N. Management of cerebrospinal fluid leak following retrosigmoid posterior cranial fossa surgery. *ORL* 2009;71:329-33.
- Deenadayal DS, Kumar MN, Pandaredathil S, Patel SH. Mondini dysplasia with paradoxical cerebrospinal fluid rhinorrhea. *Otolaryngol-Head and Neck Surg* 2010;144:851-2.
- Ragheb AS, Mohammed FF, El-Anwar MW. Cerebrospinal fluid rhinorrhea: Diagnostic role of gadolinium enhanced MR cisternography. *Egypt J Radiol Nucl Med* 2014;45:841-7.
- Eljamel MS. The Role of Surgery and Beta-2-Transferrin in the Management of Cerebrospinal Fluid Fistula [Thesis]. Liverpool, England: University of Liverpool; 1993.
- Daudia A, Biswas D, Jones NS. Risk of meningitis with cerebrospinal fluid rhinorrhea. *Ann Otol Rhinol Laryngol* 2007;116:902-5.
- Thigpen MC, Whitney CG, Messonnier NE, Zell ER, Lynfield R, Hadler JL, et al. Bacterial meningitis in the United States, 1998-2007. *N Engl J Med* 2011;364:2016-25.
- Conangla G, Rodríguez L, Alonso-Tarrés C, Avila A, de la Campa AG. *Streptococcus salivarius* meningitis after spinal anesthesia. *Neurologia* 2004;19:331-3.
- Gordon DF. Reisolation of *Staphylococcus salivarius* from the human oral cavity. *J Bacteriol* 1967;94:1281-6.
- Yamakami I, Uchino Y, Kobayashi E, Yamaura A. Computed tomography evaluation of air cells in the petrous bone – Relationship with postoperative cerebrospinal fluid rhinorrhea. *Neurol Med Chir (Tokyo)* 2003;43:334-8.
- Aydin K, Terzibasoglu E, Sencer S, Sencer A, Suoglu Y, Karasu A, et al. Localization of cerebrospinal fluid leaks by gadolinium-enhanced magnetic resonance cisternography: A 5-year single-center experience. *Neurosurgery* 2008;62:584-9.
- Venable GT, Roberts ML, Lee RP, Michael LM. Primary Dural Closure for Retrosigmoid Approaches. *J Neurol Surg B* 2018; 79:330–334.
- Montgomery WW. Translabyrinthine resection of the small acoustic neuroma. *Arch Otolaryngol* 1969;89:319-25.
- Jackler RK. Atlas of Neurotology and Skull Base Surgery. Chicago: Mosby-Year Book; 1996.
- Falcioni M, Mulder JJ, Taibah A, De Donato G, Sanna M. No cerebrospinal fluid leaks in translabyrinthine vestibular schwannoma removal: Reappraisal of 200 consecutive patients. *Am J Otol* 1999;20:660-6.
- Wiet RJ, Mamikoglu B, Hoistad D, Battista R. A technique to prevent cerebrospinal fluid leakage after translabyrinthine approach. *Laryngoscope* 2000;110:1234-6.