

Posttraumatic Isolated Intraventricular Hemorrhage a Rare Entity: Case Series

Abstract

Background: Traumatic Intraventricular hemorrhage is commonly associated with other lesions like intracerebral contusions, subdural hemorrhage and subarachnoid hemorrhage. Isolated post-traumatic intraventricular hemorrhage is uncommon. It is mostly seen in the pediatric population and rarely seen in adults. **Aims:** To analyze the Demographics, mode of Injuries and outcome in injuries causing isolated post traumatic intraventricular hemorrhage which is a rare entity. **Materials and Methods:** This is a Retrospective analytic study of six cases, conducted at our Hospital in a span of eight years [2010-2018]. **Results:** Mean age of presentation is 36 years and all were males. The most common clinical presentation included loss of consciousness followed by vomiting and ENT bleed. Four cases presented with severe head injury and two with mild head injury as per Glasgow coma scale score. Mode of injury was acceleration and deceleration in all the cases. NCCT and CT Angiogram brain were done in all the cases which revealed isolated intraventricular hemorrhage without any vascular or tumoral pathology. All the patients were managed conservatively. **Conclusion:** The outcome was equivocal (3 patients had a bad outcome and 3 good outcomes) in our study.

Keywords: Hemorrhage, intraventricular, isolated, traumatic

**Karla Ravi,
Musali Siddhartha
Reddy,
Prakash Rao
Gollapudi,
Imran Mohammed,
Srikrishnaditya
Manne,
Hemant Kumar
Beniwal**

*Department of Neurosurgery,
Gandhi Medical College
and Hospital, Secunderabad,
Telangana, India*

Introduction

Isolated intraventricular hemorrhage ensuing a traumatic incident is a rare entity. Its incidence following a nonpenetrating head injury is 0.4%–4%. It is commonly associated with other lesions such as intracerebral contusions, subdural hemorrhage, extradural hemorrhage, and subarachnoid hemorrhages and is commonly observed in a pediatric population but rarely in an adult population. The outcome is poor in isolated intraventricular hemorrhages. Herein, we report six cases of isolated intraventricular hemorrhage following nonpenetrating head injuries.

Methods

We perform a retrospective analysis of all the cases of head injury which presented to the department of neurosurgery at our hospital between 2010 and 2018. The records were analyzed for clinical presentation, age groups of presentation, mode of injury, Glasgow Coma Scale score at the time of presentation, mode of injury, radiological findings, and Glasgow Coma outcome score. Radiological findings were

assessed using computed tomography (CT) of the brain and CT angiogram of the brain. The outcome was assessed on the basis of the Glasgow outcome score at the time of discharge.

Case Reports

We present six cases of isolated intraventricular hemorrhages in a span of 8 years (2010–2018) with their relevant clinical history, plain CT, and CT brain angiography findings. Patients and their attendants have given their consent for the case report being published.

Case 1

A 38-year-old male patient alleged to have sustained injuries due to falling from height brought to the emergency department by relatives with complaints of loss of consciousness since the time of injury associated with vomiting, ear bleed and two episodes of seizures. No history of significant medical and surgical illness in the past. The patient was chronic alcoholic and smoker. On examination, the patient was in a state of the unconscious with a Glasgow Coma Scale score of E1V1M3 associated with weakness of right upper and

Address for correspondence:

*Dr. Musali Siddhartha Reddy,
Department of Neurosurgery,
Gandhi Medical College and
Hospital, Padmarao Nagar,
Secunderabad - 500 003,
Telangana, India.
E-mail: siddharthareddy123@
gmail.com*

Access this article online

Website: www.asianjns.org

DOI: 10.4103/ajns.AJNS_171_18

Quick Response Code:



How to cite this article: Ravi K, Reddy MS, Gollapudi PR, Mohammed I, Manne S, Beniwal HK. Posttraumatic isolated intraventricular hemorrhage a rare entity: Case series. Asian J Neurosurg 2019;14:162-5.

This is an open access journal, and articles are distributed under the terms of the Creative Commons Attribution-NonCommercial-ShareAlike 4.0 License, which allows others to remix, tweak, and build upon the work non-commercially, as long as appropriate credit is given and the new creations are licensed under the identical terms.

For reprints contact: reprints@medknow.com

lower limb. CT scan of the brain was done which revealed an isolated intraventricular hemorrhage in the right lateral ventricle and temporal bone fracture. CT angiogram of the brain was done to rule out any vascular pathology which revealed no abnormality. The patient was shifted to the neurointensive care unit where he was put under observation under cover of antiepileptics. The patient regained consciousness after 4 days and was followed up with repeated scans which revealed no evidence of hydrocephalus. The patient recovered and was discharged.

Case 2

A 65-year-old male patient alleged to have sustained injuries due to hitting by a four-wheeler while crossing a road. He was brought to the emergency department by relatives with complaints of loss of consciousness and nasal bleed. The patient was a nonhypertensive and nondiabetic. On examination, the patient was drowsy with a Glasgow Coma Scale Score of E2V2M3 without any focal deficits. CT of the brain revealed isolated intraventricular hemorrhage and temporal bone fracture. CT Angiogram of the brain was done which revealed no vascular abnormality. The patient was intubated, shifted to neurointensive care, and kept under the cover of antiepileptics for observation. The patient succumbed after 9 days.

Case 3

A 40-year-old male patient alleged to have sustained injuries due to falling from a two-wheeler was brought to the emergency department by relatives with a history of loss of consciousness since the time of injury and associated multiple limb injuries. No history of seizures, ear, and nasal bleed. The patient was a nonhypertensive and nondiabetic, and he also was a chronic alcoholic and smoker. On examination, the patient was hypotensive and unconscious with a Glasgow Coma Scale score of E1V1M4. After intubation and resuscitation, CT scan of the brain followed by a CT angiogram was done which revealed an isolated intraventricular hemorrhage without any vascular pathology. The patient shifted to the intensive care after adequate resuscitation and put on a ventilator. He was then treated under the cover of antibiotics and antiepileptics. In spite of adequate treatment, the patient succumbed after 10 days.

Case 4

A 3-year-old child was brought to the emergency department with complaints of fall from a height with complaints of loss of consciousness, vomiting, and nasal bleed. On examination, the child was drowsy with a Glasgow Coma Scale score of E4V4M6 without any focal deficits. No evidence of any bony injuries. CT scan of the brain was done which revealed intraventricular hemorrhage and nasal bone fracture. CT Angiogram of the brain was done which showed no abnormality in the vasculature. The patient was put on antiepileptics, and he recovered in

4 days and was discharged. The follow-up was uneventful with a regression of intraventricular hemorrhage on repeat serial scans.

Case 5

A 30-year-old male patient alleged to have sustained head injuries due to fall from a two-wheeler was brought to the emergency department with complaints of loss of consciousness for a few minutes since the time of injury. No history of vomiting and ear bleed. No history of medical or surgical illness in the past. The patient is a known alcoholic and smoker. On examination, the patient was confused with a Glasgow Coma Scale score of E4V4M6 without any focal deficits. CT scan of the brain revealed intraventricular hemorrhage without any vascular abnormality on CT angiogram. The patient was put on antiepileptics and observed. The patient was discharged after 6 days. The follow-up was uneventful with a decrease in the intraventricular hemorrhage on serial CT scans.

Case 6

A 40-year-old male alleged to have sustained injuries in a road traffic accident, where he was hit by a four-wheeler while walking on the road in a drunken state. He had a history of loss of consciousness since then, with three episodes of vomiting and bleeding from the right ear. On examination, he was unconscious with a Glasgow Coma Scale score of E1V1M3, pupils were mitotic, sluggishly reacting to light bilaterally. No history of seizures or neurological deficits. Patient blood pressure was 80/60 mmHg and pulse rate of 110 beats/min. Palpation of the abdomen revealed tenderness and guarding in the left hypochondrium. Limbs examinations revealed bilateral femur fractures. The patient was intubated, resuscitated, and stabilized. CT of the brain and abdomen were done which revealed isolated intraventricular hemorrhages in both lateral, third and fourth ventricles associated with cisternal and tentorial bleed without hydrocephalus and a right temporal bone fracture, [Figure 1] along with a grade three splenic laceration and mild hemoperitoneum. CT angiogram of the brain was performed to rule out any vascular pathology. There was no vascular and tumoral pathology [Figure 2]. External ventricular drain was put and then shifted to neurointensive care. The splenic injury

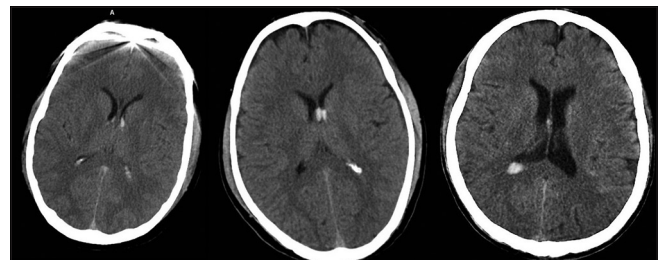


Figure 1: Hyperdense intraventricular hemorrhage seen in both the lateral ventricles with no apparent brain parenchymal changes in various computed tomography images

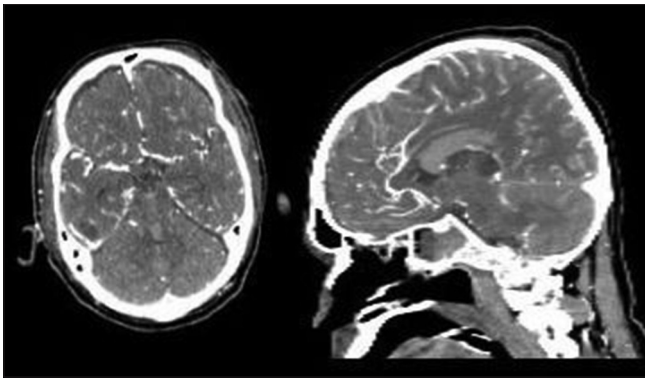


Figure 2: Computed tomography angiogram of brain showing normal vasculature

was managed conservatively with strict monitoring of vitals. In spite of good resuscitation, the patient succumbed on day two.

Results

In the present study, intraventricular hemorrhage was most commonly observed in the age groups of 30–40 years with a mean age of 36 years.

All the cases in our study were males. Mode of injury was road traffic accidents in three cases and fall from height in the other three. On admission, Glasgow Coma Scale score varied from 13 to 15 in two cases and 3–8 in four patients.

The most common clinical presentation at the time of presentation was a loss of consciousness in all the six patients, vomiting was seen in three patients and ear-nose-throat bleeds seen in the four patients. All the patients underwent noncontrast CT of the brain and CT Angiogram to rule out vascular pathology and tumor pathology. All the patients showed isolated intraventricular hemorrhages without any vascular and tumor pathology.

The outcome of the patients with isolated intraventricular hemorrhage is equivocal in the present study, wherein three patients have succumbed, and other three have recovered.

Discussion

Isolated intraventricular hemorrhage ensuing a traumatic event is extremely rare with a prevalence of 0.4%–4% in all head traumas undergoing a CT scan.^[1] Intraventricular bleed may occur when a severe force is applied to the head.

Traumatic intraventricular hemorrhages are usually associated with other lesions such as intracerebral contusions, subdural hemorrhages, extradural hemorrhages, and subarachnoid hemorrhage. Other causes of intraventricular hemorrhages are rupture of intracranial aneurysms or vascular malformations, systemic bleeding tendencies, hypertensive intracerebral bleed extending into the ventricles and neonatal germinal matrix bleed.

In the absence of other associated intracerebral bleeds, intraventricular bleed is caused by tearing of subependymal veins in the septum pellucidum, fornix, or the choroid plexus.^[2,3]

Due to deficient fibrinolysis and hemolysis of the cerebrospinal fluid, spontaneous resolution of intraventricular hemorrhage is slow. Various treatment modalities of intraventricular hemorrhage include placement of external ventricular drain and administration of fibrinolytic into the ventricles.

The outcome is poor in intraventricular hemorrhage. Cause of poor outcome is not clearly known; it may be due to the presence of blood in the ventricles, hydrocephalus development or due to increased intracranial pressure.^[4] Lee *et al.* in their study found a good outcome for isolated intraventricular hemorrhage.^[5] Is *et al.* reported a good outcome in a pediatric patient with an isolated intraventricular hemorrhage.^[6]

This case series in contrast to other studies report an equivocal outcome.

Conclusion

Traumatic isolated intraventricular hemorrhage is an extremely rare variant occurring more commonly in males and the age groups of 30–40 years, in acceleration and deceleration injuries with an equivocal outcome hence being reported.

Consent

Patient's attendants have given consent for the publication and also consent has been obtained from the institution.

Declaration of patient consent

The authors certify that they have obtained all appropriate patient consent forms. In the form, the patients have given their consent for their images and other clinical information to be reported in the journal. The patient understands that name and initials will not be published and due efforts will be made to conceal identity, but anonymity cannot be guaranteed.

Financial support and sponsorship

Nil.

Conflicts of interest

There are no conflicts of interest.

References

1. Atzema C, Mower WR, Hoffman JR, Holmes JF, Killian AJ, Wolfson AB, *et al.* Prevalence and prognosis of traumatic intraventricular hemorrhage in patients with blunt head trauma. *J Trauma* 2006;60:1010-7.
2. Karavelis A, Sirmos C. Primary post-traumatic intraventricular hemorrhage. *J Neurosurg Sci* 1995;39:253-6.

3. Hashimoto T, Nakamura N, Ke R, Ra F. Traumatic intraventricular hemorrhage in severe head injury. No Shinkei Geka 1992;20:209-15.
4. LeRoux PD, Haglund MM, Newell DW, Grady MS, Winn HR. Intraventricular hemorrhage in blunt head trauma: An analysis of 43 cases. Neurosurgery 1992;31:678-84.
5. Lee JP, Lui TN, Chang CN. Acute post-traumatic intraventricular hemorrhage analysis of 25 patients with emphasis on final outcome. Acta Neurol Scand 1991;84:85-90
6. Is M, Gezen F, Akgul M, Dosoglu M. Traumatic intraventricular hemorrhage with a good prognosis. Turk Neurosurg 2011;21:107-9.