

Intramedullary Spinal Cord Lipoma Mimicking a Late Subacute Hematoma

Abstract

Spinal cord lipomas are rare and benign tumors which may cause progressive neurological deficits due to their local expansion. We present the case of a 59-year-old male patient with severe lumbosacral pain and slowly progressive paresis of the right leg, misdiagnosed with degenerative spine disease. Repeated magnetic resonance (MR) T1-weighted images of the thoracic spine suggested a subacute intramedullary hematoma. Due to progression of the neurological deficit, the patient was referred to a neurosurgeon, who indicated surgical evacuation of the hematoma. The intraoperative finding revealed an intramedullary spinal cord lipoma, which was later confirmed by histological analysis. Since subacute intramedullary hematomas and intramedullary spinal cord lipomas present with similar clinical and radiological features, diffusion-weighted MR imaging should be used to distinguish these entities.

Keywords: Diffusion-weighted imaging, intramedullary spinal cord lipoma, subacute intramedullary hematoma

Introduction

Spinal cord tumors represent a very rare pathological entity. Their incidence rises with age.^[1] Considering their origin, spinal cord tumors can be divided into primary and secondary ones. While primary tumors originate from the spinal cord and surrounding tissues, secondary tumors are hematogenous or lymphatic metastases that originate from different parts of the body. According to their anatomical relationship with the dura mater, spinal cord tumors can be classified as extradural or intradural. Intradural tumors can be further subclassified as the more common extramedullary or the less common intramedullary tumors, the latter of which are mostly located in the thoracic spine.^[2]

Spinal cord lipomas are benign tumors composed of fat cells. They can be divided into three groups: lipomas of the conus medullaris, lipomas of the terminal filum, and subpial lipomas.^[3] Subpial lipomas are very rare, completely intramedullary lesions.^[3] The incidence of intradural intramedullary nondysraphic spinal cord lipomas is very low, amounting to <1% of all spinal cord tumors.^[4-8] Intradural intramedullary spinal cord lipomas are more often associated with dysraphism.^[2,9-12]

The most common location of intradural lipomas is the dorsal part of the cervical or thoracic spine.^[10,13]

There are several theories on the development of intramedullary lipomas. The embryological theory states that lipomas are the result of mesodermal invasion of the neural groove due to an early disjunction of the neural ectoderm from the rest of the ectodermal layer.^[2,8] Histologically, these tumors consist of fat and connective tissue abundant in blood vessels.^[6,8]

Symptoms and different neurological deficits caused by intradural intramedullary lipomas result from the mass effect on the spinal cord.^[2,10,14] In addition to patient history and neurological examination, MRI is crucial for the diagnosis of these tumors. However, the final diagnosis is established only after histopathological examination of the tissue.^[15]

Surgical treatment is the treatment of choice in the case of intramedullary spinal cord lipomas, although complete tumor resection is often not possible.^[16] The long-term prognosis is satisfactory.^[2,5]

Case Report

A 59-year-old man initially presented with mild back pain located in the projection of the lumbosacral (LS) spine,

**Ivan Pasalic,
Klara Brgic,
Jakob Nemir,
Danijela Kolenc¹,
Niko Njiric,
Goran Mrak**

Departments of Neurosurgery and ¹Neuropathology, University Hospital Center Zagreb, University of Zagreb, School of Medicine, Zagreb, Croatia

Address for correspondence:

*Dr. Ivan Pasalic,
Department of Neurosurgery,
University Hospital Center
Zagreb, Kispaticeva 12,
10000, Zagreb, Croatia.
E-mail: ivan.pasalic@yahoo.
com*

Access this article online

Website: www.asianjns.org

DOI: 10.4103/ajns.AJNS_112_18

Quick Response Code:



How to cite this article: Pasalic I, Brgic K, Nemir J, Kolenc D, Njiric N, Mrak G. Intramedullary spinal cord lipoma mimicking a late subacute hematoma. Asian J Neurosurg 2018;13:1282-4.

This is an open access journal, and articles are distributed under the terms of the Creative Commons Attribution-NonCommercial-ShareAlike 4.0 License, which allows others to remix, tweak, and build upon the work non-commercially, as long as appropriate credit is given and the new creations are licensed under the identical terms.

For reprints contact: reprints@medknow.com

radiating down the right leg. The pain had first occurred a year before the initial hospitalization. The first magnetic resonance imaging (MRI) of the LS spine showed moderate degenerative changes with mild disc protrusions that did not indicate neurosurgical treatment, but required physiotherapy. However, 3 months later, the patient developed paresthasias in the right leg and lower abdomen. He also showed signs of motor weakness in the right leg, forcing him to use a crutch when walking. Another cycle of physiotherapy was recommended, resulting in no signs of improvement. Repeated MRI of the LS spine showed the same findings as the first scan. Finally, the patient presented with paresis, Gross Motor Function Classification System (GMFCS) IV, increased muscle tone, hypotrophic muscles, and vivid muscle reflexes in the right leg (GMFCS IV), as well as hypoesthesia and hypoalgesia along the T8 dermatome.

MRI of the thoracic spine was performed, showing an oval intramedullary lesion located at the T4/5 intervertebral level [Figure 1]. The lesion did not show any change at 1-month follow-up MRI. Due to the hyperintensity seen on the T1-weighted sequence, the lesion was interpreted as a subacute intramedullary hematoma. Gadolinium contrast was not used. No signs of arteriovenous malformations or arteriovenous fistulas were found on these MRI scans.

Due to progression of neurological symptoms, a neurosurgical intervention was indicated. The procedure was done under general anesthesia, and the patient was placed in the prone position. After accessing and removing the T4 and T5 laminae, the dura was exposed and intraoperative ultrasound was used to verify the location of the lesion. Using microsurgical technique, a linear incision of the dura and midline myelotomy were done. The intramedullary process was exposed and macroscopic evaluation revealed it to be a soft yellowish tumor [Figure 2a] which did not resemble a hematoma, but showed characteristics typical of a lipoma. Samples for histopathological examination were obtained, and maximal reduction of the process was performed using the cavitron ultrasonic surgical aspirator. During the procedure, the patient's somatosensory-evoked potentials (SSEPs) and motor-evoked potentials (MEPs) were monitored. The SSEPs did not show pathological changes throughout the procedure, whereas MEPs were absent from the onset and could not be monitored.

Histopathological examination revealed lobes of mature fat cells [Figure 2b], thus confirming the diagnosis of intramedullary spinal cord lipoma. Postoperatively, the patient's motor function temporarily deteriorated and a repeat MRI of the thoracic spine was done [Figure 3]. A significant reduction in size of the intramedullary lipoma was revealed and postoperative complications were excluded. After physiotherapy, the patient's motor function recovered.

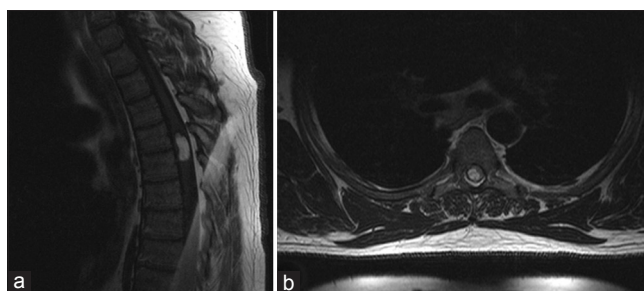


Figure 1: Preoperative T1-weighted magnetic resonance images showing T4/5 intramedullary spinal cord lipoma in the sagittal (a) and transverse planes (b)

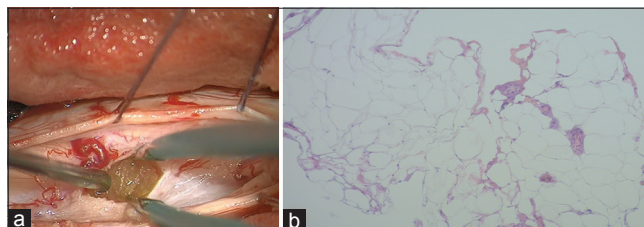


Figure 2: Intraoperative macroscopic finding (a) and histological analysis showing hematoxylin and eosin-stained fat cells specific for lipomas (x100) (b)

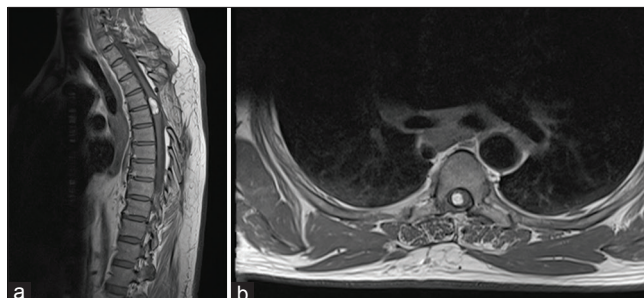


Figure 3: Postoperative T1-weighted gadolinium-enhanced magnetic resonance images showing significantly reduced size of T4/5 intramedullary spinal cord lipoma in the sagittal (a) and transverse planes (b)

Discussion

Differentiating intramedullary nondysraphic spinal cord lipomas is a difficult task due to their rarity. Intramedullary lipomas are slow-growing tumors that are asymptomatic for a long period of time. However, when the symptoms appear, they usually progress rapidly and cause significant neurological deterioration.^[2,13,17] This applied to our patient as well. He was asymptomatic for decades, but when the symptoms occurred, he rapidly developed severe weakness of the right leg.

It is important to note that intramedullary spinal cord lipomas are often located in the upper parts of the spine,^[10,13] as was the case with our patient, in the projections of the T4 and T5 vertebrae.

MRI features of these lesions are hyperintensity on T1- and hypointensity on T2-weighted sequences.^[8,11,15,18] These characteristics are typical of both intramedullary spinal

cord lipomas and intramedullary hematomas, but the latter are much more frequent.^[19] In order to distinguish these two entities, diffusion-weighted images (DWIs) on MRI should be used. In the DWIs, lipomas are hypointense, while subacute hemorrhages are hyperintense.^[20,21] Although DWIs and their macroscopic appearance can differentiate these two lesions, histopathological analysis should be used to establish the final diagnosis.

Due to its firm attachment to the spinal cord, complete removal of an intramedullary lipoma without causing significant neurological damage is difficult. Even after partial reduction, postoperative temporary neurological deficits can be expected,^[2,11,16,17] which was the case with our patient.

Conclusion

Intramedullary nondysraphic lipomas are rare tumors of the spinal cord which are difficult to differentiate from subacute intramedullary hemorrhage. It is crucial to take them into consideration in the differential diagnosis of all patients with progressive neurological deterioration and hyperintense spinal cord lesions in T1 sequences. To differentiate spinal cord lipomas from subacute hemorrhage, DWI sequences are mandatory.

Declaration of patient consent

The authors certify that they have obtained all appropriate patient consent forms. In the form the patient(s) has/have given his/her/their consent for his/her/their images and other clinical information to be reported in the journal. The patients understand that their names and initials will not be published and due efforts will be made to conceal their identity, but anonymity cannot be guaranteed.

Acknowledgments

We would like to thank Aleksandra Žmegač Horvat, University of Zagreb School of Medicine, for proofreading of the text.

Financial support and sponsorship

Nil.

Conflicts of interest

There are no conflicts of interest.

References

- Schellinger KA, Propp JM, Villano JL, McCarthy BJ. Descriptive epidemiology of primary spinal cord tumors. *J Neurooncol* 2008;87:173-9.
- Samartzis D, Gillis CC, Shih P, O'Toole JE, Fessler RG.

- Intramedullary spinal cord tumors: Part I-epidemiology, pathophysiology, and diagnosis. *Global Spine J* 2015;5:425-35.
- Finn MA, Walker ML. Spinal lipomas: Clinical spectrum, embryology, and treatment. *Neurosurg Focus* 2007;23:E10.
- de Araújo LP, Dezena RA, da Silva MN, Etchebehere RM, Dornelas AG. Thoraco-lumbar nondysraphic intramedullary spinal cord lipoma with an unusual aspect on MRI: Case report and review. *J Bras Neurocirurgia* 2012;23:251-5.
- Srinivasan US, Raghunathan N, Radhi L. Long term outcome of non-dysraphic intramedullary spinal cord lipomas in adults: Case series and review. *Asian Spine J* 2014;8:476-83.
- Ramzan A, Khursheed N, Rumana M, Javeed Z. Giant spinal intramedullary lipoma with posterior fossa extension. *Pediatr Neurosurg* 2010;46:406-7.
- Sanli AM, Türkoğlu E, Kahveci R, Sekerci Z. Intradural lipoma of the cervicothoracic spinal cord with intracranial extension. *Childs Nerv Syst* 2010;26:847-52.
- Patwardhan V, Patanakar T, Patkar D, Armao D, Mukherji SK. MR imaging findings of intramedullary lipomas. *AJR Am J Roentgenol* 2000;174:1792-3.
- Singh A, Gupta V, Singh H, Chand K. Nondysraphic intradural spinal lipoma. *J Pediatr Neurosci* 2009;4:55-6.
- Wilson PE, Oleszek JL, Clayton GH. Pediatric spinal cord tumors and masses. *J Spinal Cord Med* 2007;30 Suppl 1:S15-20.
- Ahmed O, Zhang S, Thakur JD, Nanda A. Nondysraphic intramedullary cervical cord lipoma with exophytic component: Case report. *J Neurol Surg Rep* 2015;76:e87-90.
- Muthusubramanian V, Pande A, Vasudevan MC, Ramamurthi R. Concomitant cervical and lumbar intradural intramedullary lipoma. *Surg Neurol* 2008;69:314-7.
- Lee M, Rezai AR, Abbott R, Coelho DH, Epstein FJ. Intramedullary spinal cord lipomas. *J Neurosurg* 1995;82:394-400.
- Blount JP, Elton S. Spinal lipomas. *Neurosurg Focus* 2001;10:e3.
- Bhatoe HS, Singh P, Chaturvedi A, Sahai K, Dutta V, Sahoo PK, et al. Nondysraphic intramedullary spinal cord lipomas: A review. *Neurosurg Focus* 2005;18:ECP1.
- Suresh B, Anasuyamma K, Uma M, Madhu D, Ramanappa M. Intradural lipoma without spinal dysraphism with spinal cord involvement. *Internet J Radiol* 2007;8:5. Available from: <http://www.ispub.com/IJRA/8/2/5016>. [Last accessed on 2018 Feb 25].
- Kim CH, Wang KC, Kim SK, Chung YN, Choi YL, Chi JG, et al. Spinal intramedullary lipoma: Report of three cases. *Spinal Cord* 2003;41:310-5.
- Goyal M, Mishra NK, Gaikwad S, Jayasundar R. Cervical intramedullary lipoma with unusual MRI features: Case report. *Neuroradiology* 1996;38 Suppl 1:S117-9.
- Bozzo A, Marcoux J, Radhakrishna M, Pelletier J, Goulet B. The role of magnetic resonance imaging in the management of acute spinal cord injury. *J Neurotrauma* 2011;28:1401-11.
- Peter AB, Ramli N, Rahmat K, Rozalli FI, Azlan CA. Mimics and diagnostic pitfalls of intracranial lesions in conventional MRI: Clues on advanced MRI. *Neurol Asia* 2015;20:161-5.
- Hoch MJ, Rispoli J, Bruno M, Wauchope M, Lui YW, Shepherd TM, et al. Clinical utility for diffusion MRI sequence in emergency and inpatient spine protocols. *Clin Imaging* 2017;45:37-50.