

# Management of Recurrent Aneurysms after Endovascular Coiling: A Fujita Experience

## Abstract

**Introduction:** Microsurgical clipping and Endovascular coiling (EC) are both effective alternatives in the management of intracranial aneurysms. EC has been shown to be associated with the risk of recurrent aneurysm (RA) growth. Considering the minimally invasive nature of this procedure, the management of intracranial aneurysms has been skewed toward EC, especially in the developed world. In this scenario, there has been an upsurge of RAs after EC. Since the optimal management of these RAs has not been defined, they pose a unique challenge to the treating surgeons. **Aims and Objectives:** The aim of this study is to elucidate the optimal management of RAs after EC. **Materials and Methods:** Medical records of all patients who underwent surgery for RAs were reviewed from the period January 2014 to March 2019. The demographic and angiographic patterns of the patients and operative techniques and complications were studied. The outcome was dichotomized into good and bad depending on the Glasgow outcome scale (GOS). **Results:** There were four cases of RAs operated in our institution between the above-mentioned period. There were varied differences between the initial coiling and time to recurrences. All four patients were operated under neuromonitoring. Three underwent clipping and one patient underwent clipping with bypass. All four patients had good outcome with a GOS of 5/5. **Conclusion:** Operations for RAs constitute many technical challenges and require a lot of expertise. Such surgeries are recommended in high-volume centers, with sufficient experience in both clipping and cerebral bypass.

**Keywords:** Aneurysms, endovascular coiling, management, recurrence

## Introduction

Clipping and endovascular coiling (EC) are both viable modalities of management in intracranial aneurysms. The modern world has witnessed a recent surge in advancements of EC. The balance between the two has been shifted more in favor of EC in the recent times, especially in the developed countries. The complete obliteration rates of intracranial aneurysms in the EC group has been showed to be inferior to the clipping group in the previous studies.<sup>[1]</sup> The International Subarachnoid Aneurysm Trial reported that 26% of angiograms showed neck remnants and 8% showed refilling after coiling compared with 12% and 6%, respectively, in the clipping group.<sup>[2,3]</sup> The Cerebral Aneurysm Rerupture After Treatment study revealed annual retreatment rates of coiled and clipped aneurysms of 13.3% and 2.6%, respectively, during the 1<sup>st</sup> year after

intervention.<sup>[4]</sup> The study also emphasized that rupture after residual aneurysms were directly related to the degree of neck occlusion. The annual risk of rupture for completely occluded aneurysms were 1.1%, whereas it was 5.9% for aneurysms neck occlusion of 70%–90%. These residual aneurysms have potency to regrowth and subsequent rerupture. As a sequelae to the upsurge of EC in the developed world, there has been an increase in the incidence of recurrent aneurysms (RAs). These RAs pose a unique challenge to the treating surgeons as opposed to the primary aneurysms because of the unfavorable configuration imparted by the initial coiling. In this retrospective study from our institution, we discuss the demography of patients, angiographic patterns, treatment strategies, and the outcome of RA.

## Materials and Methods

A retrospective analysis of case records of the Bantane hospital, Fujita Health University, from the period 2014 to

Raja K. Kutty,  
Ambuj Kumar<sup>1</sup>,  
Yasuhiro Yamada<sup>2</sup>,  
Riki Tanaka<sup>2</sup>,  
Satish Kannan<sup>3</sup>,  
Vigneshwar  
Ravisankar<sup>3</sup>,  
Aaron Musara<sup>4</sup>,  
Kyosuke Miyatani<sup>2</sup>,  
Saeko  
Higashiguchi<sup>2</sup>,  
Katsumi Takizawa<sup>5</sup>,  
Tsukasa Kawase<sup>2</sup>,  
Yoko Kato<sup>2</sup>

Department of Neurosurgery, Government Medical College, Thiruvananthapuram, Kerala, <sup>1</sup>Department of Neurosurgery, NSCB Medical College, Jabalpur, Madhya Pradesh, <sup>2</sup>Department of Neurosurgery, MGM Hospital, Chennai, Tamil Nadu, India, <sup>4</sup>Department of Neurosurgery, College of Health Sciences, Harare, Zimbabwe, <sup>5</sup>Department of Neurosurgery, Asahikawa Redcross Hospital, Hokkaido, <sup>3</sup>Department of Neurosurgery, Bantane Hospital, Fujita Health University, Nagoya, Japan

**Address for correspondence:**  
Dr. Raja K. Kutty,  
Department of Neurosurgery,  
Government Medical College,  
Thiruvananthapuram, Kerala,  
India.  
E-mail: drrajakutty@gmail.com

### Access this article online

**Website:** www.asianjns.org

**DOI:** 10.4103/ajns.AJNS\_105\_19

### Quick Response Code:



**How to cite this article:** Kutty RK, Kumar A, Yamada Y, Tanaka R, Kannan S, Ravisankar V, et al. Management of recurrent aneurysms after endovascular coiling: A Fujita experience. Asian J Neurosurg 2019;14:1151-6.

This is an open access journal, and articles are distributed under the terms of the Creative Commons Attribution-NonCommercial-ShareAlike 4.0 License, which allows others to remix, tweak, and build upon the work non-commercially, as long as appropriate credit is given and the new creations are licensed under the identical terms.

For reprints contact: reprints@medknow.com

2019 was done. Patients' demography and aneurysm characteristics were noted. The patient demographics included age, sex, and comorbidities. Whereas, the aneurysm characteristics studied were location of aneurysm, size at the time of clipping, number of endovascular procedures before clipping, surgical indications, techniques, and outcome of the procedure.

### Outcome

The outcome was dichotomized into good and bad outcome depending on the Glasgow Outcome Scale (GOS). Good outcome was classified according to GOS 4 and 5, whereas bad outcome was classified in patients with GOS 1, 2, and 3. Any complications occurring during the follow-up time was recorded and graded into minor and major complication. Minor complications were defined as any temporary neurologic deficit not needing intervention, any cranial nerve palsy, and wound infections. Major complications included any intervention in the form of surgery or placements of any shunt and any complication, resulting in permanent disabling neurological deficit or death.

### Statistical analysis

All recorded continuous variables will be expressed as means and qualitative variables will be expressed as proportions.

### Results

There were three cases of RAs after EC in our institution in the above-mentioned period. One patient with giant vertebral aneurysm who underwent stent-assisted coiling outside of our institution, presented to us with hemiparesis due to mass effect on the brainstem and hence was reoperated here. There were three males and one female. The mean age of the patients was  $52.2 \pm 3.4$  years. The mean size of the RAs was  $17 \pm 5.1$  mm, which included two giant aneurysms as well. Two patients underwent coiling more than once. Among them, one patient had stent-assisted coiling for a giant vertebral artery aneurysm. The time to recurrence between coiling and final clipping was between 2 and 3 years. All patients underwent direct clipping of aneurysm. In three patients, the aneurysm was amenable to direct clipping without manipulation of the coils, whereas in

one patient, it was necessary to remove the coils from within the aneurysm to facilitate clipping. This patient had a giant vertebral artery aneurysm, for which he underwent proximal and distal trapping along with the occipital artery to posterior inferior cerebellar artery bypass. Summary of data has been described in Table 1.

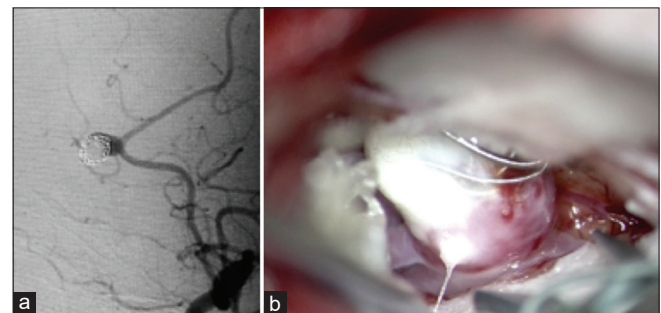
### Illustrative cases

#### Case no 1

A 58-year-old male was detected to have a distal anterior cerebral artery (DACA) aneurysm in 2008, for which he had undergone coiling. After 1 year, recurrence of the aneurysm was noted and he again underwent coiling in 2009. In 2015, on routine follow-up angiography, there was Raymond–Roy occlusion classification (RROC) Gr2 recurrence [Figure 1a]. There was coil compaction on angiography. He underwent bifrontal craniotomy and interhemispheric approach for the clipping of aneurysm. Intraoperatively, the coils were extruding out of the aneurysmal sac [Figure 1b]. No coil extraction was attempted. The neck was well defined due to coil compaction. The aneurysm was clipped effectively. The digital subtraction angiography (DSA) and intraoperative photograph are depicted in Figure 1.

#### Case no 2

A 44-year-old female underwent coiling for the right internal carotid artery posterior communicating artery aneurysm in



**Figure 1:** (a) Digital subtraction angiography showing filling of the neck of the aneurysm sac with contrast due to coil compaction. (b) Intraoperative photograph of the coiled aneurysm. Note the coils are seen embedded in the wall of the aneurysm. Some parts of the coil are seen to be extruded from the sac

**Table 1: Patient demographics, aneurysm characteristics, and outcome**

Case number	Age	Sex	Type of aneurysm	Aneurysm size (mm)	Previous treatment	Time to recurrence (years)	RROC	Final treatment	Outcome GOS
1	58	Male	DACA	5	Coiling 2 times	10	3	Clipping	5/5
2	44	Female	IC-Pcom	12	Coiling once	2	3	Clipping	5/5
3	50	Male	VA	25	Coiling once	3	1	Clipping with OA-PICA bypass	5/5
4	60	Male	A1	26	Coiling 3 times	2	2	Clipping with STA-A3 bypass	5/5

DACA – Distal anterior cerebral aneurysm; IC-Pcom – Internal carotid-Posterior communicating artery; RROC – Raymond–Roy occlusion classification; GOS – Glasgow outcome scale; OA – Occipital artery; PICA – Posterior inferior cerebellar artery; STA – Superficial temporal artery; A3 – Anterior cerebral artery third part; VA – Vertebral artery

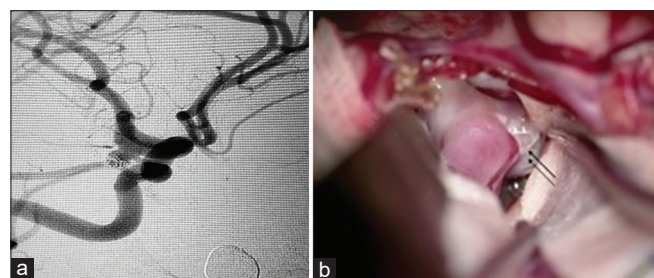
2015. On follow-up angiogram after 2 years, she had RROC Gr 2 recurrence of the aneurysm [Figure 2a]. She underwent right pterional craniotomy and trans-Sylvian approach for the clipping of aneurysm in 2017. Intraoperatively, the coils were seen embedded in the wall of the aneurysmal sac and no attempts were made to remove them [Figure 2b]. The aneurysm was clipped without any residual neck. The DSA and the intraoperative photograph are depicted in Figure 2.

### Case no 3

A 50-year-old male was detected to have a partially thrombosed giant Vertebral artery aneurysm in 2014 [Figure 3a]. He underwent coiling of the aneurysm in the same year. In the follow-up angiogram a year later, it was observed that there was a recurrence of aneurysm and he again underwent stenting and coiling in 2015. In the subsequent year, there was rerecurrence and he underwent coiling in 2016 [Figure 3a]. In 2017, the patient presented with progressive diplopia, left facial weakness along with dysarthria and dizziness. He was investigated with angiogram during which it was detected that the aneurysm showed progressive growth [Figure 3b and c]. There was evidence of mass effect on the brain stem on magnetic resonance imaging. It was decided that the patient be managed with surgery and relieve the mass effect of the growing aneurysm on the brain stem. He underwent suboccipital craniotomy during which the aneurysm was seen in close proximity to the lower cranial nerves and the PICA was seen running along the stalk of the aneurysm from the vertebral artery [Figure 3d and e]. The aneurysm was managed with proximal and distal trapping with aneurysm clips. The aneurysm was opened and the coils were retrieved from within the aneurysm sac [Figure 3f and g]. The stent was left intact within the aneurysm. The excision of the redundant sac was done. This was followed by the occipital artery to posterior inferior cerebellar artery bypass. Postoperatively, the patient did well. The dysarthria had resolved, but the facial nerve palsy recovered only partially.

### Case no 4

A 60-year-old male had undergone treatment with coiling in 2017 for a subarachnoid hemorrhage due to aneurysm rupture. The aneurysm was located at the DACA. In the following

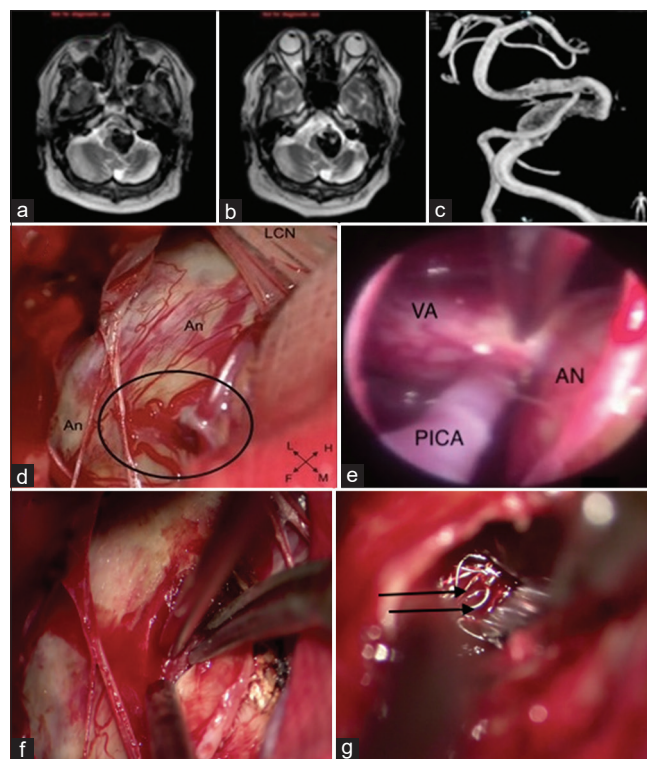


**Figure 2:** (a) Digital subtraction angiography of the patient showing aneurysm in the communicating segment of the internal carotid artery. Note the neck is well visualized with filling of the contrast. (b) Intraoperative photograph showing the aneurysm with coils embedded in the aneurysm sac (short arrows). There is no extrusion of coils

year, he underwent coiling for the same aneurysm twice in interval of 7 months as the aneurysm showed recurrence during follow-up angiogram. After 6 months, a follow-up angiogram was done, and it was noted that the aneurysm showed RROC gr3 recurrence [Figure 4a]. At this juncture, it was decided to treat the aneurysm surgically. In a view to maintain the distal supply to the anterior cerebral artery ipsilateral to the aneurysm, a salvage bypass was initially done with a midline frontal craniotomy whereby a superficial temporal artery graft to A3 was done. This was followed by a pterional craniotomy and the aneurysm clip was applied distal to its origin of the aneurysm on the non-dominant A1. Operative plan is illustrated in Figure 4b. This was done to dampen the flow into the aneurysm sac and induce thrombosis as well as to maintain flow to the perforators of the aneurysm from dominant A1 on the opposite side through the anterior communicating artery. The DACA distal to the aneurysm was perfused by interposition of a superficial temporal artery graft.

## Discussion

EC of aneurysms, though minimally invasive in nature, is not without complications. Literature has shown that



**Figure 3:** (a) Magnetic resonance imaging brain T2-weighted axial image showing giant thrombosed aneurysm with mass effect on the brain stem. (b) Follow-up imaging with the same sequence after 3 years showing growth of the aneurysm with increased mass effect on the brain stem. (c) Digital subtraction angiography depicting the large vertebral artery aneurysm. (d) Intraoperative view of the aneurysm (An - Aneurysm); LCN - Lower cranial nerves. The encircled area demonstrating stalk between the vertebral artery and the aneurysm. (e) The intraoperative field being inspected by an endoscope. VA - Vertebral artery, An - Aneurysm, PICA - Posterior inferior cerebellar artery. (f) The aneurysm being opened intraoperatively. (g) The coils within the aneurysmal sac (black arrows) being removed intraoperatively

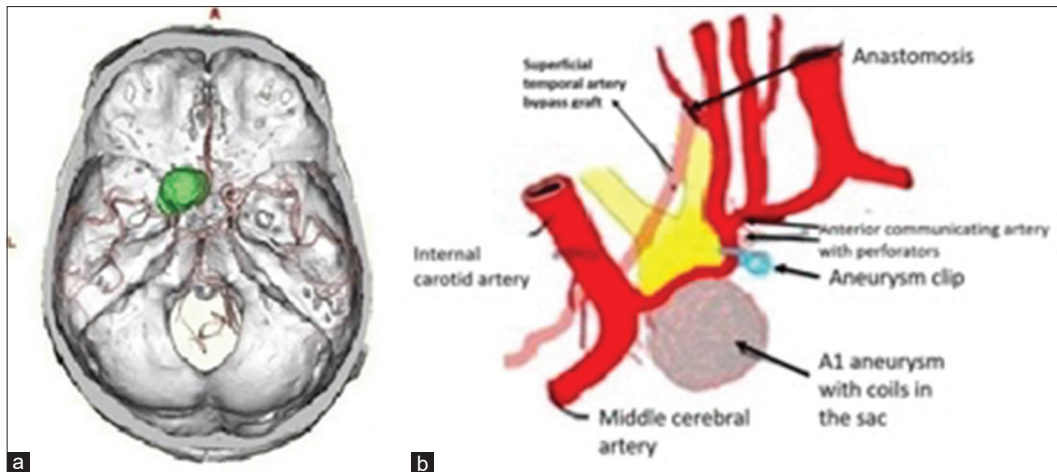


Figure 4: (a) Reconstructed computed tomography angiogram showing left A1 giant aneurysm (green color). (b) Illustrative diagram of the operative plan. The aneurysm was clipped at the A1–A2 junction distal to the aneurysm. The superficial temporal artery was anastomosed to the A3 part of the anterior cerebral artery

**Table 2: A synopsis of major series published cases in the English literature in the last 5 years**

Author	Year	Number of patients with RAs	Recurrence rates (%)	Rehemorrhage rate (%)	Complication	
					Minor (%)	Major (%)
Liu <i>et al.</i> <sup>[20]</sup>	2019	75	5	NA	NA	NA
Yu <i>et al.</i> <sup>[26]</sup>	2018	101	33	7.5	NA	NA
Toyota <i>et al.</i> <sup>[22]</sup>	2018	27	NA	NA	NA	NA
Shtaya <i>et al.</i> <sup>[27]</sup>	2018	39	NA	NA	5.1	5.1
Nisson <i>et al.</i> <sup>[28]</sup>	2018	53	NA	NA	22.6	3.9
Wang <i>et al.</i> <sup>[29]</sup>	2017	21	1.46	NA	NA	NA
Kivelev <i>et al.</i> <sup>[30]</sup>	2016	20	NA	NA	NA	NA
Daou <i>et al.</i> <sup>[31]</sup>	2016	111	40	NA	6.3	8
Owen <i>et al.</i> <sup>[32]</sup>	2015	73	2	14	4	NA
Izumo <i>et al.</i> <sup>[33]</sup>	2015	7	7.7	NA	28	NA
Chen <i>et al.</i> <sup>[1]</sup>	2015	89	13.3	NA	9.1	NA

RAs – Recurrent aneurysms; NA – Not available

approximately 20% of coiled aneurysms are associated with recurrence, of which 10% will undergo additional intervention.<sup>[5,6]</sup> A synopsis of cases available in the literature regarding surgery for recurrent aneurysms follows coiling and outcome in the last five years is summarised in Table 2. Ogilvy *et al.*, analyzed the risk for recanalization of aneurysms and noted that size more than 10 mm, neck size >4 mm, rupture, stent assistance, and posttreatment degree of aneurysm occlusion were significant factors for recanalization of aneurysms following endovascular treatment.<sup>[7]</sup> In the recently published results of 10 years of the BRAT showed that rates of aneurysm obliteration decrease and the rates of retreatment increase over the time in patients who underwent EC.<sup>[8]</sup>

The indications for surgery in patients after EC are: (a) presence of remnants after coiling, (b) recanalization and regrowth of previously coiled aneurysms, (c) mass effect of the coiled aneurysms, and finally (d) migration of the coils.<sup>[9]</sup> In our experience, we had three patients, in

whom there was a recanalization of the aneurysm, whereas, in one (Case no 3), there was true growth of the aneurysm. In this patient, the growing aneurysm was pressing itself against the brain stem. Hence, it was prudent to relieve him of the mass effect on the brain stem.

The recanalization of aneurysms after EC has been classified by various authors. Grunwald *et al.* classified the recanalization patterns into ones with coil mesh change (Type a), neck growth (Type b), and dog ears (Type C1 and C2).<sup>[10]</sup> Widely accepted classification scheme for recanalization after EC was published by Raymond *et al.*<sup>[11]</sup> and mentioned as Raymond-Roy occlusion Classification (RROC). They classified recanalization depending on the angiographic pattern of contrast enhancement into three, viz, total occlusion (RROC1), contrast filling the neck (RROC2), and any contrast into to the aneurysm dome (RROC3). Mascitelli *et al.* further subclassified RROC3 into: (a) any contrast into the interstices of the coils within the aneurysm and (b) contrast enhancement into the wall of aneurysm.<sup>[12]</sup> This was done in view of subanalysis

which showed the risk of recanalization and rerupture to be highest in Group 3B. Kobayashi *et al.* described RAs according to the plane of closure of the clip and the plane of neck of the aneurysm into four types and derived a plan of algorithm for each type.<sup>[13]</sup> The reasons for treating RAs can be due to either coil compaction or true aneurysm regrowth. In this scenario, a second EC is an option in the management with most of the recurrences. With the advances in the endovascular technique, many recurrent aneurysms have been managed effectively with stenting/stent-assisted<sup>[14-16]</sup> coiling as well as pipeline embolization<sup>[17]</sup> devices, but this expertise may not be available in all centers and not all aneurysms are suitable for this type of intervention by virtue of its unfavorable anatomical configuration, namely, wider neck and mass effect. Moreover, stent-assisted coiling has been shown to be associated with more complications<sup>[18]</sup> as well as recurrences<sup>[19,20]</sup> in view of the dual antiplatelets therapy required for long-term patency.<sup>[21]</sup> Hence, many centers opt for clipping in this scenario.

### Aneurysm characteristics that favor effective clipping following endovascular coiling

The difficult part after exposing the RA is to clip it in a configuration that would best maintain the patency of the parent vessel as well as the perforators arising from it. Many times, the surgeon may not be able to position the clips where he intends to as the clip blades may slip into the parent artery due to the mass occupied by the coils within the aneurysm. These factors should be kept in mind and the best possible clip and the plan of clipping which can cater to the given situation should be chosen. Many authors have described the favorable characteristics for clipping following recurrences after EC. Toyota *et al.* stated that RA type 3 (tall remnant neck) and RA type 4 (short remnant neck but distinct demarcation between thrombosed and nonthrombosed part) are the most favored type for selective clipping.<sup>[22]</sup> Alternatively, Waldron *et al.* noted that the ratio of coil width to compaction height was a reliable indicator of clippability. The coil width to height ratio <2.5 are good candidates for clipping, whereas others require additional technical options like bypass.<sup>[23]</sup> Kobayashi *et al.* described in their experience that RAs after EC can be safely clipped without the old clip interfering with the new one in Type 1, 2, and 3b, whereas Type 3a and 4 require more complex procedures such as bypass or endovascular treatments.<sup>[13]</sup>

### Surgical techniques and challenges

The primary challenge in the management of RAs is to dissect the aneurysm in the field of fibrosis induced by the partially or totally extruded coils placed during the endovascular intervention. The accurate placement of clips during surgery is difficult and often involves removal of the coils placed during EC to define the neck. This process has been found to be an adverse factor in the outcome of clipping after EC. The ideal aneurysm characteristics for clipping after coiling are those with narrow neck and coils

not protruding in the parent vessel. Removal of coils from the recanalized aneurysm offers a technical challenge as coils become incorporated into the aneurysm wall as early as 2 weeks after placement, and their removal therefore becomes riskier over time.<sup>[24,25]</sup> In our limited experience, we had only one patient, in whom it was necessary to remove the coils. In this patient (Case no 3), this procedure was inevitable in the process of excision of the growing aneurysm to relieve the mass effect on the brain stem. In view of complex anatomical recurrences, it is essential to have a complex surgical procedure in the form of cerebrovascular bypass. This can be achieved by a *in situ* bypass selecting an appropriate neighboring artery or by inserting an interposition graft. A meticulous surgical plan must be delineated before the commencement of the surgery in such complex configuration of RAs.

### Limitations

The case series is limited by small sample size, hence no accurate derivations can be drawn. Larger sample size is required to draw accurate management algorithms in cases of RAs following EC.

### Conclusion

RAs possess a complicated dilemma in outlining an optimal management plan. These aneurysms have to be dealt with surgeons and large volume centers that handle complicated neurovascular surgery, including complicated cerebrovascular bypasses. The best method of treatment should be discussed in a multidisciplinary team consisting of both endovascular as well as open surgery, with the aim of providing sustainable result with minimal morbidity.

### Declaration of patient consent

The authors certify that they have obtained all appropriate patient consent forms. In the form the patient(s) has/have given his/her/their consent for his/her/their images and other clinical information to be reported in the journal. The patients understand that their names and initials will not be published and due efforts will be made to conceal their identity, but anonymity cannot be guaranteed.

### Financial support and sponsorship

Nil.

### Conflicts of interest

There are no conflicts of interest.

### References

1. Chen KS, Wilson TJ, Stetler WR, Davis MC, Giles DA, Kahn EN, *et al.* Management of recurrent aneurysms following endovascular therapy. *J Clin Neurosci* 2015;22:1901-6.
2. Molyneux AJ, Kerr RS, Birks J, Ramzi N, Yarnold J, Sneade M, *et al.* Risk of recurrent subarachnoid haemorrhage, death, or dependence and standardised mortality ratios after clipping or coiling of an intracranial aneurysm in the international subarachnoid aneurysm trial (ISAT): Long-term follow-up.

- Lancet Neurol 2009;8:427-33.
3. Molyneux AJ, Kerr RS, Yu LM, Clarke M, Sneade M, Yarnold JA, *et al.* International subarachnoid aneurysm trial (ISAT) of neurosurgical clipping versus endovascular coiling in 2143 patients with ruptured intracranial aneurysms: A randomised comparison of effects on survival, dependency, seizures, rebleeding, subgroups, and aneurysm occlusion. *Lancet* 2005;366:809-17.
  4. Johnston SC, Dowd CF, Higashida RT, Lawton MT, Duckwiler GR, Gress DR. Predictors of rehemorrhage after treatment of ruptured intracranial aneurysms: The cerebral aneurysm rerupture after treatment (CARAT) study. *Stroke* 2008;39:120-5.
  5. Ferns SP, Sprengers ME, van Rooij WJ, Rinkel GJ, van Rijn JC, Bipat S, *et al.* Coiling of intracranial aneurysms: A systematic review on initial occlusion and reopening and retreatment rates. *Stroke* 2009;40:e523-9.
  6. Spetzler RF, McDougall CG, Zabramski JM, Albuquerque FC, Hills NK, Russin JJ, *et al.* The barrow ruptured aneurysm trial: 6-year results. *J Neurosurg* 2015;123:609-17.
  7. Ogilvy CS, Chua MH, Fusco MR, Reddy AS, Thomas AJ. Stratification of recanalization for patients with endovascular treatment of intracranial aneurysms. *Neurosurgery* 2015;76:390-5.
  8. Spetzler RF, McDougall CG, Zabramski JM, Albuquerque FC, Hills NK, Nakaji P, *et al.* Ten-year analysis of saccular aneurysms in the barrow ruptured aneurysm trial. *J Neurosurg* 2019;1-6. doi: 10.3171/2016.9.
  9. Arnaout OM, El Ahmadieh TY, Zammar SG, El Tecle NE, Hamade YJ, Aoun RJ, *et al.* Microsurgical treatment of previously coiled intracranial aneurysms: Systematic review of the literature. *World Neurosurg* 2015;84:246-53.
  10. Grunwald IQ, Papanagioutou P, Struffert T, Politi M, Krick C, Gül G, *et al.* Recanalization after endovascular treatment of intracerebral aneurysms. *Neuroradiology* 2007;49:41-7.
  11. Roy D, Milot G, Raymond J. Endovascular treatment of unruptured aneurysms. *Stroke* 2001;32:1998-2004.
  12. Mascitelli JR, Moyle H, Oermann EK, Polykarpou MF, Patel AA, Doshi AH, *et al.* An update to the raymond-roy occlusion classification of intracranial aneurysms treated with coil embolization. *J Neurointerv Surg* 2015;7:496-502.
  13. Kobayashi S, Moroi J, Hikichi K, Yoshioka S, Saito H, Tanabe J, *et al.* Treatment of recurrent intracranial aneurysms after neck clipping: Novel classification scheme and management strategies. *Oper Neurosurg (Hagerstown)* 2017;13:670-8.
  14. Kang HS, Han MH, Kwon BJ, Kwon OK, Kim SH. Repeat endovascular treatment in post-embolization recurrent intracranial aneurysms. *Neurosurgery* 2006;58:60-70.
  15. Mai JC, Hoh BL. Endovascular management of recurrent aneurysms. *Neurol Res* 2014;36:323-31.
  16. Lee J, Lim JW, Cho YD. Follow-up outcomes after re-embolization for recanalized aneurysms after initial coiling: Further recurrence rates and related risk factors. *World Neurosurg* 2018;114:e508-17.
  17. Dombos D 3<sup>rd</sup>, Karras CL, Wenger N, Priddy B, Youssef P, Nimjee SM, *et al.* Pipeline embolization device for recurrence of previously treated aneurysms. *Neurosurg Focus* 2017;42:E8.
  18. Hong Y, Wang YJ, Deng Z, Wu Q, Zhang JM. Stent-assisted coiling versus coiling in treatment of intracranial aneurysms: A systematic review and meta-analysis. *PLoS One* 2014;9:e82311.
  19. Tähtinen OI, Manninen HI, Vanninen RL, Rautio R, Haapanen A, Seppänen J, *et al.* Stent-assisted embolization of recurrent or residual intracranial aneurysms. *Neuroradiology* 2013;55:1221-31.
  20. Liu JJ, Nielsen TH, Abhinav K, Lee J, Han SS, Marks MP, *et al.* Surgical treatment of recurrent previously coiled and/or stent-coiled intracerebral aneurysms: A single-center experience in a series of 75 patients. *World Neurosurg* 2019. pii: S1878-8750(19)30041-5.
  21. Tumialán LM, Zhang YJ, Cawley CM, Dion JE, Tong FC, Barrow DL. Intracranial hemorrhage associated with stent-assisted coil embolization of cerebral aneurysms: A cautionary report. *J Neurosurg* 2008;108:1122-9.
  22. Toyota S, Kumagai T, Goto T, Mori K, Taki T. Trends in the management of cerebrovascular diseases. *Acta Neurochir Suppl* 2018;129:53-9.
  23. Waldron JS, Halbach VV, Lawton MT. Microsurgical management of incompletely coiled and recurrent aneurysms. *Oper Neurosurg* 2009;64:301-17.
  24. Gurian JH, Martin NA, King WA, Duckwiler GR, Guglielmi G, Viñuela F. Neurosurgical management of cerebral aneurysms following unsuccessful or incomplete endovascular embolization. *J Neurosurg* 1995;83:843-53.
  25. Zhang YJ, Barrow DL, Cawley CM, Dion JE. Neurosurgical management of intracranial aneurysms previously treated with endovascular therapy. *Neurosurgery* 2003;52:283-95.
  26. Yu LB, Fang ZJ, Yang XJ, Zhang D. Management of residual and recurrent aneurysms after clipping or coiling: Clinical characteristics, treatments, and follow-up outcomes. *World Neurosurg* 2019;122:e838-46.
  27. Shtaya A, Dasgupta D, Millar J, Sparrow O, Bulters D, Duffill J. Outcomes of microsurgical clipping of recurrent aneurysms after endovascular coiling. *World Neurosurg* 2018;112:e540-7.
  28. Nisson PL, Meybodi AT, Roussas A, James W, Berger GK, Benet A *et al.*, Surgical Clipping of Previously Ruptured, Coiled Aneurysms: Outcome Assessment in 53 Patients. *World Neurosurg*. 2018 Dec;120:e203-e211. doi: 10.1016/j.wneu.2018.07.293.
  29. Wang HW, Sun ZH, Wu C, Xue Z, Yu XG. Surgical management of recurrent aneurysms after coiling treatment. *Br J Neurosurg* 2017;31:96-100.
  30. Kivelev J, Tanikawa R, Noda K, Hernesniemi J, Niemelä M, Takizawa K, *et al.* Surgical management of recurrent aneurysms after coiling treatment. *World Neurosurg* 2016;96:1-9.
  31. Daou B, Chalouhi N, Starke RM, Barros G, Ya'qoub L, Do J, *et al.* Clipping of previously coiled cerebral aneurysms: Efficacy, safety, and predictors in a cohort of 111 patients. *J Neurosurg* 2016;125:1337-43.
  32. Owen CM, Montemurro N, Lawton MT. Microsurgical management of residual and recurrent aneurysms after coiling and clipping: An experience with 97 patients. *Neurosurgery* 2015;62 Suppl 1:92-102.
  33. Izumo T, Matsuo T, Morofuji Y, Hiu T, Horie N, Hayashi K, *et al.* Microsurgical clipping for recurrent aneurysms after initial endovascular coil embolization. *World Neurosurg* 2015;83:211-8.