

CASE REPORT

Spontaneous expectoration of tumor tissue in primary adenocarcinoma lung

Ramakant Dixit, Mukesh Goyal, Neena Kasliwal¹, Hasha T. Somson, Shreya Agarwal²

Department of Respiratory Medicine, J. L. N. Medical College, Ajmer, ¹Department of Pathology, J. L. N. Medical College, Ajmer, ²Department of Pathology, Mahatma Gandhi Medical College & Hospital, Jaipur, Rajasthan, India

Access this article online

Website: www.avicennajmed.com

DOI: 10.4103/ajm.ajm_97_20

Quick Response Code:



ABSTRACT

Spontaneous expectoration of the tissue fragments in primary lung carcinoma is an extremely unusual event. Expectoration of tumor fragments is a significant event that should not be ignored as it serves itself as a noninvasive tool to diagnose underlying malignancy if such samples are immediately preserved and subjected to histopathological examination. More so, expectoration of a large-sized fragment may provide substantial relief from the breathlessness. Reported here is the case of a middle-aged male patient with adenocarcinoma in the right lung, and mass extended up to trachea, who spontaneously coughed out pieces of tumor tissue.

Key words: Lung carcinoma, trachea, tumor expectoration

INTRODUCTION

Expectoration of the tumor tissue is an unusual event in patients with malignancy. This may happen in patients with primary or metastatic malignancy in the lung with endobronchial component.^[1] Originally described by Mackenzie,^[2] the exact incidence of expectoration of tumor tissue is unknown and this has been described as individual reports in cases of primary endobronchial lung cancer, metastasis from colon cancer, renal cell carcinoma, carcinoids, malignant melanomas, Kaposi sarcoma, lymphomas, and malignant fibrous histiocytoma.^[3] Although mostly described at the time of tumor recurrence, the tumor tissue expectoration may be a presenting manifestation of an underlying disease process. Tumors with endobronchial components are more prone to this event and the size of expectorated tumor tissue may vary from 1 to 10 cm.^[4] The expectoration of tumor tissue may be spontaneous or following bronchoscopic manipulations.^[5] This report describes a middle-aged man with adenocarcinoma in the right lung and encroachment of mass in the trachea, who expectorated pieces of tumor tissue.

CASE REPORT

A 60-year-old man who had smoked about 40 cigarettes per day for the past 15 years presented with progressive dyspnea, right-sided chest pain, cough with expectoration, and streaking of blood for 7 months. A chest X-ray with posteroanterior (PA) view revealed an opaque right hemithorax with a tracheal shift toward the same side [Figure 1]. A contrast-enhanced computed tomography (CECT) of the chest revealed a right lung mass with tracheobronchial extension, postobstructive atelectasis, and mild pleural effusion. The lesion was large, ill-defined, lobulated, heterogeneously enhanced, in the right middle lobe and lower lobe with areas of necrosis and calcification within it. The lesion displaced right main pulmonary artery, mediastinal pleura, right heart border, had tracheobronchial invasion, and extended about 3.5 cm above carina [Figure 2].

This is an open access journal, and articles are distributed under the terms of the Creative Commons Attribution-NonCommercial-ShareAlike 4.0 License, which allows others to remix, tweak, and build upon the work non-commercially, as long as appropriate credit is given and the new creations are licensed under the identical terms.

For reprints contact: reprints@medknow.com

Cite this article as: Dixit R, Goyal M, Kasliwal N, Somson HT, Agarwal S. Spontaneous expectoration of tumor tissue in primary adenocarcinoma lung. *Avicenna J Med* 2021;11:46-8.

Address for correspondence: Dr. Ramakant Dixit, Department of Respiratory Medicine, J. L. N. Medical College, Opp. Patel Stadium, Kala Bagh, Ajmer 305001, Rajasthan, India.
E-mail: dr.ramakantdixit@gmail.com

Upon general examination, he was cachectic. Physical examination revealed grade III clubbing and was unremarkable for pallor, icterus, cyanosis, and lymphadenopathy. Examination of the respiratory system revealed fullness on the right side of the chest with a dull percussion note and reduced intensity of breath sounds.

Routine laboratory investigations were within normal limits. Ultrasounds of the abdomen and chest were performed and there was no evidence of disease other than lung mass and mild pleural effusion on the right side. Even the CECT abdomen and pelvis did not reveal any abnormality. Pleural fluid analysis showed low adenosine deaminase (ADA = 31U/L), exudative (protein = 4.4g/dL) effusion without any evidence of the malignant cells.

Percutaneous transthoracic biopsy of the lung lesion was performed under local anesthesia. The histopathological examination of the tissue revealed features of moderately

differentiated adenocarcinoma [Figure 3]. On the 8th day after admission, the patient had a paroxysmal cough and expectorated pieces of tumor tissue, the largest of which was 1.5 cm × 1.0 cm, with some bloody sputum [Figure 4]. The expectorated specimen was partially autolyzed with viable tissue portion, which revealed identical histological features as seen in the lung biopsy material.

The patient reported relief in cough and breathlessness following this event. Subsequently, the patient was started on platinum-based chemotherapy.

DISCUSSION

The expectoration of tumor tissue, also suggested to be called oncoptysis, histoptysis, or carcinoptysis, is a very unusual event, although it has been reported since 1886.^[2] Only 30 cases of such types were reported till 2012 as elaborated by Ochi

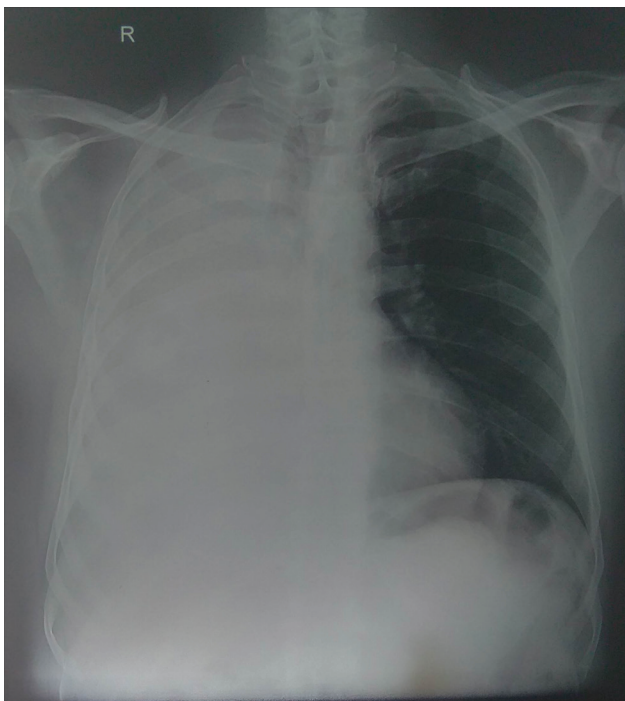

Figure 1: Chest X-ray PA view showing diffuse homogenous opacity without air bronchogram on right lung field

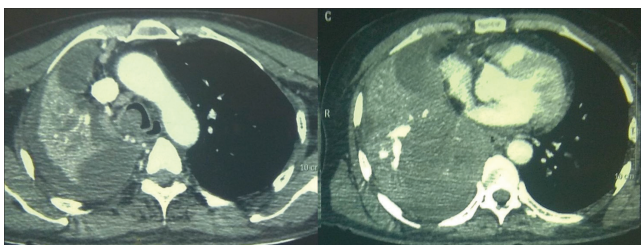


Figure 2: Chest CT scan showing right lung mass with areas of calcification and tracheal extension

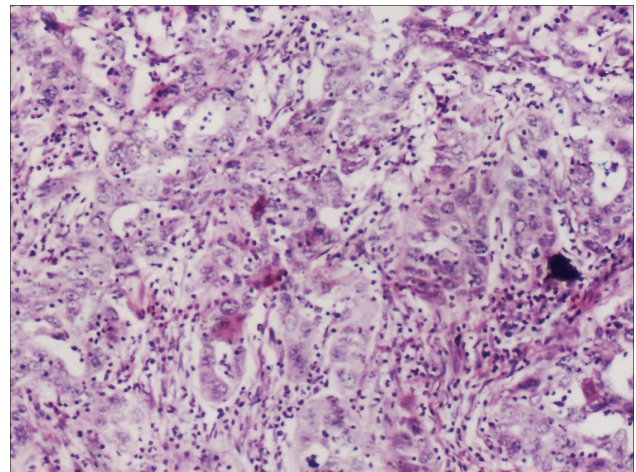


Figure 3: Photomicrograph of right lung mass biopsy showing features of adenocarcinoma lung (HE X 200)



Figure 4: Expectorated tumor tissue

et al.,^[1] who himself described another case of spontaneous expectoration of tumor tissue in primary lung carcinoma.

The tumor tissue expectoration occurs mostly spontaneously; however, this has been reported in three cases immediately after fiber optic bronchoscopy.^[5,6] The bronchoscopic biopsy, especially in the pedunculated endobronchial tumors, and those with necrotic components with more friable tissue, seems to be a possible risk factor in these cases for such events.^[7] There is also a report on expectoration of tracheobronchial pleomorphic carcinoma following ethanol injection into an intratracheal tumor to avoid tumor injury at the time of intubation.^[4] In our case, the patient expectorated tumor fragments after percutaneous transthoracic lung biopsy which appears to be unrelated as the biopsy was from the peripheral lesion, whereas the expectoration mostly occurred from the central endobronchial lesion. Moreover, we were unable to locate a correlation established about this or a similar case in the English literature till date.

The most frequent tumors reported to cause such an event are renal cell carcinoma, followed by lung carcinoma or sarcoma.^[8] This type of scenario may be the initial presentation of underlying malignancy or may occur at the time of recurrence. The case presented here was a case of adenocarcinoma in the right lower lobe of the lung with tracheal component and coughed out tumor pieces at the time of presentation. Among the various histological types in primary carcinoma of the lung, the most common one reported to cause such an event is squamous cell carcinoma.^[9] However, it has also been reported with small cell carcinoma,^[10] large cell carcinoma,^[5] and adenocarcinoma.^[1]

Among the primary lung tumors, squamous cell carcinoma and small cell carcinoma are more common central tumors, whereas adenocarcinoma is mostly a peripheral tumor. Among the primary lung tumors, the squamous cell variety has been commonly reported to cause tumor tissue expectoration.^[6,9] The case presented here is unique in view of adenocarcinoma histology and we found only one previous report on adenocarcinoma of the lung associated with tumor expectoration; however, that was a case of recurrence of the previously resected tumor.^[1]

The tumor tissue expectoration is usually preceded by a bout of cough and associated with hemoptysis; however, in the previously reported cases and in the present case, the hemoptysis was not massive and got controlled without any specific intervention. Nevertheless, it is always better to offer cough suppressants to such cases for symptom control. Although tumor tissue expectoration is shown to relieve dyspnea and forceful coughing in most cases, there may be a few complications on rare occasions. Dolgoff and Hansen^[11]

showed the development of pulmonary cavitation on chest radiograph following expectoration of fragments of metastatic Ewing's sarcoma. Daryanani *et al.*^[12] observed spontaneous unilateral hydro-pneumothorax following an episode of hemoptysis with tumor tissue expectoration in metastatic renal cell carcinoma that required a chest tube and subsequent pleurodesis. Therefore, it is wise to be vigilant for such rare events to manage complications, if any, in time. The further management of underlying tumors depends on the nature of the tumor, whether primary or metastatic, histological type, anatomical location, and performance status of the patients.

Tumor piece expectoration or tumoroptysis is a significant event for several reasons. It may be a clue to the underlying malignancy with endobronchial component and may prompt further investigation in that direction. It indirectly reflects tumor friability and advanced malignant process especially in patients with extrapulmonary primary malignancy. Both patients and physicians must be vigilant regarding this event and such symptoms should not be ignored.

Financial support and sponsorship

Nil.

Conflicts of interest

There are no conflicts of interest.

REFERENCES

- Ochi N, Yasugi M, Yamane H, Tabayashi T, Kawanaka N, Okimoto N, *et al.* Spontaneous expectoration of tumor tissue in a patient with adenocarcinoma of the lung. *Respir Care* 2012;57:1521-3.
- Mackenzie GH. A Practical Treatise on the Sputum. Edinburgh and London, UK: W & AK Johnston; 1886. p. 50-1.
- Sharma KB. Spontaneous expectoration of lung tumour mass. *CMAJ* 2005;172:1182.
- Ohata N, Nakahara R, Kasai T, Kamiyama Y, Igarashi S, Mori K, *et al.* Pulmonary pleomorphic carcinoma with tumor expectoration. *J Japan Society Respir Endoscopy* 2012;34:80-4.
- Dixit R, Joshi N, Nuwal P, Purohit SD, Gupta RC, Gupta N. Postbronchoscopy expectoration of tumour tissue in lung cancer. *Indian J Chest Dis Allied Sci* 1999;41:105-9.
- Wigton R, Rohatgi PK. Expectoration of bronchogenic carcinoma. *J Natl Med Assoc* 1978;70:799.
- Kelly WF, Crawley EA, Vick DJ, Hurwitz KM. Spontaneous partial expectoration of an endobronchial carcinoid. *Chest* 1999;115:595-8.
- Watanabe R, Kamiyoshihara M, Kaira K, Motegi A, Takise A. Spontaneous expectoration of primary pulmonary synovial sarcoma. *J Thorac Oncol* 2006;1:1025-6.
- Mital OP, Agarwala MC. Expectoration of a bronchogenic carcinoma. *Br J Dis Chest* 1968;62:52-3.
- Kaira K, Shimizu Y, Sunaga N, Hisada T, Ishizuka T, Mori M. Expectoration of bronchogenic tumour tissue. *Intern Med J* 2007;37:340-2.
- Dolgoff S, Hansen RH. Pulmonary cavitation following expectoration of neoplastic tissue. *Am J Clin Pathol* 1950;20:974-6.
- Daryanani S, Knausenberger HP, de Takats PG, Guest PJ, Kerr DJ. Spontaneous pneumothorax associated with expectoration of a lump of metastatic renal cancer. *Clin Oncol (R Coll Radiol)* 1997;9:262-3.